This is a digital copy of a book that was preserved for generations on library shelves before it was carefully scanned by Google as part of a project to make the world's books discoverable online.

It has survived long enough for the copyright to expire and the book to enter the public domain. A public domain book is one that was never subject to copyright or whose legal copyright term has expired. Whether a book is in the public domain may vary country to country. Public domain books are our gateways to the past, representing a wealth of history, culture and knowledge that's often difficult to discover.

Marks, notations and other marginalia present in the original volume will appear in this file - a reminder of this book's long journey from the publisher to a library and finally to you.

**Usage guidelines**

Google is proud to partner with libraries to digitize public domain materials and make them widely accessible. Public domain books belong to the public and we are merely their custodians. Nevertheless, this work is expensive, so in order to keep providing this resource, we have taken steps to prevent abuse by commercial parties, including placing technical restrictions on automated querying.

We also ask that you:

+ *Make non-commercial use of the files* We designed Google Book Search for use by individuals, and we request that you use these files for personal, non-commercial purposes.
+ *Refrain from automated querying* Do not send automated queries of any sort to Google's system: If you are conducting research on machine translation, optical character recognition or other areas where access to a large amount of text is helpful, please contact us. We encourage the use of public domain materials for these purposes and may be able to help.
+ *Maintain attribution* The Google "watermark" you see on each file is essential for informing people about this project and helping them find additional materials through Google Book Search. Please do not remove it.
+ *Keep it legal* Whatever your use, remember that you are responsible for ensuring that what you are doing is legal. Do not assume that just because we believe a book is in the public domain for users in the United States, that the work is also in the public domain for users in other countries. Whether a book is still in copyright varies from country to country, and we can't offer guidance on whether any specific use of any specific book is allowed. Please do not assume that a book's appearance in Google Book Search means it can be used in any manner anywhere in the world. Copyright infringement liability can be quite severe.

**About Google Book Search**

Google's mission is to organize the world's information and to make it universally accessible and useful. Google Book Search helps readers discover the world's books while helping authors and publishers reach new audiences. You can search through the full text of this book on the web at `http://books.google.com/`

COUNTWAY LIBRARY
HC 4K5W 4

Digitized by Google

Digitized by Google

Digitized by Google

Digitized by Google

Digitized by Google

Digitized by Google

TRANSACTIONS OF THE

SECTION ON

# DERMATOLOGY

of the
American Medical Association
at the Sixty-Fourth Annual
Session, held at Minneapolis,
Minn., June 17 to 20, 1913

*AMERICAN MEDICAL ASSOCIATION PRESS*
*CHICAGO: NINETEEN HUNDRED AND THIRTEEN*

Digitized by Google

DEC 10 1924
LIBRARY

CATALOGUED
DEC 10 1924
D. B. S.

Reprinted from
THE JOURNAL
of the
AMERICAN MEDICAL ASSOCIATION

Copyright 1913
by the
American Medical Association

Digitized by Google

## OFFICERS FOR 1912-1913

CHAIRMAN

JOSEPH ZEISLER - - - - - - - - - - - CHICAGO

VICE-CHAIRMAN

H. R. VARNEY - - - - - - - - - - - - DETROIT

SECRETARY

HOWARD FOX - - - - - - - - - - - - NEW YORK

EXECUTIVE COMMITTEE

WILLIAM ALLEN PUSEY, CHICAGO
GROVER W. WENDE, BUFFALO
CHARLES J. WHITE, BOSTON

## OFFICERS FOR 1913-1914

CHAIRMAN

RICHARD L. SUTTON - - - - - - - KANSAS CITY, MO.

VICE-CHAIRMAN

J. B. KESSLER - - - - - - - - - - IOWA CITY, IA.

SECRETARY

HOWARD FOX - - - - - - - - - - - - NEW YORK

EXECUTIVE COMMITTEE

GROVER W. WENDE, BUFFALO
CHARLES J. WHITE, BOSTON
JOSEPH ZEISLER, CHICAGO

Digitized by Google

Digitized by Google

# LIST OF OFFICERS

This Section was organized in 1887 and has been served by the following officers, the year being the date of election. The list is compiled from the published records, which are incomplete in some cases. It will be appreciated if any errors are brought to the attention of the Secretary of the American Medical Association.

SECTION ON DERMATOLOGY AND SYPHILOLOGRAPHY

1887 Chairman, L. D. Bulkley, New York City.
Secretary, F. F. Dunlop, Kentucky.
1888 Chairman, L. D. Bulkley, New York City.
Secretary, W. T. Corlett, Cleveland, Ohio.
1889 Chairman, J. E. Atkinson, Baltimore.
Secretary, W. T. Corlett, Cleveland, Ohio.
1890 Chairman, L. D. Bulkley, New York City.
Secretary, W. T. Corlett, Cleveland, Ohio.
1891 Chairman, L. D. Bulkley, New York City.
Secretary, J. C. McGuire, Washington, D. C.
1892 Chairman, L. A. Duhring, Philadelphia.
Secretary, W. H. Dunlop, New York City.
1893 Chairman, A. H. Ohmann-Dumesnil, St. Louis.
Secretary, L. F. Frank. Milwaukee, Wis.
1894 Chairman, A. E. Regensburger, San Francisco.
Secretary, D. H. Rand, Portland, Ore.
1895 Chairman, L. D. Bulkley, New York City.
Secretary, T. C. Gilchrist, Baltimore.
1896 Chairman, A. Ravogli, Cincinnati.
Secretary, T. C. Gilchrist, Baltimore.
1897 Chairman, A. W. Brayton, Indianapolis.
Secretary, T. C. Gilchrist, Baltimore.

SECTION ON CUTANEOUS MEDICINE AND SURGERY

1898 Chairman, W. T. Corlett, Cleveland, Ohio.
Secretary, J. M. Blaine, Denver.
1899 Chairman, L. D. Bulkley, New York City.
Secretary, R. R. Campbell, Chicago.
1900 Chairman, W. L. Baum, Chicago.
Secretary, R. R. Campbell, Chicago.
1901 Chairman, H. W. Stelwagon, Philadelphia.
Secretary, R. R. Campbell, Chicago.
1902 Chairman, John A. Fordyce, New York City.
Secretary, R. R. Campbell, Chicago.
Delegates, M. B. Hartzell, Philadelphia, and William L. Baum, Chicago.
1903 Chairman, Henry G. Anthony, Chicago.
Secretary, R. R. Campbell, Chicago.
Delegate, Jay F. Schamberg, Philadelphia.

Digitized by Google

## LIST OF OFFICERS—Continued

1904 Chairman, Douglas W. Montgomery, San Francisco.
Secretary, R. R. Campbell, Chicago.
Delegate, A. W. Brayton, Indianapolis.

1905 (The Section did not meet and the old officers acted two years.)

1906 Chairman, R. R. Campbell, Chicago.
Secretary, M. L. Heidingsfeld, Cincinnati.
Delegate, Henry R. Varney, Detroit.

1907 Chairman, M. B. Hartzell, Philadelphia.
Secretary, M. L. Heidingsfeld, Cincinnati.
Delegate, R. R. Campbell, Chicago.

1908 Chairman, William Allen Pusey, Chicago.
Secretary, M. L. Heidingsfeld, Cincinnati.
Delegate, R. R. Campbell, Chicago.

### SECTION ON DERMATOLOGY

1909 Chairman, Grover W. Wende, Buffalo, N. Y.
Secretary, H. R. Varney, Detroit.
Delegate, William Allen Pusey, Chicago.

1910 Chairman, Charles J. White, Boston.
Vice-Chairman, Martin F. Engman, St. Louis.
Secretary, H. R. Varney, Detroit.

1911 Chairman, Charles J. White, Boston.
Vice-Chairman, Martin F. Engman, St. Louis.
Secretary, H. R. Varney, Detroit.

1912 Chairman, Joseph Zeisler, Chicago.
Vice-Chairman, H. R. Varney, Detroit.
Secretary, Howard Fox, New York.
Delegate, Frank C. Knowles, Philadelphia.

1913 Chairman, Richard L. Sutton, Kansas City, Mo.
Vice-Chairman, J. B. Kessler, Iowa City, Iowa.
Secretary, Howard Fox, New York.
Delegate, William A. Pusey, Chicago.

Digitized by Google

# CONTENTS

PAGE

List of Officers ..... 7

Proceedings of the Section ..... 11

Chairman's Address: Our Tendency to Fads. Joseph Zeisler ..... 17

Pemphigus Foliaceus. J. B. Kessler ..... 23

Radium in Skin Diseases. Frank E. Simpson ..... 30

Salvarsan Versus Profeta's Law. Augustus Ravogli ..... 40

A Comparative Study of Antigens for the Wassermann Reaction. H. R. Varney and F. W. Baeslack ..... 48

The Histopathology of Pompholyx. Richard L. Sutton ..... 59

Cutaneous Affections of Childhood. Alfred Schalek ..... 71

Skin Complications of Diabetes. Burnside Foster ..... 80

Primary Sarcoma of the Lower Lip. A. J. Markley ..... 87

An Anomalous Case of White-Spot Disease. H. H. Hazen 90

Neuroma Cutis (Dolorosum). M. L. Heidingsfeld ..... 98

Skin Diseases Among Full-Blood Indians of Oklahoma. Everett S. Lain ..... 105

The Newer Cutaneous Mycoses. Ernest Dwight Chipman 116

Idiopathic Atrophy of the Skin with Report of a Case. H. G. Irvine ..... 132

Mycosis Fungoides Following Psoriasis. Howard Fox ..... 145

A Study of the Spinal Fluid in One Hundred Cases of Syphilis, Including Investigations for Arsenic After Intravenous Administration of Neosalvarsan. M. F. Engman, Rudolph Buhman, F. D. Gorham and R. H. Davis ..... 155

Angioma Serpiginosum (Infective Angioma of Hutchinson), with a Report of a Very Extensive Case. Fred Wise ..... 177

List of Fellows Registering in This Section ..... 205

Index ..... 207

Digitized by Google

Digitized by Google

BOSTON MEDICAL
DEC 10 1924
LIBRARY

# PROCEEDINGS OF THE SECTION

TUESDAY, JUNE 17—AFTERNOON

The Chairman, Dr. Joseph Zeisler, Chicago, called the meeting to order at 2:15 p. m. in Folwell Hall. He said that he was pleased to see such a good attendance, and expressed the hope that the profit and pleasure of the meeting would be enhanced by a free discussion of the papers.

Dr. John Butler, Minneapolis, invited the members to a banquet at the Country Club at 7:30 p. m., and said that automobiles for their transportation to the club had been provided.

Dr. Zeisler then read the Chairman's address, entitled "Our Tendency to Fads."

The chairman stated that before proceeding further with the scientific program, he would appoint a Nominating Committee.

Dr. M. L. Heidingsfeld, Cincinnati, moved that the nominations be made from the floor on the day set apart for the election of officers.

Dr. William A. Pusey, Chicago, offered as a substitute motion that the Chairman appoint the Nominating Committee.

Dr. H. R. Varney, Detroit, in seconding this motion, said that for many years it had been the usual custom for the Chairman to appoint this committee. The motion was thereupon carried.

The Chairman announced the following to act as a Nominating Committee: Drs. F. O. Foerster, Milwaukee, Chairman; M. L. Ravitch, Louisville, and H. G. Irvine, Minneapolis. The committee was asked to make its recommendations on Thursday morning.

Dr. J. B. Kessler, Iowa City, read a paper on "Two Cases of Pemphigus Foliaceus." Discussed by Drs. Alfred Schalek, Omaha; Richard L. Sutton, Kansas City, Mo.; W. A. Pusey, Chicago; Howard Fox, New York; H. H. Hazen, Washington, D. C.; M. Ravogli, Cincinnati; Isadore Dyer, New Orleans, and J. B. Kessler, Iowa City.

Dr. H. H. Hazen, Washington, D. C., read a paper on "An Anomalous Case of White-Spot Disease." Discussed by Drs. A. Ravogli, Cincinnati, and H. H. Hazen, Washington, D. C.

Digitized by Google

Dr. Frank E. Simpson, Chicago, read a paper on "Radium in Skin Diseases." Discussed by Drs. M. L. Heidingsfeld, Cincinnati; M. L. Ravitch, Louisville; Joseph Zeisler, Chicago; Fred Wise, New York; Alfred Schalek, Omaha; H. R. Varney, Detroit, and Frank E. Simpson, Chicago.

Dr. George M. MacKee, New York, read a paper on "The Massive Dose Roentgen-Ray Method in the Treatment of Skin Diseases." Discussed by Drs. Everett S. Lain, Oklahoma, Okla., and George M. MacKee, New York.

Dr. M. L. Heidingsfeld, Cincinnati, read a paper on "Neuromas of the Skin" (with lantern-slide demonstration). Discussed by Dr. Howard Fox, New York.

Dr. Fred Wise, New York, read a paper on "Angioma Serpiginosum (Infective Angioma of Hutchinson) with Report of a Very Extensive Case." Discussed by Drs. Joseph Zeisler, Chicago; George M. MacKee, New York; Howard Fox, New York, and Fred Wise, New York.

### Wednesday, June 18—Morning

Drs. S. E. Sweitzer, Minneapolis; H. G. Irvine, Minneapolis; Charles D. Freeman, St. Paul; C. A. Boreen, Minneapolis, and George P. Crume, Minneapolis, presented a number of clinical cases which were discussed by Drs. Richard L. Sutton, Kansas City, Mo.; Ernest D. Chipman, San Francisco; M. L. Ravitch, Louisville, Ky.; H. G. Irvine, Minneapolis; Charles D. Freeman, St. Paul; S. E. Sweitzer, Minneapolis; Alfred Schalek, Omaha; M. L. Heidingsfeld, Cincinnati; Joseph Zeisler, Chicago; David Lieberthal, Chicago; J. C. Elliott King, Portland, Ore.; Isadore Dyer, New Orleans, and Howard Fox, New York.

Dr. A. Ravogli, Cincinnati, read a paper on "Salvarsan and Profeta's Law." Discussed by Drs. Alfred Schalek, Omaha; M. L. Heidingsfeld, Cincinnati, and A. Ravogli, Cincinnati.

Drs. M. F. Engman, Rudolph Buhman, Robert H. Davis and F. D. Gorham, St. Louis, presented a joint paper on "A Study of the Spinal Fluid in One Hundred Cases of Syphilis." This was read by Dr. Rudolph Buhman and was discussed by Drs. F. G. Harris, Chicago; David Lieberthal, Chicago; H. G. Irvine, Minneapolis; M. L. Heidingsfeld, Cincinnati; H. H. Hazen, Washington, D. C., and Rudolph Buhman, St. Louis.

Drs. H. R. Varney and F. W. Baeslack, Detroit, read a paper on "Comparative Study of Antigens for the Wassermann Reaction." This was discussed by Drs. Howard Fox, New York; J. Frank Waugh, Chicago; M. L. Heidingsfeld, Cincin-

Digitized by Google

nati; Rudolph Buhman, St. Louis; H. R. Varney, Detroit, and F. W. Baeslack, Detroit.

Dr. Richard L. Sutton, Kansas City, Mo., read a paper on "The Histopathology of Pompholyx." Discusssed by Drs. Joseph Zeisler, Chicago; Isadore Dyer, New Orleans; W. A. Pusey, Chicago; Frank E. Simpson, Chicago; M. L. Ravitch, Louisville, Ky.; K. A. Zurawski, Chicago; Everett S. Lain, Oklahoma, Okla., and Richard L. Sutton, Kansas City, Mo.

Dr. Alfred Schalek, Omaha, read a paper on "Cutaneous Affections of Childhood." Discussed by Drs. W. A. Pusey, Chicago; David Lieberthal, Chicago; Burnside Foster, St. Paul; Everett S. Lain, Oklahoma, Okla.; M. L. Ravitch, Louisville, Ky.; K. A. Zurawski, Chicago, and Alfred Schalek, Omaha.

### Wednesday, June 18—Afternoon

Dr. M. L. Ravitch, Louisville, read a paper on "Empiricism in Dermatologic Therapeutics." Discussed by Dr. A. Ravogli, Cincinnati.

Dr. Everett S. Lain, Oklahoma, Okla., read a paper on "A Study of Skin Diseases Among the Indians of Oklahoma." Discussed by Drs. Howard Fox, New York; M. L. Ravitch, Louisville; Ernest D. Chipman, San Francisco; A. J. Markley, Denver; Isadore Dyer, New Orleans; M. L. Heidingsfeld, Cincinnati, and Everett S. Lain, Oklahoma, Okla.

Dr. Ernest Dwight Chipman, San Francisco, read a paper on "The Newer Cutaneous Mycoses." Discussed by Drs. Richard L. Sutton, Kansas City, Mo.; A. Ravogli, Cincinnati; Arthur H. Schwartz, Duluth, Minn.; Joseph Zeisler, Chicago; H. E. Menage, New Orleans; Ernest D. Chipman, San Francisco, and David Lieberthal, Chicago.

Dr. A. J. Markley, Denver, read a paper on "Primary Sarcoma of the Lower Lip." Discussed by Drs. M. L. Heidingsfeld, Cincinnati, and A. J. Markley, Denver.

### Thursday, June 19—Morning

The following officers were elected for the ensuing year: Chairman, Dr. Richard L. Sutton, Kansas City, Mo.; Vice-Chairman, Dr. J. B. Kessler, Iowa City, Iowa; Secretary, Dr. Howard Fox, New York; Delegate, Dr. William A. Pusey, Chicago; Alternate, Dr. Isadore Dyer, New Orleans.

Drs. Charles D. Freeman, St. Paul; Burnside Foster, St. Paul; S. E. Sweitzer, Minneapolis, and John Butler, Minneapolis, presented a number of patients. These cases were discussed by Drs. M. L. Heidingsfeld, Cincinnati; A. Ravogli,

Digitized by Google

Cincinnati; Howard Fox, New York; Joseph Zeisler, Chicago; W. A. Pusey, Chicago; Charles D. Freeman, St. Paul; M. L. Ravitch, Louisville, Ky.; H. G. Irvine, Minneapolis; Burnside Foster, St. Paul; Isadore Dyer, New Orleans; H. E. Menage, New Orleans, and David Lieberthal, Chicago.

The Chairman spoke of the interest evoked by this clinical demonstration, and a vote of thanks was extended to the members of Minneapolis and St. Paul for their kindness in having these patients in readiness and bringing them to the meeting for inspection and discussion.

Dr. Isadore Dyer, New Orleans, offered a resolution that any member of the Section on Dermatology who applies for space on the program of that Section and allows his name and the title of his paper to be published thereon, and then fails to be present at the meeting or to send a satisfactory excuse for his absence, shall be debarred from the program for two successive years thereafter; and any member who absents himself for two successive years after allowing the name and title of his paper to be published, with or without an excuse, shall be debarred for five years.

This resolution was carried, and the Secretary was requested to transmit a copy to the House of Delegates through the proper representative of the Section. (This failed to reach the House of Delegates.)

Dr. Burnside Foster, St. Paul, read a paper on "Relation of Diabetes to Various Dermatoses." Discussed by Drs. John M. Armstrong, St. Paul; Ernest D. Chipman, San Francisco; M. L. Heidingsfeld, Cincinnati; K. A. Zurawski, Chicago; H. E. Menage, New Orleans; Everett S. Lain, Oklahoma, Okla., and Burnside Foster, St. Paul.

Dr. H. G. Irvine, Minneapolis, read a paper on "Idiopathic Atrophy of the Skin, with Report of a Case" and presentation of the patient. Discussed by Drs. Richard L. Sutton, Kansas City, Mo.; M. L. Heidingsfeld, Cincinnati; W. A. Pusey, Chicago, and H. G. Irvine, Minneapolis.

Dr. Howard Fox, New York, read a paper on "Mycosis Fungoides Following Psoriasis." Discussed by Drs. Joseph Zeisler, Chicago; C. A. Boreen, Minneapolis; O. H. Foerster, Milwaukee; Frank E. Simpson, Chicago, and H. H. Hazen, Washington, D. C.

The Secretary read a communication from Dr. Alexander R. Craig, the Secretary of the Association, stating that at the meeting of the House of Delegates yesterday afternoon the House adopted the recommendation of the Reference

Digitized by Google

Committe on Reports of Officers regarding the advisability of having the various Sections elect their secretaries for a term of more than one year.

Dr. Joseph Zeisler, the retiring Chairman, said that without unfairness he believed this concluded the most successful session that the Section on Dermatology had ever enjoyed in the history of the American Medical Association. The sessions were far better attended, and they had succeeded in introducing a very important feature, namely, the presentation of clinical cases. Furthermore, the discussion of the papers had been interesting and strictly to the point, without verbosity or divergence. The Section was now doing real scientific dermatologic work. It had outgrown its baby shoes and was now able to take rank with other scientific bodies. In closing his remarks, Dr. Zeisler congratulated the Section on having chosen as his successor a man who was so well worthy of the dignity of the position.

Dr. Richard L. Sutton, Kansas City, Mo., the newly elected Chairman, thanked the members for the honor they had conferred on him, and expressed the hope that the future work of the Section would prove the wisdom of their choice.

A vote of thanks was extended to the retiring Chairman of the Section, and also to the Secretary for their efficient services in connection with this meeting. A vote of thanks was also extended to the local members of the Section in Minneapolis and St. Paul for their efforts to make the meeting a success.

Adjourned.

Digitized by Google

Digitized by Google

# OUR TENDENCY TO FADS

JOSEPH ZEISLER, M.D.
Professor of Dermatology, Northwestern University Medical School
CHICAGO

This is neither the place nor the time to enlarge on the fact that the American people have a distinct tendency toward indulgence in fads of all kinds. That the medical profession in its own field of activities has shown the same inclination can easily be proved by a retrospect into recent medical history. I do not mean to suggest that Americans in general, and American physicians in particular, are possessed of that peculiar tendency to a very much larger degree than people abroad; but with us the tendency I refer to manifests itself in a somewhat different manner. Our fads show a very short life and a continuous change. Also, we are strongly inclined to cultivate certain fads just about when they begin to be discarded by Europeans. A fad is not necessarily a thing without any value as is evident from a definition taken from the dictionary: "A trivial fancy adopted and pursued for a time with irrational zeal; a matter of no importance, or an important matter imperfectly understood taken up and urged with more zeal than sense; a whim; a crotchet; a temporary hobby."

To mention just a few of the more noteworthy fads relating to medicine in general in recent times, I might cite the treatment of senile prostatic hypertrophy by orchidectomy which was practiced about eighteen years ago with a great deal more zeal than reason, and was quickly abandoned when it was found that almost disastrous constitutional effects followed the operation. Not

Digitized by Google

long after that the so-called Bottini-Freudenberg operation for the same purpose, consisting in the galvanic cauterization of the enlarged organ through the bladder, made a great deal more noise than it deserved, and after a short and harmful career has been utterly abandoned. There was a time when ovaries were sacrificed to an extent amounting to a fad. The same criticism might perhaps without much injustice be made to-day as to appendectomy. A few in this audience may perhaps recollect that short-lived fad of nerve stretching in cases of tabes or may still have in mind the time when galvanocautery of the turbinated bodies in the nose was practiced for the relief of hay-fever, chronic rhinitis and almost any pathologic state in the nostrils with a great deal of vigor and very little rationality. The injections of paraffin for the relief of cosmetic defects may also be classed among the short-lived fads. The irreparable harm which this practice has often done has led to its utter abandonment except in rare instances. I may not be competent to speak about matters outside of our own special domain, but my impression is that the extent to which Freud's psychanalysis has been exploited in neurologic literature of late borders on faddism.

Coming to matters of more personal interest to us, I might remind you of the almost unprecedented enthusiasm with which Roentgen rays were used and abused soon after their therapeutic value was first brought to our notice, twelve or thirteen years ago. It was a veritable fad to employ them in all kinds of conditions, often without even a correct diagnosis being made. It took a great many and costly lessons to narrow down the field of their usefulness, and to modify the technic of their application to a plane of safety. No one can appreciate the remarkable therapeutic efficiency of Roentgen-ray treatment in many dermal conditions more than I do, but my brief criticism in this connection is directed against its misuse in inexperienced and untrustworthy hands.

Digitized by Google

The treatment of syphilis in recent times also has furnished some occasion for the pursuit of faddism. I have often had to smile at the peculiar activity and zeal with which about ten years ago mercurial inunctions were taken up in this country as if that method were something entirely new. This form of treatment, hundreds of years old, had formerly been practiced in this country only in certain resorts. The profession in general and even so-called specialists in the treatment of syphilis seemed to consider the method so cumbersome, unpractical and unclean that they seldom made use of it, being seemingly contented with the continuous administration in season and out of season of the infallible pills of protiodid of mercury. When European physicians had almost discarded inunctions in favor of injections of mercury we could here see it being taken up as a fad as if it were the latest word in the treatment of syphilis. Do not misunderstand me. I am ready to subscribe to the unquestioned value of this method, which has stood the test of time; I merely point out the peculiar faddism which gave it a short-lived popularity here.

In a similar way we could observe several years ago the short-lived practice of intravenous injections of bichlorid of mercury of which to-day we hear so little. Coming to present-day history I should certainly not be willing to criticize the enthusiastic reception which Ehrlich's great discovery received everywhere. But in this connection I feel like severely criticizing a certain phase of the most modern treatment of lues, I mean the exposure by surgery of the vein into which the salvarsan solution is to be injected. I consider this a perfectly useless and inexcusable procedure amounting to a fad. If we consider that many cases of syphilis require repeated injections of salvarsan or neosalvarsan, if we furthermore remember the frequent necessity of entering the veins in the same anatomic neighborhood for the purpose of serodiagnostic tests, we can easily appreciate

Digitized by Google

the great injury to which those poor veins are subjected. Nor should we forget that a patient who has been subjected to that style of injection is forever stigmatized.

In former times I could make the almost daily observation that physicians in general and even specialists were very slow in adopting any form of treatment which required the regular use of a hypodermic syringe. That applied, of course, particularly to the treatment of syphilis. All this has changed wonderfully of late when almost anything is being treated by the injection of all sorts of serums and the so-called vaccines or bacterins. I feel perfectly incompetent to discuss that subject in general from its many points of view. I realize its great possibilities and its scientific fundaments, but when we see that vaccines are recommended and used for the treatment of vertigo, hay-fever, rheumatism and sciatica, of appendicitis and gall-stones, we are forced to regard such practices as fads. Regarding purely cutaneous affections, their use in sycosis and furunculosis is to-day pretty well established, although we are far from possessing sufficiently exact data as to dosage and frequency of injections. I can only look with mild incredulity on the reports of the cure of pruritus ani by autogenous vaccines. I should require better proof for the microbic origin of that condition before I can accept those statements.

Of most interest to dermatologists is without any doubt the use of vaccines in the treatment of acne on account of the frequency of this disease in our practice. It is now several years since autogenous vaccines were first introduced in the treatment of this condition under the influence of Wright's epoch-making researches concerning the so-called opsonins. Since then we have gone through a series of developments. Enterprising pharmaceutical houses have done their share in complicating the matter, not to say making our lives miserable. Barely have we had a chance to make observations on the value or lack of value of their stock vaccine sup-

Digitized by Google

posed to contain the dead acne bacillus when they suggest the necessity of using a polyvalent or mixed vaccine containing as many as five different organisms, a veritable shotgun mixture, not to say "ragout," which in itself constitutes an implied admission of weakness of this form of treatment. Leaving entirely out of the discussion the question whether or not the acne bacillus is really the cause, or at least the chief cause, of acne, a matter which is by no means universally acknowledged or proved at all, the fact remains that extensive observations will force on us the conviction that these injections have very little, or at best only temporary, effect in most cases of acne. This applies at any rate to the stock vaccines in the market. Whether or not the use of autogenous vaccines, which means dependence on a reliable bacteriologic laboratory, will ever become popular remains to be seen.

If I mention in this connection the so-called Phylacogens which have been urged on our attention during the last year by an overzealous drug house I do so merely to warn others against their use. I know only by hearsay that in rheumatism and other general infections they have occasionally been used with disastrous results, but I do know from my own experience in a few instances that the use of the special acne Phylacogen, which so far has been only experimentally tried, was followed in each case by such disagreeable, not to say alarming coeffects, that I would under no circumstances be willing ever to use them again. It is a source of comfort to know that THE JOURNAL of the American Medical Association has proved itself in this instance, as in many others before, a veritable areopagus, or in plain English, a faithful watchdog. Its severe criticisms of Phylacogens are praiseworthy. Its recent articles on vaccine treatment are a splendid guide to the novice.

Not only in regard to therapeutics do we find a tendency to fads. We can observe a similar tendency in

Digitized by Google

regard to broad pathologic and diagnostic questions. There was a period in dermatology when an attempt was made to explain most skin diseases of unknown etiology on the basis of trophoneurotic influences. That was at the time before bacteriology had become established in its varied etiologic relations. More recently the subject of anaphylaxis has been forced into the foreground and is being discussed to an extent and used to explain the cause of disease in a manner which classes it among the fads.

One of the greatest accomplishments of modern serologic studies is the so-called Wassermann test. Its value is absolutely established as one of the most important diagnostic features in syphilis; but when we see that in any case of a non-specific skin disease the diagnosis of which offers no difficulty whatever, in eczema, psoriasis, lichen planus, in keratosis palmaris, lupus erythematosus, or what not, a Wassermann test is undertaken as a sort of diagnostic pons asinorum, we are forced to think that that excellent method is being abused or made a fad of.

We are living in a period to-day when the pathologic laboratory has become indispensable to us in our daily work, but we should not use it for the pursuit of fads; we should not forget that after all the laboratory should be our aid, our assistant, not to say our servant, and not our master. Clinical knowledge is in danger of becoming neglected in favor of laboratory methods. The two must work together if we are to perform our work successfully.

32 North State Street.

Digitized by Google

# PEMPHIGUS FOLIACEUS

J. B. KESSLER, M.D.
IOWA CITY, IOWA

Pemphigus foliaceus was first described by Cazenave in 1844. It is a rare skin disease occurring about once in five thousand cases. Radcliff Crocker, with his almost unlimited experience up to the year 1903, encountered it only six times—in five women and one man. It is one of the rare forms of dermatitis that has a universal distribution, with the formation of flaccid bullae which quickly rupture and discharge their contents, leaving an inflamed, excoriated and fissured surface.

The disease may begin as a pemphigus foliaceus or from a chronic pemphigus vulgaris, the bullae changing their character. It may develop from a dermatitis herpetiformis, according to Hallopeau, or from a general dermatitis exfoliativa.

The bullae are flaccid and at times do not raise the epidermis perceptibly; if the amount of fluid is greater, it extends the lower part of the bullae. The contents are purulent, almost from the beginning. The mucous membranes may be involved. There is a feeling of stiffness and tension in the skin where the epidermis has dried. There is not much itching or burning as a rule, but at times it is severe and paroxysmal, owing to the exposure of the corium to the air.

After the disease has lasted for a time, there may be fever, either intermittent or continuous, or the temperature may remain normal.

The etiology of this disease is still in doubt; chills may be a causative factor, or violent emotions, according to Hallopeau.

Digitized by Google

In making a diagnosis we must differentiate from universal eczema, pityriasis rubra, lichen acuminatus universalis, eczema rubrum and pemphigus vegetans.

The disease may be years in duration, but, sooner or later, the patient succumbs.

Two cases which have come under my observation since March 5, 1912, may be of interest to the general practitioner, if not to the dermatologist.

CASE 1.—Mrs. M., aged 56, a native of Denmark, who had come to America the previous October to visit a married daughter living in northern Iowa, was admitted to the University Hospital, March 5, 1912. Her father died at the age of 61; mother died aged 36 or 38; one brother and one sister are living and well; three brothers are dead, cause unknown. Nothing is known of grandparents; there is no history of malignant or Bright's disease or nervous trouble, and no history of skin diseases in the family. Husband and two children are living and well; one child died at 4 months, and one at 2 years of age. There have been no miscarriages, no diseases of childhood or specific diseases. The patient had influenza in 1909.

About June 20, 1911, the patient noticed a red spot on the right cheek; this soon developed into a blister which spread slowly until January, 1912, when the whole face and upper trunk were involved; the disease kept creeping downward until March, when the entire body was covered with blisters, ruptured and unruptured. The blisters came out in crops, appearing on the face and then on the body; the lesions seemed to spring from the healthy skin. The patient says that unless she sees a lesion or it is ruptured, she is not aware of its presence. When the bulla ruptures a new red epithelium is seen, which the patient says stings as if needles were pricking.

There seems to be a separation of the epidermis from the derma to a marked extent in this disease. The patient had two falls while in the hospital; contrary to instructions that she should not get out of bed when the nurse was out of the room, she would persist in doing so; she fell on a tray once and the epidermis was separated and rolled up for about three inches square on one palm. After the second fall a like condition was found on one ankle.

Since admission to the hospital, patient's temperature had ranged from 98 to 104 +. The last month in the hospital it was normal.

While the temperature ranged from 102 to 104 + about two or three weeks, the condition of the patient was serious; the contents of the bullae, especially those about the

Digitized by Google

Fig 1.—Case 1.

Digitized by Google

Digitized by Google

**Fig. 2.—Case 2; front view of patient.**

Digitized by Google

Digitized by Google

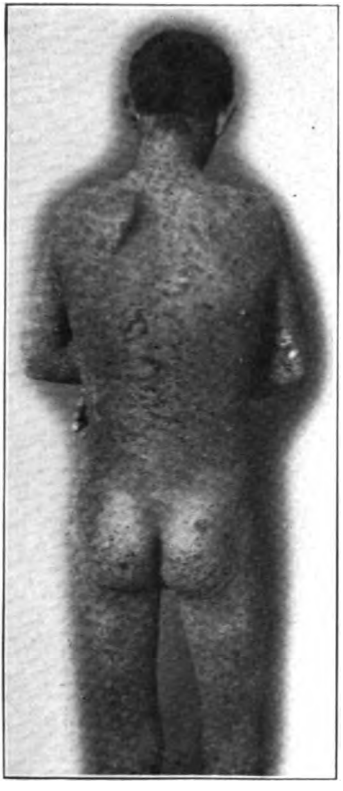

Fig. 3.—Case 2; back view of patient.

Fig. 5.—Case 2; patient after recovery.

Digitized by Google

Digitized by Google

Fig. 4.—Case 2; the desquamated soles.

Digitized by Google

Digitized by Google

face, instead of being an opaque, purulent exudate, became greenish and very foul.

The general condition of the patient remained good, except when the temperature was high.

The lesions did not appear on the palms, soles, conjunctiva or mucous membranes. After the bullae ceased to form, there was abundant exfoliation of the epidermis (Fig. 1). There was no involvement of the lymph-nodes. Blood-pressure was 120, hemoglobin 65 per cent., reds 403,000, whites 15,200, polymorphonuclears 70 per cent., transitionals 2 per cent, eosinophils 9 per cent.

The urine was normal both chemically and microscopically.

*Treatment.*—Patient was treated with large doses of quinin and baths. She took 10 grains of quinin every four hours for several weeks at a time with the best effect with scarcely any tinnitus aurium; the bullae ceased forming and the temperature remained normal or nearly so.

The medicine at times was suspended and bullae would again form. When the patient left the hospital, Sept. 11, 1912, there had been no bullae on the skin for about two months; she apparently had recovered. In conjunction with the internal medication, the patient was given bran baths daily, which seemed beneficial in preventing cracking of the skin around the joints.

I have tried to keep informed in reference to this patient, and received a letter from Germany bearing date of April 17, 1913, stating that she had had a relapse, and was unable to get out of bed without assistance; but when assisted, fluid would ooze from the legs. I am sorry that she could not remain under observation longer, and the medicine continued, to see what the final result would be. From the description by letter, I shall say that probably an eczematous condition supervened.

CASE 2.—The patient, Earl B., referred by Dr. Emmett Ady of West Liberty, Iowa, was a white youth aged 16. Father is supposed to be alive, and mother died aged 37, from unknown cause. One brother and four sisters are alive and well; the history is negative in reference to grandparents and malignant and tuberculous diseases. Patient denies venereal diseases and gives the usual history of the diseases of childhood. The present disease began the latter part of December, 1912, when the patient noticed a small red eruption on his right arm, which itched severely.

The first lesion was about the size of a split pea and grew larger and finally became the size of a dime. More of these appeared on the arms, then on the chest, scalp, neck, face, trunk and finally the legs, so that the entire body, except the eyes and mucous membranes, was affected (Figs. 2 and 3).

The lesions became blisters, filled with a yellowish fluid which would rupture and wet the patient's clothing. Finally

Digitized by Google

the bullae became confluent, and the body appeared to be one solid mass of eruption. About the time the patient entered the hospital the bullae began to dry up. When he came to the city he called at my office while I was out. When I entered, the first thing that greeted me was an offensive odor, not sweetish, but very repugnant. The patient was accompanied by his brother and another relative; the latter had worn a dog-skin coat and had taken it off and placed it on a chair. My first thought was that it was the most offensive dog-skin coat that I had ever come in contact with.

The boy was bent over. When asked why he bent forward so much he stated that his clothing stuck to him so that he could not stand erect. On removing his clothing, he was seen to be a mass of scales and bullae, from the crown of his head to his ankles; his feet and buttocks were not involved, but were invaded later; scales and crusts were large in places, especially on the right wrist, where they were about 3 by 4 inches. Desquamation of the finger-nails and toe-nails eventually occurred, then the soles of the feet in mass (Fig. 4), which could probably be accounted for by the patient being a farmer boy who ran barefooted all summer and into early winter.

The patient's temperature ranged when he entered the hospital, Feb. 4, 1913, from 102 to 103 +. Urine, blood, heart, lungs and kidneys were normal.

*Treatment.*—This patient was treated the same as the first patient, internally, and was given linseed meal baths with ½ ounce compound solution of cresol to the bath, and cold cream applied to the joints to keep the skin from cracking. This kept the skin moderately soft and comparatively free from odor.

This patient left the hospital twelve weeks after entrance apparently well (Fig. 5), five months after the commencement of the disease. I shall have this lad continue to take small doses of his medicine for an indefinite time.

## SUMMARY

1. The internal and local treatment in these cases seemed to be highly efficacious.

2. Two patients within one year with pemphigus foliaceus in an agricultural district is unusual.

3. Quinin in large doses seems to be highly beneficial in keeping the disease in abeyance.

4. Linseed meal and baths containing compound solution of cresol remove the odor and keep the skin pliable and the patient comfortable.

106½ East Washington Street.

Digitized by Google

## ABSTRACT OF DISCUSSION

Dr. Alfred Schalek, Omaha: I was very much interested in Dr. Kessler's paper, because I saw one of these rare cases about two years ago. My case had a peculiarity which I have never seen mentioned anywhere in having some of the features of epidermolysis bullosa; the least trauma would develop into a bulla. We have all come to consider pemphigus foliaceus a very hopeless condition with high mortality. I have treated various forms of skin disease with quinin internally, some of them with very good results. In one case of chronic urticaria it seemed to control the eruption, and I have also seen good results from it in lupus erythematosus. For these reasons I believe it may be worth a trial in pemphigus.

Dr. Richard L. Sutton, Kansas City, Mo.: The position occupied by pemphigus foliaceus among the bullous eruptions is a matter of more than academic interest. Recently, two of my students, Drs. Dannie and Smith, worked up a typical case of this disease quite thoroughly and with rather surprising results. The patient, a Pullman-car porter, was a man of 43 years in whom the disease had been present for over three years. Practically the entire surface of the body, with the exception of the mucous membranes, was involved. The *Bacillus pyocyaneus* was repeatedly obtained in pure culture from the contents of the bullae and from the serum which exuded from the skin at various points at which the epidermis was broken. At the time of admission the patient was so emaciated and weak that he had to be carried into the hospital. After nine weeks of bacterin therapy (autogenous vaccines being employed), the skin was entirely clear with the exception of an occasional distended bulla, and the patient's general condition was much improved. At this time, a 0.6 gm. dose of salvarsan was given, and the patient's skin promptly cleared up and he gained over 40 pounds in weight within less than one month. At present he is apparently well and attending to his regular duties. In this case I believe that the condition was simply a pemphigus chronicus, plus a pyocyaneous infection. It is probable that not all of the cases diagnosed as examples of pemphigus foliaceus are due to the same cause or causes, but the prompt and excellent results that followed vaccine and salvarsan therapy in this instance certainly were suggestive, to say the least.

Dr. William A. Pusey, Chicago: I have reported on a previous occasion a case of pemphigus foliaceus with a rather remarkable favorable result. This was a young man, a farmer, who came into my service in the Cook County Hospital showing all of the features of a well developed case of pemphigus foliaceus. The case was seen by several Chicago dermatologists and all agreed on the diagnosis. I gave an utterly unfavorable prognosis as to recovery and an opinion

Digitized by Google

that the case would probably drag on for a long time. In the course of six or eight weeks, however, to our great amazement and without any treatment of consequence, the disease entirely disappeared, and so far as I know, has never recurred. I have seen, I should think, ten or a dozen cases of pemphigus foliaceus and I have been rather impressed with the belief that it—and pemphigus in general—has a tendency to occur most frequently in farmers and those in allied occupations. I have a feeling that we shall learn in time that the course of pemphigus foliaceus is somewhat influenced by the age of the patient, and that the disease in younger persons offers a better prognosis than it does in the elderly. I think that in estimating the value of any method of treatment we must not fail to take into consideration the possibilities of spontaneous cure or improvement in these cases.

Dr. Howard Fox, New York: There are just one or two points that I should like to comment on. Last summer, together with my father, Dr. George H. Fox, I saw an absolutely typical text-book case of pemphigus foliaceus, and the interesting point of this case was that the patient, a woman had previously suffered from lupus erythematosus, for which she had been treated with iodin locally and quinin internally. Several months later she developed pemphigus foliaceus, which ultimately proved fatal.

Dr. H. H. Hazen, Washington, D. C.: I have had the opportunity of seeing four cases of pemphigus foliaceus during the past two years, and I have come to the conclusion that we have not yet reached an absolute classification of this disease. For example, there are cases of dermatitis exfoliativa, the so-called Ritter's disease, which are objectively the same as pemphigus foliaceus. As regards the causation of pemphigus foliaceus, Lipschitz has reported the presence of a distinctive organism in the lesions, a finding that I have not confirmed. As to treatment in one of our cases we gave two injections of salvarsan without any effect. One patient was apparently benefited by continuous tubbing. In another case, treated by keeping the patient covered with a dry powder, as suggested by Drs. Martin F. Engman and Charles J. White, no beneficial effect was observed. The Roentgen ray treatment was also unsatisfactory. I should particularly like to make the point that the lesions are autoinoculable. Serum from a vesicle rubbed into or injected into the skin of the same patient will cause a new lesion, whereas salt solution will not do this.

Dr. A. Ravogli, Cincinnati: I have at present a patient under my observation, a woman who has been under treatment for the past three or four years for pemphigus foliaceus. She has had numerous outbreaks of bullae. The bullae contain

Digitized by Google

little serum, and soon break. The skin was in such a condition that on merely touching her to give hypodermic injections in the parts not affected with bullae, some of the epidermis would detach and come out on the finger. In the treatment of this patient, in addition to quinin—which was not, however, given in the large and repeated doses suggested by Dr. Kessler—I have used the cacodylate of soda and an injection of staphylococcic vaccine. Nothing has done her much good. At present I am using an ointment of resorcin and salicylic acid (15 grains to the ounce) together with a little arsenic internally (Fowler's solution), and she is getting on fairly well.

Dr. J. B. Kessler, Iowa City: The treatment of pemphigus foliaceus outlined in my paper is not entirely new. Several years ago a writer, whose name I do not recall, recommended the use of large doses of quinin in pemphigus vulgaris. That gave me my cue, and I tried the drug in these two cases of pemphigus foliaceus with the happiest results. In order to secure these results, the quinin must be given in large, repeated doses. In one of my cases, that of the boy, I gave 4 grains every four hours, and later increased the dose to 7½ grains every four hours. These patients apparently tolerate the drug in large doses.

Digitized by Google

# RADIUM IN SKIN DISEASES

FRANK E. SIMPSON, M.D.
CHICAGO

The preliminary note that I present at this time with reference to the action of radium in skin diseases is based on studies made on forty-five patients with fifteen different skin affections who have had in the aggregate about one thousand applications of radium.

Some experiments made on guinea-pigs with the help of Dr. Korper of the Sprague Memorial Institute to determine the effect of radium on experimental cutaneous tuberculosis will be only briefly referred to here.

The whole subject of the physics of radium is on a well-established foundation. Radium gives off spontaneously two different therapeutic forces—the emanation and the rays. The emanation has been used principally in the domain of internal medicine.

In the treatment of skin diseases the rays are mainly utilized by simply applying the radium directly to the diseased area. A very useful modification of this method consists in the interposition of screens or filters between the radium and the skin. The use of screens was developed originally by Wickham[1] from a consideration of the different characters of the alpha, beta and gamma rays emitted by radium. The alpha and soft beta rays produce a dermatitis rather easily. The hard beta and gamma rays, isolated by screening out the alpha and soft beta rays, act deeply and produce little or no

1. Wickham and Degrais: Radiumthérapie, Second edition, 1912, p. 48.

Digitized by Google

superficial inflammation unless the action has been very prolonged.

Reaction in the tissues produced by radium may be, first, "selective." Certain vascular nevi may be dissipated without visible inflammatory changes in an absolutely unique manner.

Second, radium reaction may be "inflammatory." In practice, one utilizes, of course, both the selective and the inflammatory reactions in achieving results.

Taking as a type a radium applicator having a flat surface of 4 sq. cm. and containing 4 cg. of mixed radium sulphate and barium bromid (alpha rays 20 per cent., beta rays 76 per cent., gamma rays 4 per cent.), one may produce various results on healthy or non-inflammatory pathologic tissue. The reaction produced depends principally on the length and frequency of the exposure to the rays.

After an exposure of thirty minutes redness appears on the skin in about three days. This is accompanied by slight burning and itching. Desquamation occurs and in about three weeks the reaction has subsided. An exposure on three successive days, one hour each day, produces an inflammatory reaction that is marked and unique. At the expiration of about three days redness appears. The skin becomes itchy, somewhat swollen and tender to the touch. A crust gradually appears which is of greenish-yellow color and rests on a dry or slightly excoriated base. The crust, which may be 0.5 cm. thick, resembles in appearance that of impetigo contagiosa. The crust lasts for two or three weeks and may fall off spontaneously and renew itself several times. Finally, at the expiration of four or five weeks, a pink and then a normal skin surface is left.

In applying radium for curative purposes the personal factor is important. Regard must be paid to the exact character of the lesion in order to bring about a favorable result.

Digitized by Google

## REPORT OF CASES IN WHICH RADIUM WAS USED

The cases in which I have used radium may be briefly reviewed:

### EPITHELIOMA

I have treated about a dozen cases of epithelioma situated on the face. In this number are included two cases of epithelioma of the lower lip. In neither of these was there any demonstrable metastasis.

In one case, in which an epithelioma had existed at the mucocutaneous junction of the lower lip for three years, radium was applied unscreened for three hours and then with a silver screen (0.1 mm. thick) for four hours. The applications extended over several weeks. A slight dermatitis and some soreness of the lip followed which soon subsided. It would now be difficult to detect the site of the former epithelioma.

In a second case, an enormous epithelioma had been present on the lower lip for eight years. It had taken on great activity in the eight months prior to my observation and when first seen involved almost the entire lower lip. At first radium was applied unscreened. After three preliminary applications the exposures were continued through silver screens (0.1 and 0.5 mm. in thickness). The applications were made both on the external and internal surfaces of the lip. This "cross-fire" method, advocated by Wickham,[2] evidently allowed greater concentration of the rays at a depth without injury to the superficial tissues. In the course of two months the patient received twenty applications. While complete recovery has not yet occurred the progress has been very satisfactory. At the present time only a very slight infiltration marks the site.

I would not be understood as advocating this as the method of choice in epithelioma in this situation. In patients who refuse operation and in whom there is no evidence of metastasis, radium treatment has been shown to be effective. In ten cases of epithelioma of the rodent-ulcer type, situated on the temple, at the side of the nose and other parts of the face, I have obtained successful results with radium.

From present experience, the radium treatment of epithelioma may be summed up by saying that it is useful in the same general class of cases in which we now use Roentgen rays. Its effectiveness as compared with x-rays cannot now be decided. Much depends on the operator, the amount of radium available and the method of use. Only time and continued observation will determine this question.

2. Wickham and Degrais: Radiumthérapie, p. 77.

Digitized by Google

Wickham[3] has reported cases in which radium was successful in healing certain epitheliomas after Roentgen rays had failed. Doubtless the reverse may be true and some epitheliomas may be more amenable to x-rays than to radium.

In certain epitheliomas that are inaccessible to Roentgen rays because of their position in some cavity of the body radium occupies a unique position. I have treated an inoperable carcinoma of the cervix without producing, however, any appreciable improvement. This case had previously been subjected to injections of zinc chlorid which had caused sloughing and the radium treatments could not be carried out with the necessary vigor.

In a case of cancer of the cervix, under Wickham,[4] radium caused so great a change in the tumor that it was successfully removed, although previously regarded as inoperable.

In an inoperable cancer of the buccal cavity now under my care great improvement is being produced by radium.

Wickham[5] treated successfully a case of recurring carcinoma of the breast by injecting below the tumor 0.1 mg. of radium sulphate mixed with paraffin petrolatum, at the same time applying above the tumor an ordinary radium instrument.

Abbe's method of introducing radium tubes into incisions made in tumors should be mentioned.

Finally, although the use of radium has been extended gradually from small benign growths to large malignant tumors, the cases should be selected with the greatest care in order not to deprive patients of other treatment that may at times be more effective.

### OTHER CONDITIONS

*Angioma.*—Three cases have been treated. In a boy, aged 10, a flat angioma affected the left side of the nose, the inner canthus of the left eye and the adjacent part of the forehead.

3. Wickham and Degrais: pp. 155, 157.
4. Wickham and Degrais: p. 209.
5. Wickham and Degrais: p. 204.

Digitized by Google

In the second case, that of a man 38 years old, the right side of the neck was extensively affected. The third patient, a male baby, 6 months old, had a cavernous angioma of the lower lip. In the areas so far treated a beautiful smooth scar of satisfactory color has been produced, but as none of these cases has been completed, comment on them will be deferred.

In the hands of Wickham[6] radium therapy has had one of its most brilliant successes in the treatment of the different types of angioma.

The absence of pain and the beauty of the cosmetic result are noteworthy. The possible late development of telangiectases may slightly mar the final result, but these fortunately can be removed and to some extent precluded by avoiding too strong doses.

*Nevus Pigmentosus.*—A hairy, pigmented, verrucose nevus, 16 sq. cm. in extent, situated over the extensor surface of the left elbow in a young man aged 24, was successfully removed. The site of the former nevus is remarkably like normal skin. In these nevi the pigmentary layer must be destroyed, otherwise repigmentation may occur.

*Tuberculosis.*—One case of lupus vulgaris was treated with radium. A patch on the cheek of a child aged 12, which had been present for six years, was exposed for five hours in the course of ten days. Rather severe reaction followed but in six weeks complete recovery ensued.

*Tuberculosis Verrucosa Cutis.*—Two cases have been treated. In a man, aged 35, a verruca necrogenica on the palmar surface of the third finger of the right hand was given an exposure of three hours in the course of ten days. Moderate reaction ensued and this was followed by the complete disappearance of the lesion. In a girl aged 13, a similar lesion was present on the dorsum of the first phalanx of the right middle finger. This patient had, in addition, enlarged cervical lymph-nodes and kyphosis of the upper dorsal spine. An exposure of four hours was given in the course of three weeks. Normal reaction is now taking place so that the final outcome of this case has not been determined. According to Wickham[7] this type of tuberculosis is particularly amenable to radium.

*Syphilis.*—In a man, aged 40, with a syphilitic eruption appearing six or seven years after the primary lesion and consisting of large, flat, scaly plaques, radium was used experimentally for twenty minutes on several lesions. This was

6. Wickham and Degrais: Ibid., p. 250.
7. Wickham and Degrais: Ibid., p. 311.

Digitized by Google

followed by their prompt disappearance in less than three weeks, although the other untreated lesions persisted.

*Blastomycosis.*—In a man, aged 24, a patch of blastomycosis about 1 sq. cm. in extent, situated at the inner canthus of the left eye and involving the upper and lower eyelids, had been present for three months. The diagnosis was confirmed by the microscopic examination of a section. Radium was easily applied and was held in place by the patient. At the present time, normal reaction is taking place. The belief is entertained that on its subsidence recovery may occur.

*Sycosis Vulgaris.*—Two cases of sycosis vulgaris have been treated with radium. While neither case has progressed sufficiently to allow of a definite opinion as to its exact value in this affection it seems probable that radium will prove a great addition to our armamentarium. Depilation can be easily produced. Wickham[8] treated one case successfully by permanently removing the hair.

*Keloid.*—Two cases were subjected to radium. In one case, great improvement ensued but the patient was lost sight of before the final outcome could be determined. The second case is now under treatment and the result will be reported at a future time.

In the hands of Wickham[9] the various types of keloid have been particularly amenable to the selective action of radium.

*Hypertrichosis.*—In a man, aged 22, with an abnormal triangular patch of hair extending from the scalp to a point two centimeters below the hair line in the center of the forehead, five applications of radium produced complete and permanent alopecia. The quality of the skin from which the hair was removed is practically the same as that of normal skin. In certain types of localized hypertrichosis radium treatment seems to be the most effective method of relief.

*Dysidrosis.*—One case of dysidrosis of the palm was treated with radium. The patient had suffered from previous attacks on the hands and feet which had persisted for several months. Constantly recurring outbreaks of vesicles on the palm had prolonged the present attack for four months. Applications of radium, each lasting fifteen minutes were made. Five exposures brought about complete recovery in two weeks.

*Neurodermatitis.*—In a woman, aged 42, seen through the kindness of Dr. H. B. Thomas, a typical patch of neurodermatitis had existed on the left labium majus for eight years. No relief from the intolerable pruritus had been obtained by the ordinary methods. Radium was applied over the patch for ten minutes at a time at intervals of several days. Symptomatic recovery ensued after six treatments.

---

8. Wickham and Degrais: p. 352.
9. Wickham and Degrais: p. 231.

Digitized by Google

Four months later this case reported that the improvement had been maintained. Several cases of localized chronic eczema have also been treated with radical relief of the pruritus.

*Trichophytosis of the Finger-Nails.*—In a woman, aged 25 years, seen through the courtesy of Dr. Philip Shaffner, ringworm of the nails had existed for ten years. The diagnosis had been made by Dr. Shaffner by microscopic examination of the nail-substance and by cultures. On the left hand all the nails were involved except the little finger-nail. On the right hand the nails of the middle and ring fingers were affected. Four applications of radium, each lasting an hour, were made. At the expiration of about a week from the last application some soreness of the nail was complained of and slight redness of the peri-ungual tissue appeared. A week later a little seropurulent material could be expressed from beneath the free edge of the nail. Complete exfoliation of the nails has not taken place but the hope is entertained that with this occurrence the new nail may be free from the fungus.

*Lichen Planus.*—In a case of ordinary lichen planus with lesions of the scrotum and thighs, radium was very effective in relieving the itching. In a case of lichen planus verrucosus of extreme development, a number of warty plaques which were situated on the legs near the ankles, were treated with radium. The great rebelliousness of these plaques to all ordinary treatment except perhaps Roentgen rays is well known. While the progress in this case has been very satisfactory, further comment will be made at some future time.

*Psoriasis.*—Several cases of psoriasis have been treated with radium. Three or four treatments of five or ten minutes each are sufficient to remove a patch of psoriasis. In psoriasis of the nails, Blaschko[10] (quoted by Wickham) states that radium is superior to all other methods of treatment.

*Lupus Erythematosus.*—Ten cases have been treated. They varied in duration from six months to eighteen years and in severity from small patches, a centimeter in diameter, to areas involving nearly all of the nose, cheeks and ears. In one peculiar case, only the lower lip and backs of the hands were involved. The lip, which was thickly crusted, was given an exposure of thirty minutes. In three weeks the crust fell off and a practically normal surface was left which has remained well to the present time. Four of the remaining cases were well when last seen. All of the others have shown great improvement.

The treatment of lupus erythematosus is necessarily slow, particularly in the extensive cases, as each area involved must, of course, be subjected to treatment and

10. Wickham and Degrais: p. 345.

Digitized by Google

time must be allowed for the subsidence of the reaction which may be produced. Following the advice of Wickham,[7] the line of application of the radium was allowed to extend beyond the diseased area in order to preclude possible extension of the patch at the border.

An exposure of an untreated area for thirty minutes is followed by the appearance of increased erythema after about sixty hours. The slight itchiness of the disease is relieved. Swelling and some soreness of the patch ensue. Gradually a crust appears which, at the end of two weeks, may be several millimeters thick. The crust is very adherent and persists for three or four weeks. If it is detached during this time it is seen to rest on a slightly excoriated base.

Certain patches become normal after a single treatment. Frequently, however, slight scaliness and erythema persist and the exposure must be repeated. In a second or third similar exposure the patch reacts less markedly.

At the present time an exposure of about thirty or forty minutes is being given, followed in a few days by two shorter exposures of ten to fifteen minutes each. Patches covered by thick crusts or scales demand longer treatment than the more erythematous patches. While the capricious character of lupus erythematosus makes it difficult to estimate the effect of any treatment, radium is undoubtedly a great addition to our resources in this intractable affection.

59 East Madison Street.

## ABSTRACT OF DISCUSSION

Dr. M. L. Heidingsfeld, Cincinnati: My personal experience with radium has been somewhat limited. Some nine years ago, I used radium of moderate activity for a period of a year or more, and felt obliged to discontinue its use on account of negative results. Anyone personally acquainted with the work of Wichmann of Hamburg or Schiff of Vienna, cannot be otherwise than most favorably impressed with the wonderful results obtained from radium. These results speak for themselves. They cannot be obtained, however, unless

Digitized by Google

radium of a very high activity is employed. Wichmann, Schiff and others have steadfastly maintained that radium owes its disrepute to the fact that men have labored for results with a preparation that was inefficient. In my judgment, radium costing no less than from $5,000 to $10,000 in value and better twice that amount, alone suffices to obtain satisfactory results. In the last few years mesothorium, a much less expensive product, relatively speaking, has been substituted for radium. There are certain disadvantages, however, in connection with its use. It is not a staple preparation like radium, and the therapeutic results cannot be measured with the same degree of accuracy. Mesothorium increases in activity for a period of about five years, and gradually decreases in activity until it becomes almost worthless at the end of ten years. There is therefore danger of overtreatment in the early years and undertreatment in later years from this preparation.

Some of the most brilliant achievements of radium have been in connection with angiomata or vascular nevi, particularly those of deep-seated type, and in malignancy of the lip, mouth and tongue; owing to the inaccessible location of these lesions and the unfavorable nature for other forms of treatment, it fills a very valuable and indispensable position. Ordinary vascular nevi which are superficially located in the skin yield equally well to other measures, particularly to carbon dioxid snow. The cosmetic results from radium are most excellent.

Dr. M. L. Ravitch, Louisville: In what we have heard about radium, I think the psychologic effect had more to do with the cures than the radium itself. I have given radium a thorough trial and I am compelled to confess that my results with it were unsatisfactory. We have practically no knowledge regarding the action of radium and its method of penetration, and I have never been able to become enthusiastic regarding it, in spite of the very miraculous results with it as reported by Dr. Robert Abbé of New York in a paper which, I believe, he read before the International Medical Congress in 1907. We have certainly obtained no such results with radium here. Hallopeau reported results quite opposite to Dr. Abbé's, and he warned the profession against its careless use. Radium has a greater uniformity than the Roentgen rays; still we do not know what injury may occur from gamma rays with their deeper penetrating power.

Dr. Joseph Zeisler, Chicago: Lest any of you might be tempted by Dr. Heidingsfeld's remarks in regard to the cheapness of mesothorium, I might say that it is still selling at 150 marks per milligram, and as it is necessary to have at least 20 mg., the cost would be 3,000 marks, or $750. I have seen several of Dr. Simpson's cases which were treated with radium,

Digitized by Google

and in some of them the results were very satisfacory—about the same as we have seen from the Roentgen ray and other methods. The results in lupus erythematosus were not sufficiently brilliant to cause me to become enthusiastic regarding them, and in dealing with a new therapeutic agent, like radium, I am led to believe that we are apt to lose sight of older and equally satisfactory methods. I recently saw a case of senile keratosis of the face and hands in which some of the lesions were about to degenerate into epithelioma. With the idea of saving the patient a long-continued Roentgen ray treatment or the rather painful refrigeration method, I prescribed elastic collodion, with 5 per cent. salicylic acid and a small amount of bichlorid of mercury, and under application for five days these keratomas disappeared promptly.

Dr. Fred Wise, New York: I should like to ask Dr. Simpson the size of the keloids in which he used the radium.

Dr. Alfred Schalek, Omaha: Even if we have no knowledge regarding the action of radium, that is no reason why we should not employ it, because the more we use it, the more we shall learn about it.

Dr. H. R. Varney, Detroit: Dr. Simpson has given us a preliminary report on the action of radium in skin diseases in which he has covered a variety of dermatoses. I trust that he will continue his work with this agent and report his results at a subsequent meeting. My experience with radium has not been so encouraging as that of the reader of the paper. I used it for some years without resulting benefit. It is possible and quite probable that the specimen I secured was not sufficiently active.

Dr. Frank E. Simpson, Chicago: In presenting this preliminary report on the action of radium in skin diseases I did not hope to escape a certain amount of criticism for being perhaps unduly enthusiastic about the value of this agent, nor am I inclined to retract anything I said regarding it. My interest in radium dates back to a visit I paid Wickham about two years ago, and any one who has visited him at his home in Paris and has seen the results he obtained would feel equally enthusiastic in regard to the value of this remedy. I feel assured that with a similar preparation of radium we could all get the same results as he has demonstrated. Psychology has nothing to do with it. The preparation of raidum I use has an activity of 500,000, and was purchased through Wickham himself. Of the two cases of keloid in which I used the remedy, one was an acne keloid, which improved considerably. The other was an extensive keloid on the upper arm of a young girl; this has also shown marked improvement, but the case is still under treatment.

Digitized by Google

# SALVARSAN VERSUS PROFETA'S LAW

AUGUSTUS RAVOGLI, M.D.
CINCINNATI

The theory of syphilitic immunity, as established by Ricord, has long been upset. If there is a syphilitic immunity in infected persons this is due to two circumstances combined: first, to a saturated condition of the fluids and solids of the organism with spirochetes and their toxins; second, to the capacity of the organism to produce antibodies to counteract the poisonous influence of the virus. With time the spirochetes become inactive and the disease, in a latent condition, loses its poisonous influence. The Wassermann test in these conditions turns negative, and yet the patient is not cured, and may show syphilitic signs of a late type. The attenuation of the virus is seen also by the observation of syphilitic families, when we see the first pregnancy end in miscarriage, the second in premature birth, the third child born alive, and only after a few days showing some syphilitic manifestations, and others born well, showing only late, faint signs of the disease.

The diminution in the poisonous intensity of the virus occurs slowly and at times in a saltatory way. In some syphilitic families a healthy child is born, and the next child will show signs of hereditary syphilis.

I shall repeat my statement, made at other times, that the spirochetes in the organism of the father, after a certain time and after some treatment, are unequally distributed, hiding themselves in those organs and those tissues which are not so easily affected by the antisyphilitic remedies. Whether an infected or a healthy child

Digitized by Google

Lesion on left side of baby's chin, and mucous patch in right corner of mother's mouth.

Digitized by Google

Digitized by Google

is born to him may depend on the presence of the spirochetes in the semen.

It is exceedingly rare and difficult, however, to find that the mother who gives birth to a syphilitic child is not infected with syphilis. The Wassermann test of to-day has already destroyed Colles-Baumes' law. They claimed that mothers bearing syphilitic children from fathers affected with latent syphilis escape the disease, or at least pass through a modified form of it. Their children, affected with mucous patches on the tongue or the lips, suckle the breast of the mother without infecting her; but if they were to suckle the breast of any other healthy woman, she would be positively infected.

Montesano[1] writing on Colles' law reported a case of a woman, who returned, after four years' separation, to live with her husband who had been infected. She became pregnant and gave birth to a child apparently well. She never had anv signs of syphilis until two years later. Then the child was taken with epileptiform spasms and the mother had ulcerative patches between the toes. Wassermann test of both the mother and the child proved to be positive. The woman had been declared immune according to Colles' law, and yet she had a latent syphilis. The immunity of the mother who has in her uterus a syphilitic fetus is only ephemeral. She has not escaped infection as Ricord claimed, but has latent syphilis.

Profeta's law[2] maintains just the reverse of what has been asserted to happen to the mother and to the child. It was maintained under his theory that this child coming from syphilitic parents has acquired a congenital immunity, which protects it, at least temporarily, from syphilitic infection. This occurrence was explained in two ways: either that the placenta would be able to oppose a strong barrier to the entrance of the spirochetes, protecting the fetus mechanically, or that the child, satu-

1. Montesano, V.: Osservazioni sulla legge del Colles, Report Soc. ital. di dermat. e sifil., 1913.
2. Profeta, G.: Sulla sifilide per allattamento, Sperimentale, 1865.

Digitized by Google

rated with antigens arising from the system of the mother, would be protected and immunized from subsequent infection.

Profeta's law had a strong support in a series of observations from Profeta[3] himself, and later from Caspray, Finger,[4] Ogilvie,[5] Bruggeman and Glück.[6] But in recent years exceptions have multiplied to such an extent that I must agree with Matzenhauer[7] that it has no more reason to be called a law.

To-day we can say that there is no congenital or hereditary syphilis without syphilis of the mother. Immunity, either active from the passage of toxalbuminous substances, or passive from antigens passing from the mother to the fetus or vice versa, can no longer be maintained.

After these observations I shall refer to the clinical case, the subject of my late study and the motive for this paper.

*Patient.*—An Italian laborer came to consult me for a lenticular papular syphilid with all the accompanying symptoms. Injections of gray oil were given and the eruption was gradually disappearing and the man was feeling much better. He was not seen for some time until he came with his wife, who had recently come from Italy to join him. He had infected his wife, of course, and she also had papular syphilid. It was at the beginning of the new era of treatment, the salvarsan, which had to accomplish the *sterilisatio magna*, and both husband and wife were treated with two intramuscular injections in the lumbar regions with a full dose of 0.6 gm. After the injection both improved remarkably. The woman was in the beginning of pregnancy. Her husband had not shown any symptoms since the injections; Wassermann and Noguchi tests were found negative. The woman could not be induced to have a Wassermann test made. She had one necrotic abscess in the place of one of the salvarsan injections, which healed up in a short time after due treatment. For some time I lost

3. Profeta, G.: Variazioni su motivi di sifilide congenita per allattamento, Gior. ital. d. mal. ven. Milano, 1900, p. 165.
4. Finger: Ueber die vererbte Syphilis, Finger Arch.
5. Ogilvie: Congenital Immunity to Syphilis and the So-Called "Law of Profeta," Brit. Jour. Dermat., 1899.
6. Glück: Ueber das sogenannte Profetasche Gesetz, Deutsch. med. Wchnschr., 1902, No. 9.
7. Matzenhauer, R.: Die Vererbung der Syphilis, Ergänzungsheft, Arch. f. Dermat. u. Syph., 1903.

Digitized by Google

sight of this couple. The woman came again with a well-nourished, well-developed baby 8 months old, which when carefuly examined showed no signs of lues. She related that the pregnancy at the time of the syphilitic manifestations ended in miscarriage. Since the salvarsan injections she had seen no signs of the infection, and she had given birth to the child she had in her arms. She came on account of a sore under lip, which was touched up with a solution of bichlorid 1:100 in alcohol and ether. The sores in her mouth were undoubtedly mucous patches of the mucosa. A few weeks later she came on account of the child, who had an initial lesion on his chin, as shown by the illustration, with enlargement of the submaxillary and cervical lymph-nodes. At the same time the face, chest, back, arms, thighs and legs were covered with a macular syphilid (roseola). I had the picture taken to show the mucous patch at the right corner of the mouth of the mother, and the initial lesion on the left of the chin of the child.

COMMENT

The child was perfectly well and had never shown any sign of luetic taint. The father, with the mercurial treatment and after the salvarsan injection had shown no further symptoms, had negative Wassermann, and was able to generate a child free from lues. The mother, also, showed no signs of lues for some time and it seems that the active spirochetes were killed. I would say, with Pollitzer, that some of the inactive spirochetes still remained in her tissues, and were not allowed to pass through the placentary filter. This case gives no support to the idea of Matzenhauer that the fetus receives infection from the mother only; it would rather maintain the opinion of Hainiss[8] that the cause of hereditary lues is the infected sperm.

The father had shown no symptoms for a long time, the Wassermann test had been negative, and he did not communicate the disease to the offspring. The mother, at the time of conception, although still having spirochetes in her system, did not communicate lues to the offspring. Some months afterward she showed mucous patches of the mouth. The receptivity of the infection

8. Hainiss: Budapest Orv. Usag., 1912, No. 11; ref. Dermat. Wchnschr., 1912, No. 516, p. 1690.

Digitized by Google

by the child shows that he had no immunity whatever and his own mother with her saliva containing spirochetes in a maternal kiss inoculated him. The result was an initial lesion, and secondary eruption. If the Profeta law had any bearing the mother could never have inoculated her child, because it would have been protected by immunity.

Immunity in syphilis does not exist, and when a child born from a syphilitic mother is not infected that shows that he has latent syphilis, which sooner or later will manifest itself. In all cases of doubtful condition of infection examined by Linser,[9] Wassermann was found positive. I must state with Bergrath[10] that children are born either infected or healthy. Immunity does not exist, and what had been considered as immunity was only a latent condition of the disease.

Immunity against a reinfection is produced only by the existing syphilis, while immunity after perfect recovery, according to the experiments in animals carried on by Neisser, has to be entirely excluded. When syphilis is cured any immunity disappears. Moreover, while the disease is attenuating gradually, according to Finger, slight reinfection may occur.

I can state, therefore, that the child was perfectly free from syphilis. It is necessary to admit that the father was cured of syphilis. The mother was not cured because she showed later syphilitic mucous patches, but at the time of the pregnancy the spirochetes were not able to reach the fetus, which developed healthy and free from syphilis. The mother, neglecting treatment, allowed the spirochetes to become active again, and she showed mucous patches, which infected her child.

Since the use of salvarsan we have witnessed admirable results. Indeed, before the use of salvarsan cases of syphilitic reinfections were reported as of rare occur-

9. Linser: Sitzung des med.-natur. Verein Tübingen, February, 1909, quoted by Bergrath (see Note 10).
10. Bergrath: Ueber Syphilis congenita in der II. Generation, Arch. f. Dermat. u. Syph., 1910, cv, 143.

Digitized by Google

rence and were also questioned. After salvarsan, cases of syphilitic reinfection are numerous and every day increasing. Ascertained cases of syphilitic reinfections have been recently reported by Covisa and Nonell,[11] Mrongowius,[12] L. Jullien,[13] Belin, Milian and Amodrut,[14] Fournier,[15] Wüstenberg[16] and many others. This shows that by means of salvarsan, either alone or in association with the other antisyphilitic remedies, we obtain complete recoveries in syphilis.

Harold J. Levis[17] reported a case of severe syphilis in a woman who was in her fourth month of pregnancy. After two intravenous injections of salvarsan, she recovered and at full term she gave birth to twins in good health.

CONCLUSIONS

As a conclusion we can state that in the presence of the Wassermann test and of the administration of salvarsan, Colles-Baumes' and Profeta's laws have no right to existence. Syphilitic immunity lasts as long as the disease lasts, consequently the child in this case was born perfectly free from syphilis, although born from a woman who later showed syphilitic symptoms.

The opinion of Pollitzer[18] that salvarsan kills the active spirochetes and allows the inactive spirochetes to escape unaffected finds support in my case, in which the mother had conceived and carried to full term the child free from syphilis, when she still had spirochetes in her system.

---

11. Covisa and Nonell: Actas Dermosifilographicas, Madrid 1911, No. 1.
12. Mrongowius: Russky Vratsch, 1912, No. 26; ref. Derm. Wchnschr., 1912, No. 51a, p. 1563.
13. Jullien L.: Bull. méd., 1912, p. 715; Derm. Wchnschr., 1912, No. 51a, p. 1564.
14. Belin, Milian and Amodrut: Reinfectio Syphilitica nach Salvarsan, Bull. méd., 1912, p. 195; ref. Derm. Wchnschr., 1912, p. 1167.
15. Fournier F.: Rev. prat. d. org. gén.-urin., September, 1912.
16. Wüstenberg: München. med. Wchnschr., 1912, No. 30.
17. Levis, Harold, J.: Salvarsan in Pregnancy, THE JOURNAL A. M. A., Aug. 24, 1912.
18. Pollitzer: Salvarsan, New York Med. Jour., Feb. 4, 1911.

Digitized by Google

In this family salvarsan had cured the father, had operated a great improvement in the condition of the mother, and had saved the child from maternal syphilitic infection.

348 Bryant Avenue.

## ABSTRACT OF DISCUSSION

DR. ALFRED SCHALEK, Omaha: I believe that in the light of our present knowledge of syphilis, some of the laws regarding the transmission of the disease might well be regarded as obsolete. Statistics show that 100 per cent. of women with syphilitic children give a positive Wassermann, but the children of a syphilitic mother do not always show such a reaction. There is no acquired immunity in these cases, and I trust that the writers of text-books on the subject of syphilis in the future will revise these old ideas, which have been accepted and unquestioned for so many years.

DR. M. L. HEIDINGSFELD, Cincinnati: If Dr. Ravogli's premises are well taken and his conclusions properly drawn, this case again upsets our ideas in regard to Profeta's and Colle's laws, which we were on the eve of believing to be entirely cleared up by the Wassermann reaction. The Wassermann reaction has apparently shown that these so-called "laws" do not obtain; that cases of supposed immunity were apparent, rather than real; that an active infection on the part of either the mother or child, before the birth of the child, was common to both; that the circulation between mother and child was absolutely intimate, and that the all-pervading spirochete must find ready intercommunication between the two.

I do not wish to question Dr. Ravogli's diagnosis or his statement of clinical facts. His clear, clean-cut description does not leave room for any serious question regarding the main points of the case. I think, however, that this case must be accepted with the reservation that preexisting syphilis has not been effectively ruled out in the child. A Wassermann examination of the child shortly after birth would have cleared up the situation, and this, the doctor admits, was not done. The photograph bears out Dr. Ravogli's statement that the sore on the lip has the appearance of an initial lesion and the eruption on the body, that of an early secondary. The characteristic adenopathy, however, is lacking. It seems to me that the eruption on the body may be a clinical relapse, which we so often see after salvarsan treatment, namely, a comparatively earlier type of clinical relapse than we ordinarily see after other methods of treatment. The sore on the lip also has the clinical features of a superadded

Digitized by Google

infection, which Finger has so characteristically and classically described, when fresh spirochetes gain entrance to an already infected individual. This superadded infection may have come from the luxuriant mucous placques of the mother or some other source.

Dr. A. Ravogli, Cincinnati: In answer to Dr. Heidingsfeld I would say that this child was perfectly well, without any enlarged lymph-nodes, and showed no suspicion of syphilis. No Wassermann test was made at that time, therefore, as there were no indications for it. After the appearance of the initial lesion on the chin, however, there was no doubt in my mind that it represented a syphilitic infection, and improvement occurred under small doses of calomel, which is my usual treatment of syphilis in children. I am convinced that it was not a case of re-infection and that the infection came from the mother, in a perfectly healthy child.

Digitized by Google

# A COMPARATIVE STUDY OF ANTIGENS FOR THE WASSERMANN REACTION

H. R. VARNEY, M.D.
AND
F. W. BAESLACK, M.D.
DETROIT, MICH.

## HISTORICAL REVIEW

In 1901, Bordet and Gengou published the method for complement-fixation, which was designed for the purpose of detecting antigens; that is, such bodies as are capable of producing antibodies, as well as a definite group of serum substances, probably amboceptors, the nature of which is not yet determined. It is possible by this method to determine, by the use of a known antigen, whether a certain serum contains the specific amboceptor, or reversely, one may determine by means of a known serum whether the substance used as antigen contains the antigen bodies. Neisser and Sachs proposed the use of this method for the differentiation of albumin. Wassermann, Neisser and Brück were able to demonstrate, in the serum of monkeys which had been previously treated with extracts of syphilitic organs, the presence of substances which gave complement fixation with syphilitic extracts. Detre, as well as Wassermann, Neisser, Brück and Schucht, found the same substances in the serum of syphilitic patients. Their early experiments, however, gave very inconsistent results. Citron was the first to recognize that the amounts of antigen and serum employed by the former authors had been too small and that the influence of the specific medication on the reaction was unknown to them.

Digitized by Google

Porges and Meier, von Landsteiner, Müller and Pötzl and later Yamanouchi and others pointed out independently that a substance could be obtained by extracting syphilitic and normal human liver as well as other organs with alcohol, which, when mixed with the serum of syphilitics, gave rise to complement fixation, and which to a certain degree could replace the syphilitic antigen. Porges and Meier, as well as Landsteiner, incline to the view that the alcohol-soluble substance is a lipoid closely related to lecithin, while Levaditi and Yamanouchi ascribe less significance to the lecithin and consider the bile salts as the important substances. The complement-fixation tests carried on by Wassermann and Citron with various colloidal substances such as glycogen, albumoses, peptone, lecithin, oil, gelatin, as well as the experiments of Landsteiner and Stanovic with other colloids, led Citron and Wassermann to the assumption that the cause of the complement fixation is a chemico-physical change of the molecule due to its entering into combination with some other substance. The experiments of Seligmann also prove that in colloidal reaction with or without precipitation complement may be absorbed. The disappearance of the complement is not due to the molecular condition as such, but is due to the changed condition of the colloids. While this does not offer any explanation of the specific immunity reaction, it shows that aside from the immunity reaction there coexist other definite chemical reactions which cause the disappearance of the complement. This in no way alters the great value of the complement fixation test for the biologic diagnosis of infectious diseases, for it is the special property of immune serums to influence to a greater degree that colloid which is their antigen.

These findings induced Wassermann to separate the complement fixation in syphilis from the generally accepted antigen-antibody hypothesis for other infectious diseases, for he assumed that all antigens must be albumins or derivatives of albumins, without considering

Digitized by Google

DEC 20 1921
LIBRARY



that some lipoids or lipoid-albumin combinations might be antigens also. The experiments of Metchnikoff and those of Deyke Pasha and Reschad Bey point to the fact that it is possible to stimulate the organism to the formation of reacting agents, similar to antibodies, by the injection of fat-like substances. The cobra-lecithin experiments should also be mentioned in this connection. It was pointed out by Citron that the injection of animal and other poisons with lecithin causes the formation of toxolipoids which may act as antigen, that is, produce antibodies. Such antibodies against the syphilitic toxolipoids may have a lipoidophil group which is brought out in the admixture with lecithin.

The fact that the serums of luetic patients are rich in ferments capable of splitting certain fats and lipoids and the presence of such ferments to a lesser degree in the serums of patients suffering from other infectious diseases, such as leprosy, tuberculosis, scarlet fever, etc., may be the reason why such serums react with syphilitic antigen. Thus it is possible that in the Wassermann reaction we are dealing with several distinct complement-fixation reactions of entirely different character, one of which may be specific.

In spite of the fact that the Wassermann reaction is as yet unexplained, it is widely used for the diagnosis of syphilis. The aqueous extracts of the syphilitic liver and spleen were, on account of their instability, displaced by alcoholic extracts of these syphilitic organs. The difficulty of obtaining syphilitic fetal tissue also had its influence in stimulating the search for some substitute as antigen. More recently acetone has been employed as extractive, because it is supposed that such extracts contain substances which approximate the syphilitic antigen more closely, and thus permit of a more delicate reading of the test. It does not fall within the scope of this paper to review the extensive literature dealing with the various antigens employed by the experimenters in this field of research. The extracts employed

Digitized by Google

have been either specific, such as were obtained from syphilitic tissues by the use of water, alcohol, or acetone as extractives, or they have been non-specific extracts made from heart muscle, liver and brain of guinea-pigs and cattle. Aside from these extracts, combinations of chemical substances, such as Schurmann's and those given by Sachs and Rondim, have been employed as antigens in this reaction. From this it appears that normal tissue contains substances, possibly to a lesser degree, as has been shown by Much, which have the power to absorb complement.

Aside from the use of artificial antigens, there have been other modifications of the Wassermann reaction; however, none of these modifications have as yet increased the clinical value of the test, nor has any attempt to simplify the method been suggested, which does not at the same time sacrifice considerably its accuracy.

In the course of the inoculation experiments of four strains of the *Spirochaeta pallida,* which have been carried on in rabbits at the Research Laboratory of Parke, Davis & Co., it seemed that the white, glistening gumma, which contains practically nothing but spirochetes and the products of their metabolism, might offer material for the preparation of antigen for the Wassermann reaction, which would possess more of the specific antigen bodies than any other antigen yet used for such purposes. The antigen thus prepared was made from lesions caused by the four strains of the organisms. We had, therefore, a specific and to some degree polyvalent antigen. The four strains of *pallida* have been transplanted now for over a year, and the lesions which these organisms produce are free from secondary infection. No antigen was prepared from cultures of the organism, since the culture does not afford a sufficient amount nor could the mediums in which the *pallidae* were growing be separated from them. It seemed that the extract of organisms and culture mediums would afford us no more specific anti-

Digitized by Google

gen than had been employed by others thus far. The syphilitic gumma frequently replacing one half and more of the testis seemed better suited for this purpose, since all the non-infected tissue could be trimmed away, and only the grayish-white gumma used. The term "gumma" is here used not in its strictest sense. The lesion produced by the action of the *pallida* in the gland proper, is one of clearly circumscribed mucoid degeneration. Superficial chancres were not employed since these are usually contaminated with other bacteria.

The antigens were prepared as follows: The lesions were carefully freed from the tissue not involved, ground up fine and weighed. The material was then frozen in an ice and salt mixture, and dried *in vacuo* over sulphuric acid. When completely dry, it was placed in physiologic salt solution to which 0.3 per cent. trikresol had been added. The ratio of tissue to salt solution is 1:4. This tissue suspension was shaken for twenty-four hours and placed in a sterile amber glass-bottle in the refrigerator for three days to allow the tissue to settle. This was our aqueous antigen.

The alcoholic antigen was prepared in the same way that the regular stock syphilitic fetal liver antigen is prepared.

The acetone extract was prepared by placing the ground-up and dried tissue into Merck's C. P. acetone, taking for every gram of tissue 20 c.c. of acetone. This was allowed to stand in a dark bottle at room temperature for eight days, filtered and evaporated at 37 C. (98.6 F.).

The residue was taken up with C. P. methyl alcohol, using one hundred parts of the methyl alcohol for every gram of residue. The acetone residue contains a substance which is not soluble in methyl alcohol. The methyl-alcohol-soluble extract is admixed with ten times its volume of physiologic salt solution for the test.

These three extracts of gumma of rabbits were tested against the alcoholic extracts of syphilitic fetal liver, and

Digitized by Google

in our last experiments, the acetone-insoluble portion of beef heart.

Practically every antigen has the power to bind some complement. And the reason for the diversity of results obtained by some investigators on one and the same serum does not lie so much in the method employed as in the proper titration of the extract employed as antigen.

The value of a certain extract is usually determined by a preliminary experiment, usually according to Wassermann, in which a unit of the antigen gives complete fixation when admixed with a unit of luetic serum, while normal serums give a negative reaction. Any antigen fulfilling these requirements is considered satisfactory for this reaction.

If increasing doses of an antigen are tested for their activity in the seroreaction in syphilis, then it is shown that very small amounts will not bind the complement even in cases of florid syphilis. As the dose of the extract is increased, the fixation of the complement occurs with greater frequency, so that serums of latent syphilitics also react. If the amount is increased still more, the serums of patients not syphilitic will give positive reactions. And if the dose of the extract is carried still higher, we find that serums of normal healthy individuals give the reaction. The amount of antigen is then able to bind all the complement. It thus becomes evident that only such amounts of antigen should be employed in syphilis as will bind the complement only with luetic serums. Thus the Wassermann reaction is specific only within certain limits of the doses of antigen. For this reason the extracts were tested for their power to bind complement.

Increasing amounts of the extract are placed with the amount of complement usually employed in the seroreaction in the incubator, then amboceptor and sheep blood corpuscles are added. For the test only one-half of that amount is used, which clearly indicates fixation (*Eigenhemmung*).

Digitized by Google

### DETERMINATION OF THE SENSITIVENESS

In the serodiagnosis of syphilis, it is not so much a question of obtaining fixation of complement with undoubted cases of syphilis, as of determining a fixation of complement in the doubtful cases, which determine for or against syphilis. Complete binding of the complement is practically uniform with all extracts, but the cases demanding especial attention are those which show only partial complement fixation. Such cases may be overlooked by an observer who does not work with a sensitive antigen, for which reason it is not advisable to take the serum giving a strongly luetic reaction, for a positive control, but one which lies on the border-line, that is, serums that give a weak positive reaction, such as latent luetics, and those having sclerosis. Such serums are tested with varying amounts of extract according to the usual method, beginning with minute dilutions of antigen to the largest permissible.

### DETERMINATION OF THE SPECIFICITY

It is evident that for this purpose not only serums of normal individuals should be employed, but also serums which, from experience, at times give a positive Wassermann reaction. It has already been pointed out that in such cases we may not be dealing with the same biologic process which takes place in the serum of a luetic, but with a non-specific process which simulates the specific reaction in syphilis. Many serums from cases of various general diseases contain substances which inhibit hemolysis. If to such serums antigen is added which also contains bodies capable of binding complement, we are able to observe a summation of these two binding substances which absorb all the complement.

The specificity of the antigen used was determined by the luetin reaction, in so far as this reaction may be called specific. Extract of the gumma gave positive reaction in tertiary cases of this disease.

Digitized by Google

These comparisons of the antigens of gumma cover only the preliminary stages of the work we have begun. The antigens prepared from the several strains of the spirochetes are more active and for this reason had to be diluted from ten to twenty times more than the ordinary antigens prepared from syphilitic fetal organs or normal tissues. This high dilution of the antigen minimizes the physical influence, which strong alcoholic antigens exert on the serums to be tested. The antigens when admixed with physiologic salt solution were practically clear, differing in this respect from other antigens which in dilution show milky white turbidity. Another difference noticed between the rabbit gumma antigen and other antigens is the more delicate reading of the results of the reaction. The cases of doubtful clinical diagnosis are more clearly brought out by these antigens.

The sensitiveness of these antigens to luetic serums led us to test them against serums from leprosy and scarlet fever. Through the kindness of Dr. Guy L. Kiefer, health officer of Detroit, we were able to obtain serums from scarlet fever patients while the disease was in its eruptive stage and different periods following this stage. The leprosy serums included were obtained through the courtesy of Dr. James MacFarlane Winfield of Brooklyn, to whom we desire to express our thanks.

The syphilitic lesions in rabbits permitted us to obtain antigens which to a degree are more specific than the antigens generally employed, since these gumma contain the spirochetes in large numbers free from contamination. At the same time we were reasonably certain that our antigens were free from the bile salts which possibly are present in the antigens made from fetal syphilitic livers.

The fact that Schwartz and McNeil were able to improve the fixation of complement in gonorrhea by combining twelve strains of the gonococci of their antigen led us to combine the four strains of the *pallida* for the antigens we employed. By so doing, we increased

Digitized by Google

the efficiency of the antigens. The reaction was negative, however, in the serums of patients having just passed the eruptive stage. The serums of leprosy patients were also positive, yet to a less degree than the luetic controls. How far this reaction is due to the leprosy per se, it was impossible for us to determine.

### SUMMARY AND CONCLUSIONS

1. The use of syphilitic gumma in the testis of rabbits yields a more specific antigen than any obtained from other syphilitic or normal tissue.

2. The combination of a number of strains, giving a polyvalent antigen, increased the value of the antigen, permitting the diagnosis of clinically doubtful cases.

3. Aqueous antigens lose their strength in about one month while those prepared with acetone and alcohol are stable.

From our data, we incline to the view that in the Wassermann reaction of syphilis, we may be dealing with three distinct reactions. First, we deal with the antibodies produced against the causative organism—if such antibodies are produced; next, we are dealing with substances, possibly antibodies, directed against bacterial lipoids, and, finally, with a group of substances, autolytic in nature, which the tissues of the body evolve against the toxic substances resulting from the influence of the *Spirochaeta pallida* on the tissues.

Washington Arcade.

### ABSTRACT OF DISCUSSION

Dr. Howard Fox, New York: The antigen is the all-important factor in the Wassermann reaction, but the attempts that have thus far been made to standardize our preparations have not been particularly successful. It would be a great step in advance if we could find a standard antigen which every one could use, as in that way there would be fewer divergent results from different laboratories. During the past year I have used the alcoholic extract of normal heart, titrating the complement and using decreasing amounts of the serum of the patient. By this method I have obtained better results than I did formerly with the alcoholic extract of fetal liver.

Digitized by Google

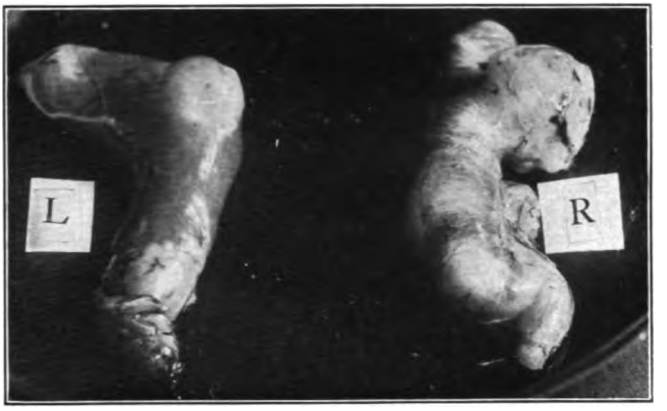


Fig. 1.—Syphilitic gumma of testis of rabbit from which antigen was prepared.

Fig. 2.—Luetin reaction obtained from gumma in rabbits used for the preparation of antigen. Control in center.

Digitized by Google

Digitized by Google

Dr. J. Frank Waugh, Chicago: There is one other antigen which I do not think has been mentioned. Noguchi has done a great deal of work on the serodiagnosis of syphilis, and in one of his articles on the subject he mentions an insoluble acetone antigen. Dr. Harris gave me some soluble acetone antigen, and on testing it, I found it very efficient. The acetone extract gives a stronger reaction in some cases than the alcoholic extract. In the last year I have tried and compared both the alcoholic and the aqueous extracts with the acetone extract and have found the latter just as efficient. I agree with Dr. Fox regarding the importance of a strong, standard antigen.

In the *Deutsche medizinische Wochenschrift* (Dec. 5, 1912), O. Stiner reported his experiences with the use of acetone extracts. He reports that in some cases of positive lues, in which alcoholic extracts gave negative results, positive reactions are secured with an acetone-liver extract.

Dr. M. L. Heidingsfeld, Cincinnati: I take exception to Dr. Varney's statement that the gonococcus complement-fixation test is more reliable than the Wassermann, in order to spare the Wassermann too much undeserved disrepute. Theoretically, the gonococcus test should be more reliable than the Wassermann, but experience has shown that the Wassermann is far the more reliable of the two. The Wassermann never errs on the unsafe side, and is a reliable procedure if the details are carefully and properly carried out. As Wassermann has pointed out, there is a fundamental reason for every step of the reaction. Some of the modifications may be more delicate, but they are at the same time the less reliable.

Dr. Rudolph Buhman, St. Louis: Did Drs. Varney and Baeslack use a watery or an alcoholic preparation as an antigen?

Dr. H. R. Varney, Detroit: I thoroughly agree with Dr. Fox that what we are searching for is a standard antigen, and that when it is found we shall have more uniform laboratory reports. Regarding the preparation of the antigen, the aqueous, acetone and alcoholic were used and checked up in series.

Regarding my estimate of the comparative accuracy of the Wassermann and the gonococcus fixation tests, which Dr. Heidingsfeld criticized, I would say that, so far as I have been able to follow the laboratory records, I am able to assert that by the fixation test it is possible to pick out the diplococcus of Neisser from a large family of similar organisms, which is proved clinically, while with the Wassermann test we cannot with our present knowledge positively exclude other diseases, as tuberculosis, scarlet fever or leprosy.

Digitized by Google

Dr. F. W. Baeslack, Detroit: The delicacy of the test depends largely on the titration of the antigen. We may titrate for its delicacy and sensitiveness, and it is only when tested against weak syphilitic cases that a real idea of the value of the antigen is obtained. It is in the careful titration of the antigen that the secret lies, and what we are searching for is a reliable antigen.

Digitized by Google

# THE HISTOPATHOLOGY OF POMPHOLYX

RICHARD L. SUTTON, M.D.
KANSAS CITY, MO.

Pompholyx was first described, as a form of dyshydrosis, by Tilbury Fox,[1] who was of the opinion that the condition was characterized essentially by "the retention in the follicles of the skin of sweat, rapidly and freely excreted," and believed that the affection bore the same relation to the sweat follicles that acne vulgaris does to the sebaceous glands. Hutchinson[2] who independently recognized and described the disease at about the same time, was opposed to this view, and, basing his argument on the symmetry and the spontaneous appearance and disappearance of the clinical manifestations, and on the fact that the condition was seen most frequently in persons whose vitality had been lowered by worry, overwork and similar agencies, concluded that it was an acute, inflammatory disease of the rete, neurotic in origin. He[3] suggested for it the name "cheiropompholyx."

Robinson[4] of New York first examined the lesions microscopically, and also analyzed the contents of some of the vesicles. The results of his investigations convinced him that the condition bore no relation to the coil-glands or ducts, and, in view of the fact that the

1. Fox, Tilbury: Dyshydrosis, Am. Jour. Syph. and Dermat., 1873, p. 1; Clinical Lecture on Dyshydrosis, an Undescribed Eruption, Brit. Med. Jour., 1873, p. 365; Skin Affection Lately Described as Dyshydrosis, Brit. Med. Jour., 1877, p. 799; Clinical Comments on Dyshydrosis and its Morbid Anatomy, Brit. Med. Jour., 1878, p. 749; Clinical Lecture on Dyshydrosis, Atlas of Skin Diseases, Plate li, p. 84, London, 1873.
2. Hutchinson: Notes on a Clinical Lecture Written Out in 1871, and Now Printed Verbatim, Lancet, London, 1876, p. 630.
3. Hutchinson: Cheiropompholyx, Letter to the Lancet, London, 1876, p. 307.
4. Robinson: Pompholyx, the Cheiropompholyx of Hutchinson and the Dyshydrosis of Tilbury Fox, Arch. Dermat., 1877, p. 289.

Digitized by Google

feet also were sometimes involved, he proposed the name "pompholyx" for the disorder. Thin[5] confirmed Robinson's findings, and agreed with him and with Hutchinson regarding the probable neurotic origin of the affection. Fox and Radcliffe Crocker[6] published in 1878 their first pathologic report. They found signs of inflammation in the coil-glands, and many of the earliest vesicles, which always formed in the rete, were directly in a line with and interrupted the course of a sweat duct. Later, Crocker[7] obtained some material from another patient, and examined it microscopically. In this case, he found that while a few of the vesicles were interpapillary, and had developed in the course of the coil-gland ducts, more often the cavities were superpapillary, and situated between the ducts. In no instance could he convince himself that the coil-gland was inflamed. The fact that, in his text-book, Crocker finally adopted the name "pompholyx" for the affection and classed the disease among the inflammations instead of with disorders of the coil-glands would indicate that he was far from positive regarding the correctness of his earlier deductions. Williams[8] and Santi[9] working in Unna's laboratory, both concluded, with Robinson, that the vesicles do not result from dilatation of the intraspinous portion of the coil-gland ducts. Williams studied 229 serial sections, from three typical lesions. He found that while many of the vesicles lay quite close to the sweat ducts, they did not communicate with the latter. Frequently the ducts were diminished in size, and pressed to one side, forming wide loops around the cavities, but not connecting with them in any way.

5. Thin: Remarks on a Skin Affection Lately Observed and Described as Dyshydrosis, Cheiropompholyx and Pompholyx, Brit. Med. Jour., 1877, p. 761.

6. Fox and Crocker Radcliffe: The Minute Anatomy of Dyshydrosis, Tr. Path. Soc., London, 1878, p. 264.

7. Crocker, Radcliffe: Diseases of the Skin, P. Blakiston's Son and Co., Phila., Ed. 3, 1, 291.

8. Williams: Cheiropompholyx, Monatsh. f. prakt. Dermat., 1891, p. 41.

9. Santi: Zur Frage der als Dyshydrosis, Cheiropompholyx und Pompholyx beschriebenen Hauterkrankung, Monatsh. f. prakt. Dermat., 1892, p. 93.

Digitized by Google

Breda's[10] conclusions, published at about the same time, but based on independent investigation, in Italy, were very similar to those of Williams. In particular, he emphasized the perivesicular looping of the coil-gland ducts in some of the specimens (an observation of Williams' the accuracy of which appears to have been questioned by Crocker.[7]) Paul Farey[11] who next made an exhaustive study of the disease, decided that the pathologic process did not involve the sweat apparatus in any way, but probably was due to a temporary exacerbation of a chronic vasomotor disturbance, and might be regarded as a toxiconeurodermatitis.

Despite the accumulated evidence, however, many expert clinicians still hold to the sweat-duct origin of the condition. Recently, Nestarowsky[12] working in Pawlow's laboratory in St. Petersburg, has examined a large number of sections (2,840) from six cases of pompholyx. He criticizes the work of other observers, in that he believes that their conclusions have been based on insufficient data. In his opinion, the affection is a disorder of the sweat-ducts, secondary to disturbance of the vasomotor or secretory nerves. He considers that hyperhydrosis, or the condition underlying it, is a predisposing factor. The distribution of the lesions, together with the fact that the disorder occurs most frequently (but not always) in individuals who are the subjects of hyperhydrosis is very suggestive, and Schamberg[13] states that "the clinical phenomena rather support the views of Tilbury Fox and Crocker," while Pusey,[14] a dermatologist of wide experience and admirable judgment, expresses the belief that "the disease is exactly analogous to miliaria on other parts, but present-

10. Breda: Pompholyce, Robinson, Osservazioni clinico-istologische, Riv. clin. e terap., 1891, p. 547.
11. Farey, Paul: Thèse de Paris, 1896.
12. Nestarowsky: Dyshydrosis, Dermat. Ztschr., 1906, p. 183 et seq.
13. Schamberg: Diseases of the Skin and the Eruptive Fevers, W. B. Saunders Co., Phila., 1911, p. 98.
14. Pusey: The Principles and Practice of Dermatology, Appleton & Co., New York, 1911, p. 948.

Digitized by Google

ing clinical differences on the palms and soles because of the thickened epidermis under which the sweat is retained."

It may be stated, in passing, that the very extraordinary case reported by Rasoni[15] which is sometimes referred to as an instance of "generalized pompholyx," was very probably an example of the condition recently described by Ormsby[16] under the name of "syringoma." During the past summer, it was my good fortune to see a large number of cases of pompholyx, a rather unusual experience in the Middle West. All were in private practice, and, although ambulatory, quite well under control. At various periods during June, July and August, nine more or less typical examples of the disease were selected for study. Of these patients, seven submitted to biopsy (two at their own suggestion, when they found that I was particularly interested in their condition. Each of these had two specimens removed). Lesions at various stages of development were selected for excision. All doubtful cases, presenting vesicles on the sides of the fingers only, were rejected.

### SUMMARY OF CASES STUDIED

A brief summary of the case histories is of interest:

CASE 1.—L. G., man, aged 20, single, train despatcher. Referred to me by Dr. Leon Rosenwald of this city. Hands and feet affected. Fourth attack (at intervals of one year). Plantar and palmar hyperhydrosis. Two lesions excised from left palm.

CASE 2.—A. N., woman, aged 32, married, housewife. Hands and feet affected. Numerous previous attacks at brief intervals, during past five years. The vesicles develop rapidly, and an attack usually lasts only a few days. Patient extremely nervous and excitable. Cold extremities. Plantar and palmar hyperhydrosis. One lesion excised from left palm.

CASE 3.—S. M., woman, aged 34, widow, governess. Referred to me by Dr. J. M. Frankenburger of this city. Hands affected. Second attack, the first having occurred in June, 1911. One lesion excised from left palm.

15. Rasoni: Tr. Internat. Med. Cong., London, 1881, iii, 146.
16. Ormsby: Jour. Cutan. Dis., 1910, p. 433.

Digitized by Google

CASE 4.—F. G., man, aged 38, single, clerk. Referred to me by Dr. Joseph Nutz of this city. Hands and feet affected. Palmar and plantar hyperhydrosis. Third attack (annual).

CASE 5.—H. S., man, aged 46, married, judge. Hands and feet affected. Second attack, the first having occurred in July, 1911. Two lesions excised from palm.

CASE 6.—P. K., man, aged 41, married, bookkeeper. Referred to me by Dr. Eugene Carbaugh of this city. Hands and feet affected, former severely, latter slightly. First attack.

CASE 7.—E. M., woman, aged 24, married, housewife. Referred to me by Dr. Fred Kyger of this city. Hands and feet affected. Second attack, the first having occurred in August, 1911. Lesion excised from right palm.

CASE 8.—L. I., woman, aged 29, single, stenographer. Referred to me by Dr. N. E. Lake of this city. Hands affected. Third attack, the first having occurred in May, 1910, the second in September, 1911. Hyperhydrosis of hands and feet. One lesion excised from left palm.

CASE 9.—A. R., woman, aged 34, married, housewife. Referred to me by Dr. Eugene Carbaugh of this city. Second attack, the first having occurred in August, 1910. Hands and feet affected, latter only slightly. No hyperhydrosis. Lesion excised from thenar surface of left hand.

## EXAMINATION AND TREATMENT

For anesthesia, Schleich's solution (No. 1) was employed, the preparation being injected subcutaneously, at a distance of about 1 cm. from the margin of the lesion. The bits of tissue were removed by means of a medium-sized cutaneous punch, and immediately placed in a 4 per cent. aqueous solution of formalin. One of the specimens from Case 1 was frozen, and a number of sections (eighty-four) were cut from it. The others were passed through the usual solutions, mounted in celloidin or in paraffin, and cut serially. The greater number were stained with hematoxylin-eosin, although a few Weigert and Gram-Weigert preparations were made. In all, 2,028 sections were examined. The findings corresponded in almost every respect to those of Robinson, Santi, Williams and Breda. No displaced coil-gland ducts were found, however, and no bacilli, such as have been described by Unna,[17] as occurring in

17. Unna: Histopathology of the Diseases of the Skin, Walker's Trans., Macmillan and Co., New York, 1896, p. 179.

Digitized by Google

Williams' sections, were to be seen. In only two specimens, one from Case 5 and one from Case 9, was there any visible connection between the vesicles and the ducts. In sections from these two lesions, the coil-glands and the epithelial lining of the lower portion of the ducts showed no inflammatory or degenerative changes, and there was every indication that the involvement of the sweat-apparatus was purely accidental (an occurrence which one could not consider as unusual in a region so thick in coil-gland elements as the palmar surface of the hand).

At the beginning, I must frankly acknowledge that I shared the view of Tilbury Fox and Crocker and Nestarowsky and Pusey, and, subconsciously it may be, the work was undertaken with the intention of proving the correctness of this supposition. When the first lesion was examined, however, and no evidence of a connection between the vesicles and the coil-glands or ducts was found, I was somewhat disconcerted, and determined to employ other methods of investigation in addition to the examination of serial sections. The patient (Case 1) was immediately placed on pilocarpin hydrochlorid, 0.005 gm., gradually increased to 0.02, by mouth, every four hours. At the end of forty-eight hours, the lesions showed little, if any change, although sweating had been profuse on all parts of the body during the entire time. Patients 3 and 4 received the same treatment, with similar results, or rather lack of results. Patient 2 was in the middle of an attack when first seen. She was placed on atropin sulphate, 0.0003 gm., gradually increased to 0.0006, by mouth, every four hours. The condition appeared to improve rapidly, and both the patient and I were greatly pleased. Three weeks later, however, she had another attack, and the same drug, pushed to the physiologic limit, failed to have any effect whatever on the lesions. Cases 7 and 8, similarly treated, also showed no signs of improvement, consequently it is very probable that No. 2 was just on the point of getting well

Digitized by Google

Fig. 1.—Lesions on palm at height of attack, Case 1.

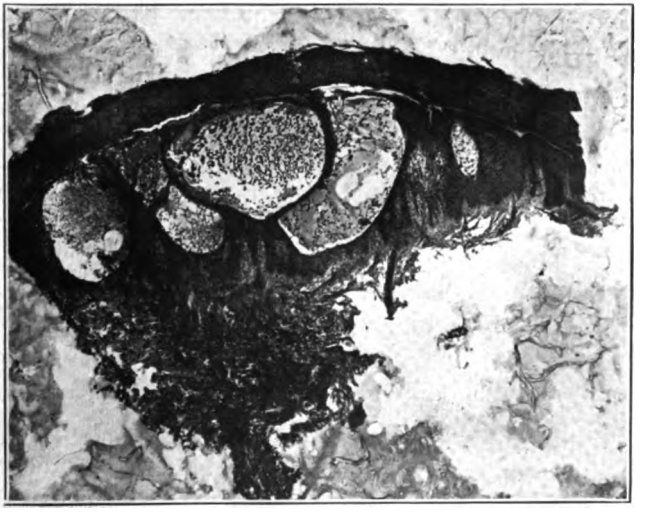

Fig. 2.—Large, multilocular lesion from palm in Case 1.

Digitized by Google

Digitized by Google

**Figs. 3 and 4.—Lesions in stage of desquamation, Case 5.**

Digitized by Google

Digitized by Google

Fig. 5.—Pompholyx lesion occurring in line of coil-gland duct. The canal was of normal caliber throughout its course.

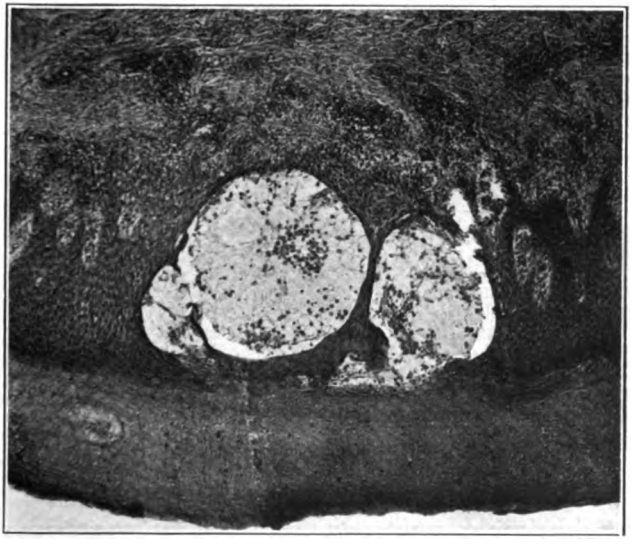

Fig. 6.—Two vesicles from palmar surface in Case 7.

Digitized by Google

Digitized by Google

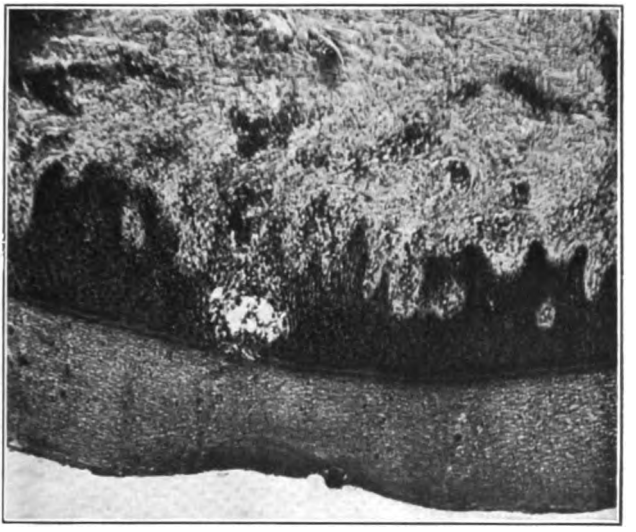

**Fig. 7.—Lesion from palm, very early stage (Spencer, 0.25 Obj., no ocular).**

Digitized by Google

Digitized by Google

when treatment was instituted. Patients 3, 4, 5, 6 and 8 were given potassium iodid, 0.6 gm. in aqueous solution, by mouth, after meals and at bed hour, for periods of from two to five days. In addition, Patients 5 and 6 each received two doses of pilocarpin, hypodermically, on the third day of the iodid medication.

At various times during the period in which iodid was administered, fluid was carefully withdrawn from several of the vesicles in each case, and tested for iodin. Under the direction of Dr. Roy Cross, of the Kansas City Testing Laboratory, this was done by placing a few drops of the fluid in a small test-tube, adding some crystals of potassium permanganate, and, after placing a bit of moist starch-paper (made from quantitative filter material) at the mouth of the tube, adding a few drops of concentrated sulphuric acid. In only one instance, the lesion being on the left palm of Patient 3, was an iodin reaction obtained. Some of the vesicles were quite large, a centimeter or more in diameter, and from 3 to 12 minims of fluid were withdrawn from each. The test is an exceedingly delicate one, and it is hardly probable that if iodin had been present it would have escaped detection. Only a few cultures were made, as the problem was undertaken from a purely histopathologic point of view. Agar, glycerin-agar and blood-serum were used as mediums. The staphylococcus (albus and aureus) was the only organism found.

## CONCLUSIONS

The pathologic changes in pompholyx are confined almost wholly to the prickle-cell layer, only a slight perivascular infiltration being present in the derma.

The coil-glands are not involved, and the ducts are implicated only by accident. At bottom, the condition is very probably a neurosis, the direct exciting cause being a toxin other than locally microbic in origin.

610 Commerce Building.

Digitized by Google

## ABSTRACT OF DISCUSSION

Dr. Joseph Zeisler, Chicago: I was particularly interested in listening to Dr. Sutton's views on the histopathology of pompholyx because the results of his work support what I have taught for many years. My associate, Dr. Simpson, will bear me out in my statement that I have always impressed on my students the neurotic character of these cases, and have held that there was no real involvement of the sweat-glands. I have always maintained that the term "dyshidrosis" was a misnomer, and I am glad that my ideas on this point have been supported. I have always held that any eruption that occurs in the form of grouped small vesicles indicates a neurotic element, and I believe that we have good reasons for looking on the pemphigus group as the result of an underlying neurosis, and the same is true of pompholyx. This eruption sometimes appears along the course of the ulnar nerve and reaches no further.

Dr. Isadore Dyer, New Orleans: Perhaps no one in this audience is more interested than I in the general proposition of pompholyx, for the reason that perhaps no one sees more cases of pompholyx than we do in New Orleans, where we number our cases by the score, and where, during the warm season, from May to October, we see anywhere from one hundred to two hundred cases. It is rather unusual to see these cases during the colder weather, and if we do see them during the winter months it is because the weather is unseasonably warm. As to the pathology of this disease, basing my opinion on clinical observation, I have held for a number of years that pompholyx is a disorder of the sweat-glands, associated with hyperhidrosis, and in that connection I would mention its frequent occurrence on the feet instead of the hands. While Dr. Sutton and others who have studied the histopathology of this disease may not agree with our observation, yet those of us who have lived in the atmosphere of this disease and have so frequently seen the evidence that it was associated with seasonal changes, still argue in favor of its relation to the sweat-glands, although this relationship has not been established.

My observation has been that pompholyx occurs with much greater frequency in males than in females—perhaps ten to one; that it rarely occurs excepting among excessive smokers, and that reduction in the quantity of tobacco consumed materially assists in controlling the disease. In addition to this, I usually reduce the amount of proteins in the diet and order strychnin, and occasionally give the high-frequency current or the Roentgen ray.

In view of what Dr. Sutton has told us I shall no longer teach that pompholyx is due to a disturbance of the sweat-glands. In many of the cases that I have seen the eruption

Digitized by Google

never reaches the stage of vesiculation. The patient may, for a period of years, show an eruption similar to that presented in some of the photographs exhibited here to-day, and without any vesiculation. The lesions may simply consist of small scaling, circular spots.

Dr. William A. Pusey, Chicago: I agree with Dr. Dyer that this disease may not have its inception in the sweat-glands, but I am not convinced that it is not a sweat eruption. My idea of pompholyx is based largely on the facts of the condition as we see it. We see it in sweating feet and to a less degree in sweating hands—not necessarily in hyperhidrosis but in the ordinary sweating during hot weather. I have seen a good many cases in Chicago, especially recurrent attacks affecting the feet, in patients who have an attack summer after summer. To my mind the situation is this: There is a maceration of the epidermis by the sweat, with the formation of sweat-cavities in the epidermis which may or may not become inflammatory. These cases may become infected by the *Staphylococcus albus*, which is always there.

The fact that Dr. Sutton does not always find his vesicles in the site of the sweat-channel, does not prove that the lesions are not due to the collection of sweat in the epidermis. The sweat-channel in the epidermis is not a closed channel; the sweat percolates between the epidermal cells and, when excessive, may collect at sites of least resistance which may not be in the line of the sweat-channel—just as water in a marsh forms pools in depressions regardless of their relation to the stream which feeds the marsh. I think you can very readily conceive of the lesion of pompholyx being produced by the sweat and only in a certain proportion of the cases occurring directly in the sweat-channel. As to the neurotic theory of pompholyx, one reason, perhaps, for my aversion to it is my objection to neurotic theories in general for skin eruptions. To my mind, the neurotic involvement is secondary rather than primary, and I believe we possess a much more rational explanation for the lesions of pompholyx in a vasomotor disturbance of toxic origin or any other rather than in a purely nervous origin. The patients I see with pompholyx belong to the ordinary run of individuals whose hands and feet sweat in hot weather. Some of them smoke, perhaps to excess; others do not smoke at all. They present other lapses from the ideal standard of personal habits—just like other mortals—to which I would attach as much or as little importance.

Dr. Frank E. Simpson, Chicago: I believe that there are two types of pompholyx, that we do not always see or describe the same type, and that in some of these cases there is a distinct neurotic element. These are probably the cases of true pompholyx. In other cases, we are dealing, not with

Digitized by Google

pompholyx, but with a condition allied to, or identical with, miliaria.

Dr. M. L. Ravitch, Louisville, Ky.: A discussion of this kind is good evidence of the fact that the text-books are not infallible. Every text-book on the subject tells us that children do not suffer from pompholyx, but in my section of the country they do. I believe Crocker was right when he said that the lesions were due rather to hyperhidrosis, than to dyshidrosis, and so on, and in all the cases which I have seen there was a neurotic element present. I am also inclined to believe that the use of tobacco in the shape of excessive smoking or chewing has some etiologic bearing on it.

A year ago Dr. Dyer advised the use of salicylic acid and strychnin in the treatment of pompholyx. I have tried this treatment with very good results, and I have also found that these patients often recovered with a change of climate. Some authorities, among them Unna, assert that the eruption has a bacterial origin. In some of these lesions we find the staphylococcus, but I regard that as an incidental occurrence.

Dr. K. A. Zurawski, Chicago: I think that the histologic features of pompholyx as described by Dr. Sutton may be considered as final, and that the various theories that have been advanced in the discussion as having an etiologic bearing on the disease are not incompatible with the histopathologic picture he has advanced. We know that in pompholyx we have an accumulation of fluid in a certain slow-forming cavity. The question arises whether or not this is due to a neurotic element. There is no reason why a local or general neurosis should not alter a secretion to such an extent that it will become less diffusible and will result in the local accumulation of such a secretion. Likewise, the theories advanced by Dr. Dyer that the disease is almost invariably met in heavy smokers and is very common in warm climates are not at variance with the histopathologic picture of Dr. Sutton, which I believe is practically conclusive. It now only remains for us to investigate pompholyx from the point of view of the chemistry of this particular secretion, through which we may reach the final solution of the etiology of pompholyx and perhaps of many other of the vesicular eruptions. We may learn that it is due to some organism which produces some chemical change in the secretion, or that perhaps this alteration is the result of a nervous disturbance. This problem still remains for us to solve, but whatever its solution, I do not think that it will alter the histopathologic findings of Dr. Sutton.

Dr. Everett S. Lain, Oklahoma, Okla.: I wish simply to say a few words touching on the treatment of pompholyx. About three years ago a patient was referred to me who suffered from recurrent attacks of pompholyx. One day

Digitized by Google

when I was out of the city my assistant, unintentionally, gave the patient a massive dose of the Roentgen ray, somewhat similar to the treatment described by Dr. MacKee. The immediate result of the treatment was rather severe, but the patient has been free from attacks of pompholyx since.

Dr. Joseph Zeisler, Chicago: I am afraid that not all of us who have taken part in this discussion have had the same affection in mind. Sweating feet, for example, I do not regard as pompholyx, although hyperhidrosis of the feet may be complicated by blisters. I saw many such cases during my service in the army, but I do not class those cases as pompholyx, nor do I call the formation of small vesicles occurring on the hands as the result of summer heat pompholyx. Dr. Sutton's paper referred to pompholyx proper and not to something else.

Dr. Richard L. Sutton, Kansas City, Mo.: I do not think that Dr. Dyer and I are so far apart clinically, after all. The fact that the majority of his cases occur in tobacco-users, the frequency of the disease in midsummer, and the line of treatment suggested by him all serve to bear out this contention. Nervous breakdowns occur oftener during the hot months than at any other time; excessive smokers of tobacco are usually neurotic individuals, and but few therapeutists have found strychnin beneficial in the treatment of the known disorders of the coil-glands. In New Orleans the majority of the women go north for the summer; hence the preponderance of male patients is readily explained.

Dr. Pusey's assertion that practically all sufferers from pompholyx are also afflicted with hyperhidrosis may hold good in his clientele; it does not in mine. Fully one-third of my pompholyx patients had never been troubled with disturbances of the sweat-glands of the hands or feet at all prior to the date of consultation. The chemical characteristics of the vesicle contents were so thoroughly investigated by Robinson (whose findings have been confirmed by the vast majority of later observers), that I considered the matter closed. In a measure, I agree with Dr. Simpson: all medical men are subject to errors of judgment when it comes to questions of diagnosis, and I have found the majority of dermatologists exceedingly human, after all. I am afraid that Dr. Ravitch misquotes the late Professor Crocker. If Dr. Ravitch will carefully read the reference cited, I am sure that all his doubts regarding the matter (in so far as Radcliffe Crocker's conclusions are concerned) will speedily vanish. Change of climate, particularly if a cooler temperature is selected, undoubtedly benefits many cases of pompholyx, just as it does other neurotic disorders, but one of the worst cases of plantar hyperhidrosis I have ever seen occurred in a professional iceman. If Dr. Zurawski's suggestion regarding the

Digitized by Google

"everglade" character of the superglandular epidermis were true, the iodid solution should penetrate the "marshy" tracts as readily as does the fluid in which it is dissolved, and the contents of every vesicle should show traces of the drug. Inasmuch as only one of them did, I am forced to acknowledge that I believe that the contamination was accidental and not pathognomonic.

Digitized by Google

# CUTANEOUS AFFECTIONS OF CHILDHOOD

ALFRED SCHALEK, M.D.
Professor of Dermatology, University of Nebraska; Member of the American Dermatological Association
OMAHA

The cutaneous affections of childhood, while only a part of the whole field of dermatology, and while of the same pathologic character as in adults, are still sufficiently different in their etiology, symptomatology and therapeutics to deserve a more individual consideration than they are given. Whatever notice is taken of them now in the dermatologic text-books is limited and widely scattered and for their connected study the reader might almost find more information in the treatises on pediatrics.

The subject is too large to be covered thoroughly and systematically in a short paper. For this reason only a few points appertaining directly to cutaneous affections of childhood will be taken up in a general way and promiscuously.

Skin diseases, especially of the acute type, occur proportionately more frequently in children than in adults. The reason for this is not far to seek. Local and general conditions combine to reduce the normal resistance of the skin and to increase its susceptibility to pathologic changes. Exposures to injurious external agencies of mechanical, chemical and microbic nature are more common at this age. Lack of proper hygiene influences the condition of the skin considerably. Keeping the skin clean and soft is the best prophylaxis against trouble, but unfortunately there are wrong conceptions about this matter even among intelligent people. Harmful

Digitized by Google

extremes are seen right along. There is no need of speaking of the fact that quite a number of eruptions are directly due to dirt. This acts on the skin mechanically and chemically, producing dermatitis and eczema and, by harboring pus cocci, inducing secondary infections such as impetigo and furunculosis. On the other hand, the modern tendency to carry the use of water too far also does a great deal of mischief. Hebra, the Nestor of dermatology, used to say that he observed more skin troubles in people who were overactive bathers than in those who were too sparing with their ablutions. The too frequent washing of the skin removes the natural lubrication without giving the fat-producing glands a chance to accomplish their duties. The skin grows dry and irritable, especially when an inherited tendency in that direction is present, and easily becomes a prey to skin diseases. The matter of soaps is quite important in this connection. Inquiries about them will often clear up the obscure cause of some obstinate skin trouble. Only the purest and mildest soaps should be employed for the skin of children, which is very tender and sensitive. There is no call for admixtures of chemicals or drugs in them. If these are needed, they can be applied more properly and accurately in other ways. This question may seem too trifling for much attention, but its consideration is attributable to the fact that people who are not instructed in this direction accept the claims of "patent-medicine" firms about their soaps, the purity and composition of which are unknown quantities and the usefulness questionable. At times the infantile skin does not tolerate water and soap at all. Trying to remove the scales and crusts with still more scrubbing is responsible for a vicious circle resulting in severe and apparently incurable skin eruptions.

A great factor in the prevalence of skin diseases in older children is the public school. Childhood is the only age at which a great number of persons come into promiscuous and intimate contact during the greatest

Digitized by Google

part of the time. It would be interesting and instructive to learn the percentage of skin diseases originating in the schoolroom. Disseminated here are syphilis, tuberculosis, scabies, trichophytosis, impetigo, the acute infectious exanthems and others. Is this not sufficient reason that wherever medical inspection of schools is obligatory — and this should be insisted on in every school — the examining physician should have more than a smattering knowledge of dermatology?

The instability of metabolism and elimination in childhood are frequently contributing factors toward cutaneous affections. Their direct connection with urticaria is well known. The association of indigestion of fat and sugar with acute inflammatory eczemas has recently been pointed out by Towle and Talbot. Whether we believe skin eruptions to be purely local or not, the regulation of gastro-intestinal functions is always an important item of our therapeutics. Most of the breast-fed infants affected with eczema suffer from some dietary mistake. No general rules can be laid down for its correction and each individual case needs its own study and consideration. The feeding may be insufficient, excessive or irregular. If insufficient, the fault may be that the mother's milk is lacking in the necessary percentage of proteins and fat. This is especially the case with anemic women, an increase of sugar being present often in the milk to the detriment of the other solid constituents. More often it will be found, however, that the mother's milk is too rich and that the child is fed too often. Even under normal conditions the fat is not absorbed entirely and the normal feces contain about 10 per cent. of it. In abnormal cases the percentage of undigested fat may rise to 75 per cent. Infants' food should also contain a sufficient amount of water to increase the secretion of pepsin and hydrochloric acid and to assist the digestion. This is frequently neglected in breast-feeding. Constipation and diarrhea can often be traced to faulty feeding and retard the recovery from

Digitized by Google

skin diseases. If the necessity arises, weaning must be resorted to and every means should be taken to find an artificial food of the right proportions. It must be remembered that the appearance of the child is often deceiving and that even if it appears stout and of the right weight signs of anemia may be in evidence and an examination will show the blood below par. Irregular and too frequent feeding is another frequent cause of digestive disturbances and requires regulation of the intervals between feeding and an early elimination of night feeding.

The diet of older children also needs careful supervision. The mistake of allowing them to partake indiscriminately of whatever food is served to adults is commonly made. When it is considered how often they are fed on sausage, cheese, pickles, sweets and other indigestible food up to the limit, it seems remarkable that no more harm is done. The control over the eating is still more important when the children are affected with skin diseases, and at times a plain milk diet becomes imperative.

Disturbances of the nervous system have more to do with causing skin diseases than is generally appreciated. The connection of dentition and eczema is probably due to such a cause. Rest and sleep are essential for the cure of acute skin diseases in children. Too much handling and petting of the sick child makes it irritable and restless and interferes with the efficiency of the treatment. It is a common experience to see children recover in a hospital under the same treatment which, applied by the mother at home, has proved a failure.

Not all these details may seem pertinent to dermatology, but their consideration is at least as necessary as the local applications and, unless the dermatologist becomes familiar with them, it would be better for him to leave the care of these cases to the pediatrician.

The nomenclature of skin diseases of children is just as unsatisfactory as in adults. Such names as pemphi-

Digitized by Google

gus neonatorum, lichen urticatus, hydroa, scrofuloderma, etc., do not convey any meaning as to the pathology, symptomatology or etiology, often presume a classification which is doubtful, and are of no practical value. Until the time comes when all controversies regarding the nature of the different skin diseases are settled and the pathologic conditions are of avail for names and classification, their consideration on some practical basis would seem advantageous. For the reason that prevention and cure often depend on the knowledge of the cause, Adamson groups the skin diseases of children according to the etiology. He divides them into (1) congenital affections, (2) affections due to physical causes, (3) affections due to local parasitic action, (4) affections due to toxemias and general microbic infections, (5) affections of nervous origin and (6) affections of unknown origin.

In addition to the etiology another feature might be utilized. Many skin affections of childhood appear at certain periods either exclusively or by predilection. The reasons for this are known in some cases, while in others no satisfactory explanation has been brought forward. For example, the fact that the *Microsporon adouini* attacks the hair of children only is stated in every textbook, but Croker only, to my knowledge, attempts to explain it. He thinks that the greater resistance of the hair of adults prevents the invasion and penetration of the fungus into the hairshaft, but confesses that so long as the hair of the adult is no barrier against the *Megalosporon ectothrix* the age alone cannot be held responsible. Neither do we know why such diseases as prurigo, urticaria pigmentosa, etc., should occur in children only By combining the usual period of occurrence of the skin diseases with their etiology whenever known, however, a grouping may be made incorporating exclusive characteristics of this age.

Such a classification would cover in a general way four groups: (1) congenital affections, like nevi, ichthy-

Digitized by Google

osis, syphilis, etc.; (2) affections occurring during infancy and childhood only, such as pemphigus neonatorum, urticaria pigmentosa, lichen urticatus, prurigo, xeroderma pigmentosum (the etiology of most of these is unknown); (3) affections predominating during childhood, among which belong impetigo contagiosa, miliaria, intertrigo and the acute exanthematous eruptions, which are due to the higher susceptibility and the lower resistance of the skin of children which permits the injurious action of micro-organisms and irritants; (4) all other affections which occur likewise in adults and are due to the same agencies. This classification is offered as a suggestion only and serves its purpose if it causes other efforts in the same direction.

Another feature which distinguishes the cutaneous affections of children is their deviation in symptomatology from that of adults. The lesions differ both in degree and in type. They assume a more acute and inflammatory character. Certain lesions like the erythematous, vesicular, pustular and bullous predominate over the papular, squamous and infiltrated. Furthermore, what would be called atypical in adults is frequently characteristic in children. Lesions of scabies occur not only in the usual locations, as the hands, feet, wrists, etc., but also on the head and the face. The wheals of urticaria, usually blanched in adults at first, from the compression of the capillaries, are often red from the beginning to the end in children. Impetigo assumes a great variety of clinical aspects and may simulate eczema, pemphigus and other affections. The bullous syphiloderm is seen almost exclusively in infants. The reasons for these changes must be looked for in the higher vascular irritability and the lower vitality of the epithelium. To one who has not given a special study to the skin diseases of children a diagnosis may become extremely difficult at times. The rule observed in adults, to depend for the diagnosis on some characteristic primary lesion, does not always hold good in children. It

Digitized by Google

will be necessary to consider not only the existing cutaneous manifestations and the general symptoms, but also to study closely the developments and changes due to the peculiarities of childhood.

In regard to the therapeutics of cutaneous affections of childhood two general rules might be laid down:

The first is the correction of any causative or aggravating complication. This point has already been partly referred to. A few words may be added in regard to the internal administration of drugs. It is better to do too little in this direction than too much. There are only a very few drugs which have any direct action on the skin. Those used for adults, such as arsenic, mercury, iodids, etc., must be used with great caution, partly on account of their general effects, partly because the child's skin is much more liable to drug dermatitis, which might complicate or disguise the original trouble. The drugs usually needed are simple and indicated by the internal complications. An occasional purge with calomel or some other laxative, some iron tonic, and possibly a diuretic is usually all that is necessary. Antipyretics and opiates should be avoided as much as possible. The second general rule applies to the local management. It should be rather conservative than aggressive. The natural tendency of the skin is to recover to a normal condition if given a chance. Protection of the diseased skin is of the utmost importance. This means avoidance of irritations of whatever nature, exposure to air, water, heat or cold, scratching, the action of physiologic and pathologic secretions, from old and dried-up applications, etc. The number of the local applications which are necessary is limited. The tender skin of children does not tolerate and does not need any strong and stimulating action. The efficiency of the treatment does not depend so much on the knowledge of a great many different remedies as on the skill to recognize the indications and the proper method of application.

**Brandeis Theater Building.**

Digitized by Google

## ABSTRACT OF DISCUSSION

Dr. William A. Pusey, Chicago: Some time ago I had an experience in the dietetics of childhood which interested and amused me not a little. I had been to see a child with a very severe infantile eczema. Several pediatrists of national reputation had already been consulted, and everything that expert knowledge could suggest had been done to put the child on a scientific diet, even to the extent of procuring a flock of goats to furnish the milk. On my way home, after seeing this patient, I met a woman carrying her 9-months-old infant. They were evidently poor, but the child had a remarkably smooth skin, was the very picture of health and was busily engaged in sucking at a green onion. I could not but contrast the condition of the two infants and think of how little we knew about dietetic disturbances. I do not mention this to advise green onions for babies or to disparage efforts at proper feeding, but to indicate how important the personal equation is in these cases. Aside from this, I thoroughly agree that intestinal disturbances are the basis of most cases of infantile eczema, and that in the treatment of these cases, careful regulation of the diet is very essential.

Dr. David Lieberthal, Chicago: To the cutaneous affections of childhood, which at times offer great difficulties, belongs infantile eczema. That this is caused directly by gastro-intestinal disturbances I do not believe. Seborrhea of the scalp, however, is of great importance, since it is a remnant of the vernix caseosa which if it does not disappear in due course, becomes the basis for the development of eczema. After this has been established, it will be aggravated and maintained by any alteration of the normal functions, especially those of the gastro-intestinal tract, which are frequently due to faulty feeding. Thus proper measures in this direction, as well as the correction of other abnormal conditions, will exert a beneficial influence on the course of the eczematous manifestations, although the latter will not disappear without local treatment. Many cases of infantile eczema would be prevented if the infant's scalp were regularly examined for seborrhea and the same properly treated. I believe that cases of infantile eczema could be managed with greater facility in a well-equipped hospital than in the home.

Dr. Burnside Foster, St. Paul: I do not know whether onions are good for infantile eczema or not, but I believe that a change in the diet is followed by good results, at least in some cases. This does not mean that a similar diet is indicated in all these cases; one infant may thrive on onions while another may be poisoned by the mere smell of them. We may see two or three children in the same family, fed on the same diet, and while one will be subject to eczema the others will be entirely well. The personal equation is a very important factor and we do not know much about it.

Digitized by Google

According to my experience, however, I have found that a radical change in the diet of these patients will many times prove beneficial.

Dr. Everett S. Lain, Oklahoma, Okla.: Of all the stubborn and discouraging conditions I have had to treat, infantile eczema is the chief. I am inclined, however, to agree with Drs. Pusey and Foster in their remarks about the diet—at least, in a measure. I do not recall ever having seen a severe case of infantile eczema among the Indians. In fact, eczema is not at all common among them, as my statistics show. When we come to the subject of the regulation of the diet of these patients, I am inclined to say, "What is the use?" I have seen an Indian baby, covered with secretions, excretions and filth, which are allowed to remain on the skin until they are accidentally removed, feeding, perhaps, from a filthy breast or from a filthier bottle and surrounded with flies, and, still many of these babies are apparently fat and healthy.

Dr. M. L. Ravitch, Louisville: The discussion thus far has shown how little we know about eczema in children. It also shows how little we know about the chemistry of the drugs we prescribe. I have long regarded overfeeding as an important factor in the etiology of infantile eczema. To my mind, increased irritability of the skin is due to the change in mineral metabolism, causing alteration of the chemism of the skin. Scientific observations coincide with empirical facts that nutrition and diet are important factors in treating infantile eczemas.

Dr. K. A. Zurawski, Chicago: I think one mistake we make in the treatment of these cases is that we do not discriminate, but treat all these children along similar lines. We treat the thin, wiry baby and the fat, flabby one, the robust brunette baby and the delicate blonde, all in the same way. We give them the same food; we administer the same remedies. We treat an Indian baby in the same way as we do a little Swede. We must generalize a little less and use more common, ordinary horse-sense; then we shall have better results. I have found that certain types of infantile eczema require more proteins while others require more carbohydrates, and if I treat my patients according to the indications, I find that they quickly get well.

Dr. Alfred Schalek, Omaha: The discussion was practically confined to infantile eczema, which was only a small part of my paper. I do not know anything more about the etiology of eczema than the rest of you, but the point I wish to emphasize is that any faulty gastro-intestinal function will aggravate the eczema and is apt to interfere with the beneficial effect of local treatment. It is important that the dermatologist should know something about the proper feeding of infants, as he is not always in a position to call on the various specialists for aid.

Digitized by Google

# SKIN COMPLICATIONS OF DIABETES

BURNSIDE FOSTER, M.D.
ST. PAUL, MINN.

A person suffering from diabetes may of course become afflicted with any form of skin disease, but there are a number of dermatoses which have long been recognized as being directly caused by diabetes, and which improve or grow worse as the amount of sugar in the urine diminishes or increases. There have occurred in my practice many cases in which the diabetic condition of the patient was first recognized as the result of a physical examination, brought about through a consultation for the purpose of obtaining relief from the skin disease. I have thought, therefore, that a brief discussion of the subject, commonplace though it may be, might be interesting and perhaps instructive.

My experience has taught me that many general practitioners fail to appreciate the close relationship that exists between diabetes and many skin affections, and that unless the classic symptoms of the former are present they do not look for sugar when consulted, for instance, concerning an obstinate pruritus, a dermatitis or furunculosis. Consequently, I have made the diagnosis of diabetes a good many times in patients who had been referred to me by capable physicians of experience. Most dermatologists have had this occur in practice.

Many cases of diabetes have existed for a long time without symptoms, and sometimes the earliest symptoms are those appearing on the skin.

Digitized by Google

*Dryness of the Skin.*—A very common symptom of diabetes is a general dryness and harshness of the skin and mucous membranes, probably due, I suppose, to the hygroscopic nature of the sugar circulating in the blood, which draws water from the tissues through which it passes and leaves them abnormally dry. An annoying and sometimes very intense pruritus results. I have notes of eight patients in whom this symptom alone led to the discovery of sugar in the urine which had not been noticed before. Local treatment is of little avail in this condition, which promptly disappears when the proper treatment for diabetes is instituted. A marked anhidrosis is usually present and there is often a general desquamation of the skin; sometimes, as in one of my patients, so extensive as to resemble the appearance of exfoliative dermatitis. The opposite condition of hyperhidrosis has been reported as associated with diabetes, but this I have never seen and am inclined to think it must be simply a coincidence. Dryness and thinning of the hair quite commonly accompanies this general xeroderma and atrophy of the nails is sometimes seen.

*Furuncles and Carbuncles.*—Probably the commonest affection of the skin complicating diabetes is furunculosis and carbuncle. The furuncles may occur on any part of the body and are more deep-seated and indurated than the ordinary furuncle and not infrequently become gangrenous. In my experience they have been less painful than the ordinary furuncle, but the slough has been deeper and their course is very slow. Sometimes they appear in the form of an acne on the face. I have in mind one patient, a physician, who acquired syphilis some years ago and who has lately developed diabetes. He has a most obstinate, deep-seated, indurated pustular acne, which is rebellious to all local treatment, but which improves whenever he adopts a rigorous antidiabetic diet, and recurs again when he returns to an abundant carbohydrate diet and begins to excrete sugar

Digitized by Google

in his urine. Carbuncles and deep-seated phlegmons are much less common than furunculosis and are usually seen in the more advanced stages of the disease. In the cases I have seen, they have always been accompanied by extreme prostration and have nearly always been the cause of the death of the patient. A deep-seated carbuncle in a diabetic patient is an extremely dangerous complication.

*Dermatitis.*—The general surface of the skin of diabetics is peculiarly prone to take on erythematous and eczematous conditions, frequently due, no doubt, to the irritation produced by scratching to relieve the intense pruritus so often present in this disease. The genital eczema, or, as it is more properly designated, dermatitis, of both sexes, which, next to furunculosis, is the commonest skin affection in diabetes, is usually ascribed to the irritation of the sugar-laden urine which comes into contact with the external genitals. I believe that this explanation is correct, because I have just now under observation two women who came to me, one two years and one about a year ago, with most extensive inflammation of the external genitals, and in both of whom diabetes was first discovered as the result of that condition. Under careful diet and general treatment the sugar was greatly diminished in amount in both of them and the skin promptly returned to a normal state. I gave them each careful instruction to avoid wetting the skin with urine and ordered stearate of zinc to be applied liberally to the parts just before each urination. At the present time both of these patients are passing a varying amount of sugar constantly, but are able to keep the skin from becoming inflamed by taking the above-mentioned precautions. A similar dermatitis occurs in men suffering from diabetes and is usually limited to the glans penis and prepuce, but sometimes spreads to the skin of the penis, the scrotum and adjacent parts. Local treatment of this condition is of little

Digitized by Google

avail, but it improves rapidly when the proper treatment for diabetes is instituted. The abundant sugar-laden exudation, always present on these inflamed areas, furnishes an excellent culture medium for the saccharomyces and other fungi which grow profusely and increase the inflammation. The itching is intense and the constant scratching may produce deep ulceration which sometimes brings about extensive sloughing and even gangrene. Numerous cases have been reported in which small ulcerations about the genitals, in diabetics, have been mistaken for venereal sores and treated as such for some time before their exact nature was made manifest; one such instance has recently occurred in my practice.

*Gangrene.*—The tendency of diabetics to gangrene of the skin has long been recognized and since this complication usually occurs in old and feeble patients, whose diabetes is of long duration, it is apt to be a very serious and often a fatal complication. Gangrene may be either dry, resembling the ordinary senile gangrene, or moist, preceded by the formation of bullae of the skin. It may occur on any part of the body, but is commonest on the extremities, particularly in old persons who already suffer from arteriosclerosis. Surgery offers the only hope when gangrene occurs and since these patients do not bear surgery well, the outlook in such cases is very dark.

*Malum Perforans.*—Sample and Gorham[1] report in detail seven cases of this complication of diabetes and cite the literature as collected by various other observers, showing that it occurs in about 3 per cent. of the cases reported. In nearly every case the patient was past 40, and it has been found with much greater frequency in males than in females. In practically all of the cases the glycosuria has been of a mild type. The initial lesion is usually in the form of a small vesicle, later

1. Sample and Gorham: Johns Hopkins Bulletin, January, 1913.

Digitized by Google

developing into an ulcer, the metatarsal phalangeal joint being the favorite seat of the lesion. Many patients recover unless gangrene supervenes. I have seen but one instance of this complication.

The above-mentioned are the commonest skin affections that complicate diabetes and are practically the only ones with which I have had much personal experience. Psoriasis has been frequently reported as occurring in the course of diabetes, and I have seen one such case, but I cannot believe it to be more than a coincidence. Other skin complications of diabetes, such as xanthoma diabeticorum, urticaria, dermatitis herpetiformis, herpes zoster and purpura are all rare, and I have had but little experience with them.

I have frequently wondered whether or not sugar is excreted in the sweat of diabetics and, if so, whether its presence on the skin would not account for some of the inflammatory diseases which occur in the course of this disease. I have not been able to find any literature on this subject and hope that some member of the Section can enlighten me.

*Importance of Skin Symptoms of Diabetes.*—I have called attention to this general subject thus briefly in the hope that the discussion will emphasize the fact that the first symptom of diabetes may be some affection of the skin, a fact which seems to me not sufficiently recognized by the general practitioner. The early recognition of diabetes is of the greatest importance to the patient because, while the ultimate prognosis of the disease is probably always bad, there are few of the serious diseases of life which are more amenable to intelligent treatment. Diabetics in whom the disease has been recognized in its early stages may live for many years, and enjoy a comfortable life, if they are willing to submit, as most of them are, to the proper hygienic and dietary regimen.

821 Lowry Building.

Digitized by Google

## ABSTRACT OF DISCUSSION

DR. JOHN M. ARMSTRONG, St. Paul: I have seen several cases in which workers in sugar developed a dermatitis of the skin which disappeared when they gave up their occupation, only to recur when they returned to handling sugar.

DR. ERNEST D. CHIPMAN, San Francisco: Dr. Foster's very interesting paper suggests a thought which we, as dermatologists, should constantly bear in mind; namely, that in our observation of skin lesions we are many times in a position to detect serious constitutional disorders. Diabetes is a case in point, and it is only one of a number of constitutional disorders the presence of which should at least be suspected and investigated in connection with certain cutaneous manifestations.

DR. M. L. HEIDINGSFELD, Cincinnati: I wish to say a few words on the importance of careful general examination in some of these cases. Only a few days ago a patient presented himself for a perforating ulcer of the foot. These cases, as is well known, commonly owe their presence to syphilis or glycosuria. In this instance, the patient's urine was heavily loaded with sugar, and the Wassermann was negative. It has been my custom invariably to make a Wassermann examination in all cases of glycosuria, and it is surprising to note the large percentage of patients with glycosuria who show a strong positive Wassermann. Antisyphilitic treatment, in these cases, particularly the intravenous administration of salvarsan or neosalvarsan, clears up promptly as a rule, not only the complicating skin affections which Dr. Foster has mentioned, but also the glycosuria.

DR. K. A. ZURAWSKI, Chicago: The recognition of certain lesions of the skin which are due to diabetes is very important, especially in those cases in which sugar is absent in the urine. We know that there are many cases of diabetes in which for a certain length of time there is no sugar in the urine, and yet there is a change in the metabolism of the sugars. Especially is this true in some of those abnormal cases in which the diabetes is due, not to an extreme ingestion of carbohydrates, but to a vicious tendency to transform the nitrogenous substances into carbohydrates. This is due to a faulty metabolism of the nitrogenous substances. It is a proved fact that nitrogenous substances are much more frequently broken up into carbohydrates than we have hitherto been led to believe.

DR. H. E. MENAGE, New Orleans: This discussion seems to open up an avenue which should broaden a little bit more. A few years ago Dr. Matas and I saw a woman with a carbuncle, which was operated on. Sugar developed after the operation, and the patient died. This suggested to us that in cases in which we have reason to suspect sugar and find

Digitized by Google

none the urine should be examined for diacetic acid and the acetone bodies. Another point brought out was in regard to the relief of pruritus, particularly when localized about the genitals, by protecting the parts with stearate of zinc. I am convinced that the irritation is due to the contact of the diabetic urine with the skin and I found that by freely anointing the skin with petrolatum before urinating the pruritus is practically relieved and that this method of treatment is superior to zinc stearate or dusting powders.

Dr. Everett S. Lain, Oklahoma City: I have been very much interested in this paper, which is on a subject that should come up for discussion more frequently. We as dermatologists are too often prone to overlook internal conditions in the treatment of the skin. Recently I saw a case in which this fact was clearly shown. The patient was a woman who was on her way to Chicago to see a dermatologist, and her family physician advised her to go by way of Oklahoma City, where I saw her and noticed the peculiarity of the skin mentioned by Dr. Foster. Diabetes was suggested, but previous examinations of the urine had failed to detect the presence of sugar. The skin manifestations consisted of an extensive eczema, with marked pigmentation, somewhat similar to the condition met with in pellagra. Subsequently, sugar was found in the urine, and a radiograph showed both gastroptosis and enteroptosis. She was referred back to her family physician, who reported improvement and eventually apparent recovery.

Dr. Burnside Foster, St. Paul: I regret that no one has attempted to answer the question which I asked in regard to the possible presence of sugar in the sweat of diabetics. That might possibly explain some of the skin phenomena. As Dr. Armstrong stated sugar is known to produce inflammation of the skin when applied externally, as is shown by the so-called "grocer's itch"—a dermatitis produced by the handling of sugar.

Digitized by Google

# PRIMARY SARCOMA OF THE LOWER LIP

A. J. MARKLEY, M.D.
DENVER

Considering the frequency of sarcoma about other parts of the face and the various structures of the mouth and jaws, it is rather remarkable that this form of malignancy should so rarely occur primarily on the lower lip.

There seems to be no reason why sarcoma should not grow here as well as in any other such structure, and it may of course secondarily involve the lip after arising in neighboring parts; yet with the single exception of Duplay and Reclus' "Surgery" of the edition of 1898 text-books make no mention of primary sarcoma of the lower lip, and a search of the literature reveals reports of very few cases.

Coley[1] reports a case of round-cell sarcoma of the lower lip in a girl aged 5 which recurred locally twice after operation and was then treated with mixed toxins with apparently complete cure.

Maunsell[2] reports a case of sarcoma of the lower lip in a woman aged 34 of five months' duration successfully removed. The clinical description of this case and the microscopic findings would suggest, however, rather a granuloma pyogenicum than a sarcoma, a mistake which might readily be made by one not familiar with that condition.

Langston[3] reports a case of large round-cell sarcoma of the lower lip in a middle-aged woman with certain congenital defects about the mouth which seem to indicate that the case was one of extensive lymphangioma

1. Coley, W. B.: Recurrent Round-Cell Sarcoma of the Lip, Post-Graduate, May, 1897.
2. Maunsell, R. C. B.: Primary Sarcoma of the Lip, Tr. Roy. Acad. Med., Ireland, 1900.
3. Langston, O.: Primary Sarcoma of the Lip, Indian Med. Gaz., July, 1909.

Digitized by Google

which later became in part sarcomatous, a not infrequent occurrence.

Dr. William H. Welch, who confirmed the diagnosis of the case herein reported, says regarding it "Hemangiomas, and less frequently lymphangiomas, with sometimes sarcomatous structure, are well-recognized neoplasms of the lower lip; but pure round-cell sarcoma of the type here represented and without lymphangiectases is in my opinion very rare."

While no considerable importance is to be attached to this condition, I believe that its rarity should give to it sufficient interest to justify the report of the following additional case, for the opportunity of doing which I am indebted to Dr. J. R. Hopkins of this city, who performed the operations and kindly turned over to me the specimens.

Mr. B., aged 65, came under observation in May, 1912, for an opinion as to the character of a lesion of the lower lip which was first noticed about six months previously as a small lump on the vermilion border which soon became irritated and broke down, probably from mechanical insult. Examination disclosed a flat ulceration occupying the middle third of the vermilion border, in the center of which was a projecting mass about the size of a large pea. The edges of the ulcer were neither elevated nor indurated, and showed practically a normal epithelial covering without thickening; on palpation the growth was felt to lie deeply within the body of the lip, being as apparent on the mucous as on the skin surface with definite protrusion on each surface. A group of nodules was felt in the submental region.

Although the superficial evidences of epithelioma were absent, the age of the patient, the location of the lesion and the presence of enlarged lymph-nodes in the submental region led to a diagnosis of epithelioma, and a radical operation was urged. Microscopic examination revealed not the expected epithelioma, however, but a small round-cell sarcoma. Neither the skin nor the mucosa was involved except as a result of ulceration. The projecting mass was composed only of blood and detritus. The growth occupied the body of the lip, infiltrating the muscular and fibrous structures as shown in Figures 1 to 4.

About six months after operation a nodule appeared at the anterior border of the sternomastoid muscle on the left side and was promptly removed, but unfortunately was lost without examination. Up to the present there has been no other recurrence.

Digitized by Google

Fig. 1

Fig. 2

Fig. 1.—Relation of growth to structures of lip × 2.
Fig. 2.—Border of growth, showing infiltration of muscle. Zeiss obj. aa, oc. 3.

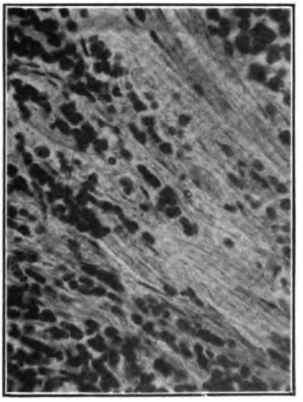

Fig. 3

Fig. 4

Fig. 3.—Border of growth, showing infiltration of muscle fascia. Zeiss obj. DD, oc. 1.
Fig. 4.—Sarcomatous infiltration of muscle. Zeiss obj. DD, oc. 1.

Digitized by Google

Digitized by Google

On clinical evidence alone it would be extremely difficult if not impossible to make a diagnosis in such a case. A number of widely differing pathologic conditions might present such a picture, and accuracy of diagnosis in this location is of much importance, as a mistake may lead to an unnecessary mutilating operation or, on the other hand, to wholly inadequate treatment.

Darier[4] has emphasized this point in reporting a case of lymphosarcoma of the lower lip in which the clinical appearances all indicated epithelioma. Because of the frequency of epithelioma in this situation its presence will usually be assumed in cases presenting the aspects of malignancy unless appeal be made to the microscope, and since the rapid growth and tendency to wide-spread metastasis in sarcoma render early diagnosis even more important than in carcinoma, this appeal should be prompt, a biopsy being made in all such cases when the clinical manifestations are not so clear as to be unmistakable.

The involvement of the anatomically related lymph-nodes is generally regarded as definitely indicating carcinomatous disease; but Adami[5] shows that metastatic deposits in sarcoma also "may occur along the lymphatics so that malignant enlargement of superficial and other lymph-glands is not absolutely diagnostic of cancer. Borst ascribes this liability to lymphatic extension, especially to small round-cell sarcomas."

Malignant growths of the lower lip ordinarily possess such features as to place them in the domain of general surgery rather than of dermatology, yet dermatologists are keenly interested in all disease processes which involve the superficial tissues and are frequently obliged to pass judgment on those affecting the lips, among which primary sarcoma, even though it be rare, should be given consideration as a possibility.

432 Metropolitan Building.

4. Darier, J.: Lymphosarcoma, Ann. de dermat. et de syph., 1911, Series 5, ii, 226.
5. Adami: Principles of Pathology, i, 701.

Digitized by Google

# AN ANOMALOUS CASE OF WHITE-SPOT DISEASE

H. H. HAZEN, M.D.
Professor of Dermatology, Georgetown University, School of Medicine; Clinical Professor of Dermatology, Howard University, School of Medicine
WASHINGTON, D. C.

The following case is so interesting, both clinically and histologically, that it seems worthy of being reported in detail, especially as it may help to throw some light on the rather obscure relationship existing between certain cases of morphea guttata and lichen planus atrophicus et sclerosus.

*History.*—May 13, 1912, Dr. J. J. Richardson of Washington referred to me a white woman aged 32, who complained of some spots on her neck. The past and family histories were unimportant save that the patient had lived in Porto Rico, under the most favorable circumstances, for the past ten years. In spite of the most careful questioning no trace of syphilis could be elicited. Her husband had died twelve months before from an acute attack of appendicitis, and she had been considerably prostrated by the shock and had been somewhat depressed ever since.

In August, 1911, she first noticed some white spots on the back of her neck. As they gave rise to no symptoms she was unable to say just how long they had been present; but considering how conspicuous they were it seems improbable that they could have been of long duration without her attention being called to them. She was not aware of the presence of any other spots. The present condition of her neck is well shown by the unretouched photograph (Fig. 1).

*Examination.*—The most striking feature of the lesions was their snow-white color, not at all the color of an ordinary scar, but whiter and more glistening. On the neck there were two groups of spots, one just at the hair margin and the other about 8 cm. below. Both groups were almost in the midline. The upper patch contained about a dozen lesions and the lower patch about forty. The spots varied from 1 to 5 mm.

Digitized by Google

in diameter, were sharply defined, more or less angular and showed no central depression. They were distinctly macular, and no infiltration could be made out; in fact, rather the reverse was true, for they were slightly softer than the surrounding normal skin. The skin over them was dry, thin and wrinkled, and the tactile sensation was decreased but not entirely absent. The surrounding skin was normal with the exception of a few freckles.

Four days later a careful examination revealed many similar lesions. There were three small patches around the waist, just under the belt, one on the right side of the neck near the clavicle, one on each thigh, one on the back of the right knee and one on the perineum. None of these patches contained more than ten spots; in fact, the majority of them contained not more than four. The lesions were white, slightly depressed, and to the eye resembled scar tissue, for they totally lacked gloss. A slight central depression could be made out with a lens, but not with the naked eye. To the touch the spots did not feel like scar tissue, for they were slightly softer than normal skin.

The clinical diagnosis of morphea guttata was made, for the appearance of the lesions seemed to rule out lichen planus atrophicus.

A strong irritating treatment containing resorcin was at first used, but beyond inflaming the skin it did absolutely no good. Vigorous massage or the use of suction cups would frequently cause hemorrhage into the lesions but not into the surrounding tissues, and when this hemorrhage cleared up it was difficult to see the original white spot. In from two to three weeks, however, the gloss would begin to reappear, and the lesion become whiter.

*Laboratory Investigations.*—The Wassermann was faintly positive. The hemoglobin was 90 per cent. by a standardized Sahli instrument. The red blood-cells numbered 4,900,000, and the white cells 9,000. A differential count of 500 leukocytes gave the following results: polymorphonuclears, 57.2 per cent.; eosinophils, 2.4 per cent.; large mononuclears, 0.4 per cent.; small mononuclears, 38.0 per cent.; transitionals, 1.6 per cent., and mast-cells, 0.4 per cent. The urine had a specific gravity of 1.020 and contained no albumin or sugar, and no excess of indican. Microscopic examination revealed the absence of casts and red and white blood-cells.

Cultures taken from the serum expressed from the lesions gave no growth of bacteria, nor did smears show any micro-organisms of any kind. One of the lesions on the flank was excised and fixed in alcohol. Sections were stained with hematoxylin and eosin, polychrome methylene blue, and neutral and acid orcein, both singly and in various combinations. All gave practically the same results. The most striking

Digitized by Google

feature of all sections was the almost complete disappearance of collagen and elastin in a circumscribed area in the subpapillary portion of the corium.

The horny layer was a trifle thickened but was otherwise normal. In the center of the lesion there was a gaping follicle almost completely filled with keratin. The granular layer was normal, but the prickle-cells had almost entirely disappeared. The basal cells showed marked hydropic degeneration, nearly every one containing one or two vacuoles. Pigment was entirely absent. The wavy line between the rete and corium was almost obliterated. The rete stained as usual.

In the corium there was a sharply circumscribed area corresponding in size to the macule, and extending about half the depth of the corium, in which the collagen had undergone marked rarefaction and degeneration. The fibrous tissue of this area stained very faintly with eosin and orcein, and not at all with any of the other stains. There was marked intracellular edema, only a few strands of fibrous tissue being present. Each fiber was quite separate from the others. The nuclei had entirely disappeared from all of these fibers. In this area also the elastin had almost entirely disappeared, and what little remained was in the form of short, almost straight fragments. Within the degenerated area there was no cellular infiltration, with the exception of a few stray cells around the edges. No glandular elements were found although the entire lesion was sectioned. Very few blood-vessels were found, only one or two being present; in them the walls were lax and shapeless and only the endothelial elements remained. No definite lymphatics were seen. One muscle was found, intact. The entire lesion was walled in by a moderately thick infiltrate, consisting of small round cells and fixed tissue-cells. This infiltration was especially marked around the blood-vessels. The blood-vessels outside of the degenerated area were not changed, nor were the glandular structures or muscles. In the degenerated area just inside of the infiltration proper a curious type of cell was found about the size and shape of a plasma-cell, but with an oval nucleus in the center, and a strongly acidophilic protoplasm. The granules were about equal in size to those in an eosinophil. All stages of these cells grading into typical fibroblasts were found. These cells were probably the acidophilic plasma-cells of Schridde.[1]

*Treatment and Result.*—At the end of six weeks the patient left town for the summer, with instructions to alternate between mercury by mouth and Donovan's solution. On October 16 she reappeared, stating that although she had obeyed instructions she was no better. Examination showed that the lesions on the body had not changed, but that the

1. Schridde: In Adami: Inflammation, New York, 1907, p. 66.

Digitized by Google

spots on her neck had assumed a different aspect. They were still white, but with a faint yellowish tinge, and were not so glistening as formerly. Their general character and size were still the same: they had not become confluent, but nearly every one contained from two- to four-minute honey plugs. Further biopsy was not permitted. On the next day the patient left for Porto Rico.

When first seen this case was almost clinically typical of the morphea guttata cases, but when later seen more closely resembled the lichen planus atrophicus cases.

Histologically the picture was totally different from that usually associated with lichen, but more nearly resembled Johnston and Sherwell's[2] case of "white-spot disease."

A critical comparison of the various types of "white-spot" cases is necessary in order to determine in just what group this case should be placed. Five groups of cases have been described; namely, "white-spot" disease, morphea guttata, lichen planus atrophicus et sclerosus of Hallopeau,[3] lichen albus of von Zumbusch,[4] and the *kartenblattähnliche Sklerodermie* of Unna.[5] Further work by Montgomery and Ormsby[6] has shown that the cases of "white-spot" disease are the same as the cases of morphea guttata, a group in which Unna's two cases are now placed. Recent work by Vignoli-Lutati,[7] Ormsby[8] and others has shown that lichen planus atrophicus is the same disease as lichen albus. There are a few cases, however, which do not entirely fill the conditions of either group, namely, the case of Johnston and Sherwell[2] and the case of Riecke.[9]

*Etiology.*—The origin of the morphea cases is in doubt. The disease nearly always occurs in women, either young or middle-aged, but beyond that nothing is

2. Johnston and Sherwell: Jour. Cutan. Dis., 1903, xxi, 302.
3. Hallopeau: Ann. de dermat. et de syph., 1889, Series 2, x, 447.
4. Von Zumbusch: Arch. f. Dermat. u. Syph., 1906, lxxxii, 339.
5. Unna: Handbuch der Pathologie der Hautkrankheiten, Berlin, 1894, p. 1121.
6. Montgomery and Ormsby: Jour. Cutan. Dis., 1907, xxv, 1.
7. Vignoli-Lutati: Dermat. Wchnschr., 1912, liv, 661.
8. Ormsby: Lichen Planus Sclerosus et Atrophicus, THE JOURNAL A. M. A., Sept. 10, 1910, p. 901.
9. Riecke: Arch. f. Dermat. u. Syph., 1909, xcix, 181.

Digitized by Google

known. The lichen planus atrophicus cases are now regarded as unusual forms of lichen planus in which the lesions begin as white papules, for the form of lichen planus which begins in the usual way and later becomes atrophic must be carefully excluded. Again the etiology is unknown; the disease occurs in nervous women over 30 years of age.

*Symptomatology.*—Lichen atrophicus begins as a papule, white, angular and firm to the touch, each papule containing either comedo-like pus or corresponding depressions. The lesions may become confluent and later leave scars. Circumscribed scleroderma is not distinctly papular, and the lesions do not contain spines or depressions, and do not become confluent. A slight inflammatory halo may be found in both conditions.

*Histopathology.*—In morphea the epidermis is practically intact, although there is frequently hyperpigmentation of the basal layer. In the corium there is hypertrophy of the collagen (the fibers running in straighter bundles than usual), diminished number of blood-vessels, dilated lymph-spaces, excess of pigment in the corium and infrequency of glandular structures. There is a general sclerotic condition of the corium.

The histopathology of lichen atrophicus as studied by Ormsby and others corresponds in a general way to the pathology of lichen planus, except that the infiltration is deeper. The horny and granular layers are usually thickened, while the remainder of the rete is atrophied. The wavy line between the rete and corium is missing. The upper portion of the corium shows collagenous hypertrophy. The elastin is reduced in amount. A cellular deposit is present deep in the corium and about the blood-vessels, glands and follicles. Horny plugs are present in the sweat-pores and the ducts show hyperkeratosis.

*Prognosis.*—Both diseases end in the same way, by atrophy so that a scar is left.

Digitized by Google

*Treatment.*—Irritative treatment in both classes of cases may do some good.

It can readily be seen that the chief difference between the two diseases lies in the following facts:

1. The lesions of lichen atrophicus are distinctly papular at the beginning, while the lesions of morphea are macular, or possibly maculopapular.

2. The lesions of lichen contain either spines or depressions, which is not true of the spots of morphea.

3. The lesions of lichen are more apt to become confluent than are the lesions of morphea.

4. There is a deep cellular infiltration in lichen that is lacking in morphea; in lichen the horny and granular layers are thickened while the remainder of the rete is atrophied, a point that is not true of morphea guttata in which the rete is usually intact.

It is evident that my case differs from either group in the following particulars: (1) in its clinical course, starting as a morphea-like condition and changing its lesions so as to simulate lichen planus atrophicus; (2) in its histology, there being a rarefaction instead of a sclerosis.

Nor does the case correspond to any of the atypical cases that have from time to time been reported as being related to one of two groups. It does somewhat resemble Johnston and Sherwell's case of "white-spot" disease in which the eruption consisted of white macules over the chest and shoulders, the lesions having the following histopathology: the rete consisted of four or five layers of cells showing hydropic degeneration, the stratum granulosum was practically absent, and the wavy line between the corium and rete had disappeared. The collagen was absent and the elastin was broken into short bits. There was an irregular lymphocytic infiltration. The few remaining blood-vessels were dilated and the endothelium projected into the lumen.

In Riecke's case, which in some respects is similar to mine, the lesions were macular and lustrous, and each

Digitized by Google

had a central depression. Later the lesions became confluent. Histologically the granular layer was thickened, but the rest of the rete was absent, with the exception of the basal layer, which showed marked hydropic degeneration. The connective tissue of the subpapillary portion of the corium was thickened and straightened, and contained no nuclei and no pigment. The elastic tissue was normal, the blood-vessels were increased in number and dilated, and the sweat-glands were unchanged. There was a moderate small-celled infiltration of the papillary and subpapillary layers of the corium. There was infiltration around the blood-vessels at the edge of the lesion. With the exception of the hypertrophy of the corium and the presence of an increase in the blood-vessels, the histology of Riecke's case is similar to that of mine.

White[10] also has reported a case of "dermatolysis" which has certain histologic similarities to mine, although an entirely different clinical appearance, the lesions being nodular and cherry-colored, and later becoming dirty white. Histologically there was rarefaction of the lower portion of the corium. The nuclei were retained, and there were endarteritis, marked epidermal changes, perivascular, perifollicular and periglandular lymphocytic infiltration, basophilic collagen, collastin, with a diminution of elastin, and later a disappearance of both collagen and elastin.

Finally Dubreuilh[11] has reported a case in which there was first a perifollicular rarefaction followed by scleroderma; but again this does not correspond to my case.

## CONCLUSIONS

1. It is generally conceded that there are two groups of cases that may give rise to "white spots," the morphea guttata group and the lichen planus atrophicus group.

10. White: Jour. Cutan. Dis., 1908, xxvi, 295.
11. Dubreuilh: Ann. de dermat. et syph., 1906, vii, 569.

Digitized by Google

Fig. 1.—Neck of patient when first seen.

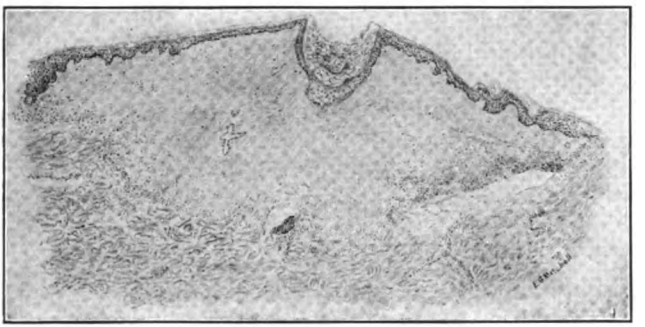

Fig. 2.—Low-power drawing through lesion.

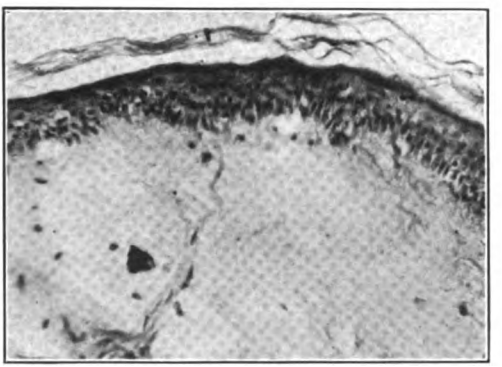

**Fig. 3.—High-power photomicrograph to show epidermis and subpapillary portion of degenerated corium.**

Digitized by Google

Digitized by Google

2. Typical cases of either one of these groups differ both clinically and histologically from typical cases of the other group. The large majority of reported cases fall clearly into one or the other class, and there is no instance on record in which the lesions of one type have been converted into lesions of the other type.

3. Clinically the character of the eruption in my case changed from that of a morphea guttata type to that of a lichen planus atrophicus variety, and in this respect is unique.

4. Histologically my case showed a subpapillary disappearance of both collagen and elastin, a condition approached only by the case reported by Johnston and Sherwell.

5. Judging by some of the cases reported it is impossible to draw a hard and fast line between the two types of disease. Riecke's case does not clearly belong to either type, nor does mine, for it presents features suggesting a transitional stage between the two groups.

I am indebted to Dr. Gilchrist for much advice and help, both in the study of the sections and in the preparation of the paper.

1204 Eighteenth Street N. W.

## ABSTRACT OF DISCUSSION

Dr. A. Ravogli, Cincinnati: I have had occasion to see some of these cases of white-spot disease, and I agree with the views of Dr. Hazen that some sclerotic condition of the tissues is always present. I recall the case of a woman in whom the white spots developed after an eruption of large papules, probably on a syphilitic basis. A photograph of this patient was published in connection with my article in the Beck *Festschrift*. I have also seen these lesions after lichen planus atrophicus, especially around the neck. Unless we consider morphea as a separate type, I think that in all these cases we have a degeneration of the connective tissues, with a lack of pigment and a resulting light, superficial scar.

Dr. H. H. Hazen, Washington, D. C.: So far as my observation goes, the histopathologic changes that occurred in the case reported in my paper represented to me a totally unfamiliar form of degeneration of the skin. From the literature, morphea and white-spot disease are totally distinct affections, and yet this case had features of each.

Digitized by Google

# NEUROMA CUTIS (DOLOROSUM)

M. L. HEIDINGSFELD, PH.B., M.D.
Professor of Dermatology, Ohio-Miami Medical College of the University of Cincinnati; Dermatologist, Cincinnati General Hospital
CINCINNATI

Cutaneous neuromas are either exceedingly rare or they have escaped proper recognition and enumeration in a field of specialized medicine preeminent for scrutinous detail and range of investigation. It is noteworthy that every structure of the skin save nerve-tissue has played an important and versatile rôle in the pathology and histogenesis of skin affections. The epidermis and its various layers, hair and its follicles, sweat-glands and ducts, oil-glands, lymph-vessels and blood-vessels, connective and elastic tissue, fat and unstriped muscle fiber have frequently been the seat of reduplication and structural activity, and each has often been accorded much significance and importance in the histogenesis of the host of cutaneous diseases. Nerve tissue, notwithstanding its important and versatile functions, its rich and wide distribution and its well-recognized changes in other localities, alone has escaped important notice, as evidenced by only two well-defined cases of cutaneous neuromas thus far recorded in the literature.

A neuroma cutis implies some form of new growth in the skin, multiple or single, variously sized, situated intimately in the skin, and containing new nerve elements. An important clinical feature in the cases thus far described is that they are the seat of very severe paroxysmal pain, of both spontaneous and secondary character. All subcutaneous nodules, whether painful

Digitized by Google

or painless, springing from amputated nerves or what not, the so-called false neuroma of Virchow, and the subcutaneous nodules of Wood, together with the so-called "neurofibromas" of Recklinghausen, painless embryonic connective tissue new growths of the skin, accredited with springing from the medullated sheaths of subcutaneous nerves, are for obvious reasons not to be considered in an affection which deals with new nerve elements, in a new growth which has its origin, development and location in the true skin.

### HISTORICAL

As already intimated, only two well-defined cases of neuroma cutis have thus far been reported in the literature.

Duhring, in 1873, reported a case of multiple neuromas, involving the left arm and shoulder, in a man aged 70. The affection began when the patient was 60 years of age, and the lesions increased steadily in numbers, until the affected areas were well covered. The lesions consisted of small, firm, split-pea-sized nodules, pinkish or bluish-red, and were firmly embedded in the skin. The overlying skin was somewhat scaly, but otherwise normal in appearance. For the first few years, the lesions did not cause any discomfort; soon after this they became the seat of very severe paroxysmal pain, of persistent excruciating and radiating character. These paroxysms were both spontaneous and induced, and were aggravated by unfavorable external influences. The color of the lesions was more livid during the seizures.

Kosinski, in 1874, reported a similar case, of sixteen years' duration in a male aged 30. The lesions, which numbered almost a hundred, were situated over the right thigh and buttock, and were extremely sensitive to touch and pressure. Both cases conformed in histologic structure to Virchow's description of amyelinic neuroma. The tumor, in Duhring's case, consisted of fibro-connective tissue and medullated and non-medullated nerve-fibers. Unstriped and striped muscular tissue was

Digitized by Google

nowhere in evidence. Kosinski's case also showed chiefly fibroconnective tissue and non-medullated fibers. Resection of the brachial plexus in the one, and the small sciatic nerve in the other, resulted in prompt relief from pain and gradual subsidence of the lesions. The symptoms relapsed in six months in Duhring's case, and the pain and discomfort, up to the patient's death, six and one half years after the operation, became as severe as ever.

## REPORT OF CASE

*History.*—J. F., saloon-keeper, aged 50 years, presented himself Jan. 31, 1913, with a small purplish-red nodule, somewhat larger than a split pea, situated on the anterior aspect, toward the inner side of the right thigh, 4 inches above the knee. It began twenty-five years before, following a slight injury, when the skin was caught between the staves of a sugar-barrel, which the patient lifted from a wagon. The lesion, which has undergone little material change in size for the past twenty or more years, caused the patient little discomfort, in the beginning. It soon became the seat of severe paroxysmal pain, of both spontaneous and induced character, of constant increasing intensity. It has become so sensitive in recent years, that slight pressure, notwithstanding that the patient is an unusually robust and strongly developed individual, measuring 6 feet in height and weighing over 200 pounds, almost induces syncope. Pressure and slight irritation from the trouser leg is almost unendurable. The pain is of a sharp, lancinating, excruciating character, and radiates up and down the thigh toward the genitocrural region and the knee. The paroxysms are often spontaneous, and are easily induced by even moderate indulgence in alcohol. The lesion bore such a striking clinical resemblance to that of a case of myomata cutis in my own experience, that this diagnosis was firmly entertained until a biopsy was completed.

The latter case, which I have already reported,[1] was that of J. R., a tailor aged 26 years, who presented himself with a small painful lesion above the left knee, which resulted from a fall from a bicycle nine years prior. The patient was thrown violently against a wagon, and sustained an ecchymosis with severe contusion, at the site of the present lesion. The central area took on a permanent bluish-red discoloration, and became the seat of severe excruciating pain of progressive character. The pain was of a lancinating, radiating character, often spontaneously paroxysmal, and easily induced by pressure or slight

1. Heidingsfeld, M. L.: Myomata Cutis, THE JOURNAL A. M. A., Feb. 16, 1907, p. 562.

Digitized by Google

irritation. Pressure from the undergarments or trouser leg was at times intolerable. No diagnosis was entertained until the biopsy was completed. The microscope revealed a myoma cutis. Extirpation gave immediate and permanent relief.

*Histologic Report.*—The lesion, with a narrow border of normal tissue, was thoroughly excised to the subcutaneous fat, by means of an elliptical incision, and embedded in paraffin, sectioned serially and stained after the ordinary methods. A small portion was reserved for examination of nerve fibers. It is needless to state that I immediately sought the presence of unstriped muscular tissue. Not a vestige of involuntary muscular fiber was discernible in any of the sections.

Under low-power magnification, the growth was observed to consist of an irregularly round mass of deeply stained tissue, irregularly convoluted and containing numerous spaces which were easily recognized as vascular in character. The greater number of these were thick-walled veins; some were lymphatic spaces, with an extensive endothelial proliferation. A few small thick-walled arteries were interspersed. The mass rested in the true skin just below the epidermis, and extended well into the depths of the cutis, but was separated from the normal-appearing subcutaneous fat by a considerable mass of connective tissue. The pathologic area was surrounded on all sides by a narrow well-defined capsule of connective tissue. The overlying papillae were entirely obliterated, apparently from a distention atrophy, inasmuch as a small portion of the circumference of the tumor mass projected slightly above the level of the surrounding epidermis. Under stronger magnification, the tumor was observed to be made up almost entirely of small irregularly round or oval cells, with large, somewhat deeply stained nuclei arranged here and there in irregular rows with a thickness of several layers, but for the most part in thickly proliferated masses. The cells were indistinguishable and apparently identical with those which lined the large lymph-spaces and venous spaces. No other structures or specialized elements were discernible in the tumor mass except in the specially stained preparations which showed an abundant mesh-work of richly distributed non-medullated nerve-fibers, which ramified through the tumor mass in an arborescent manner. The epidermis was normal. The rete malpighii was of normal thickness and contained its well-defined layer of columnar cells, and was covered with a normal stratum granulosum lucidum and corneum. Hair, hair follicles, and sweat or sebaceous glands or ducts were not demonstrable in the cutis or epidermis, either above or below, or in proximity to the growth. The cells in the pathologic area did not preserve the even, diffuse distribution of an ordinary lymphoma, but conformed more to that of a lymph-angioma or rather an endothelioma. The pathologic diag-

Digitized by Google

nosis was that of a neuro-endothelioma of amyelinic type and conformed very closely in its histologic character to the amyelinic neuroma described by Virchow.

## GENERAL DEDUCTIONS

Cutaneous neuromas bear a close and deceptive clinical resemblance to myoma cutis, and the microscope must be relied on to effect the differentiation. My own case of neuroma preserved the greatest possible resemblance in point of clinical appearance, chronicity, nature and character of onset, development and symptomatology, to my previously reported case of myoma cutis. When the microscope failed to reveal the presence of involuntary muscular fibers, I was momentarily bewildered.

Fourteen cases of well-defined myoma cutis have thus far been recorded in the literature. Pain, of a severe lancinating character, spontaneously paroxysmal or easily induced, was associated in nine of the cases, and was absent in the remaining five. In some of the cases nerve abnormalities were noted, but in the vast majority no such observations were made, possibly because of technical omissions, in this special direction. Verneuil, for example, reports a dissecting-room case of myomata cutis in which nerve-fibers were present in such abundance that the diagnosis of neuroma could be entertained almost as well as that of myoma.

The diagnosis of myoma must be considered well taken if there has been a preponderating proliferation of well-defined involuntary muscular fiber; but this in and of itself fails to explain why slightly less than two-thirds of the cases present clinical characteristics in the form of severe paroxysmal pain, spontaneous or easily induced in character, whereas slightly more than a third of the cases are free from all special symptoms. It also fails to explain why some of the cases show an abnormal proliferation of nerve elements, and others no special change. The explanation that the pain is due to mechanical pressure of the growth on the surround-

Digitized by Google

ing nerve endings, scarcely suffices; otherwise all growths in the cutis would give rise to similar symptoms.

The pathologic proliferation of involuntary muscular fiber in the true skin is unquestionably noteworthy. I am of the opinion, however, that it is not an incident of very exceptional character. I have observed, for instance, marked proliferation of involuntary arrectores pilorum in some of the chronic dermatoses which are attended with persistent creepy and chilly sensations, notably pityriasis rubra pilaris. It is evident that this tissue can readily undergo a very material compensatory hypertrophy under abnormal stimulation, and its hypertrophic presence can readily be considered an effect rather than a cause. If this is true, no cutaneous abnormality would, in all probability, be more conducive to involuntary muscular fiber proliferation than a neuroma, with its attendant intolerant paroxysmal attacks. It is therefore obvious that some of the cases of myomas can, on clinical as well as on pathologic grounds, be considered to be neuromas rather than myomas. Unassociated myoma in my case can probably be attributed to apparent primary absence of all specialized structures, hair, follicles, glands, etc., as well as involuntary muscular fiber. At all events, all excessively, persistently painful lesions of the skin, in which the pain is of a severe, lancinating, spontaneously paroxysmal or easily induced character, warrant a careful technical examination of nerve fibers, and their abnormal presence justifies, in my opinion, irrespective of other findings, the diagnosis of neuroma cutis. The cases doubtless justify further differentiation, in the form of neuromyoma, neuro-endothelioma or neurolymphangioma, in conformity to the preponderating hypertrophy of the associated pathologic tissue.

## CONCLUSIONS

Neuroma cutis is a well-defined clinical and pathologic entity. Its relative infrequency is more illusive than real. Its failure to receive proper recognition and

Digitized by Google

enumeration is doubtless due in large measure to technical omissions. There are good grounds for believing that well-defined cases of neuroma have been accorded classification with other affections of the skin. Every chronic lesion of the skin attended with severe paroxysmal pain, of spontaneous or easily induced type, should be carefully examined for nerve abnormalities and accorded recognition in conformity to the clinical and histologic findings, irrespective of other pathologic changes.

19 West Seventh Street.

BIBLIOGRAPHY

Arnosan and Vaillard: Jour. de méd. de Bordeaux, 1881.
Brigadi and Marcacci: Imparsiale, 1881.
Crocker: Brit. Jour. Dermat., 1897, pp. 1, 47.
Duhring: Am. Jour. Med. Sc., October, 1873.
Hardaway: Am. Jour. Med. Sc., April, 1886, p. 511.
Heidingsfeld, M. L.: Lancet-Clinic, June 3, 1899.
Herzog: Jour. Cutan. Dis., 1898, p. 527.
Hess: Virchows Arch. f. path. Anat., 1890, cxx, 321.
Jadassohn: Virchows Arch. f. path. Anat., 1890, cxxi, 88.
Jansch: Verhandl. deutsch. dermat. Gesellsch., v, 360.
Kosinski: Centralbl. f. Chir., 1878, No. 16, p. 241.
Lukasiewicz: Arch. f. Dermat. u. Syph., 1892, xxiv, 33.
Marschalko: Monatsh. f. prakt. Dermat., 1900, xxxi, 313.
Neumann: Arch. f. Dermat. u. Syph., 1897, xxxix, 3.
Rump: Arch. f. Path. Anat., 1880, lxxx, No. 1, p. 177.
Roberts: Brit. Jour. Dermat., 1900, p. 115.
Verneuil: Société anatomique.
Virchow: Die Geschwülste, Berlin, 1867, iii, 97.
White: Jour. Cutan. Dis., 1899, p. 266.
Darnall, William Edgar: Multiple Neuromata of the Skin, THE JOURNAL A. M. A., Dec. 1, 1906, p. 1810.

Digitized by Google

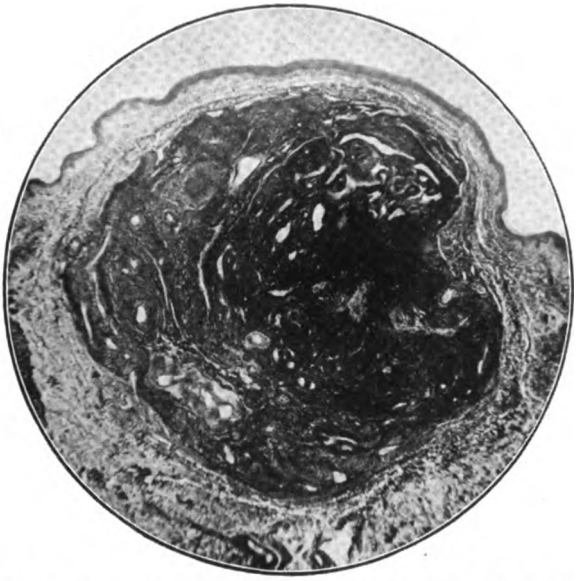

Fig. 1.—Neuroma cutis (low magnification). Irregularly round tumor mass of deeply stained convoluted tissue, containing numerous lymph-spaces and vascular spaces. Situated in the true skin just below the epidermis. Overlying papillae obliterated by distention atrophy. Entire absence of all glandular and special structures.

Fig. 2.—Moderate magnification. Border of growth showing convoluted structure and fibrous capsule. Cells arranged in irregular rows of several layers' thickness and in thickly proliferated masses.

Digitized by Google

Digitized by Google

Fig. 3.—Moderate magnification. Center of growth showing general cellular structure and masses of cellular tissue containing lymph-spaces and vascular spaces.

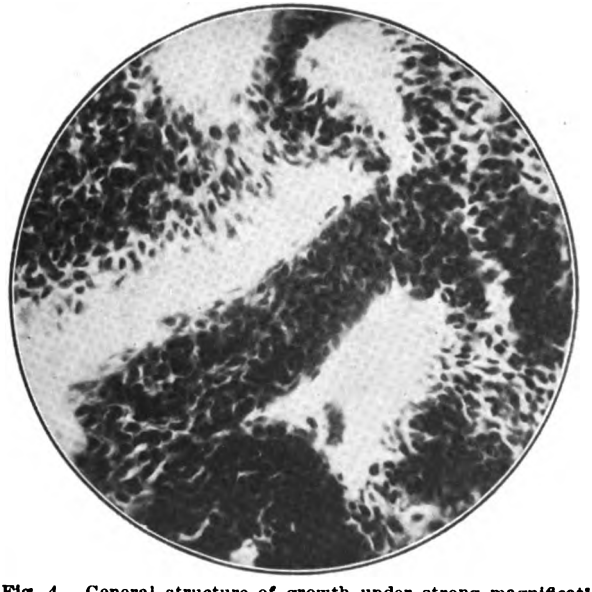

Fig. 4.—General structure of growth under strong magnification. Small, irregularly round, deeply stained cells with large nuclei surrounding lymph-spaces and vascular spaces.

Digitized by Google

Digitized by Google

# SKIN DISEASES AMONG FULL-BLOOD INDIANS OF OKLAHOMA

EVERETT S. LAIN, M.D.
OKLAHOMA CITY, OKLA.

The suggestion of studying skin diseases in the American Indian was first made to me by Dr. Howard Fox, in July, 1910. About that time I also read with much interest an abstract[1] of a report by Dr. Isaac Levin, on "Cancer among the American Indians and Its Bearing on the Ethnologic Distribution of the Disease," laying particular stress on its relative infrequency among the full-bloods, made to the American Institution of Cancer Research, May 2, 1910.

My statistics and reports are largely based on my personal observations and investigations among the full-bloods or so-called "uncivilized tribes" of Western Oklahoma, composed of Arapahoes, Cheyennes, Caddos, Kiawas, including also a small number of Choctaws, Poncas, Wichitas, Seminoles, Delawares and Sioux. These investigations I have made on my own initiative, covering a period of the past eight years as opportunity was afforded. Furthermore, I may say that my diagnoses were not verified by microscope, Wassermann tests, etc., except in a few of the mentioned cases, but were based on clinical findings with only meager history in any case. The examinations of children were made in the different government schools or in the buildings of the agencies, while nearly all of the adults were examined under the most adverse environments. I was

1. I have since received a reprint of this report which has given me much inspiration in my own investigations.

Digitized by Google

courteously received and kindly aided by the agents and physicians in charge of the reservations wherever possible, though I was accompanied most times by only a lazy, illiterate interpreter and made examinations while we both sat flat on the filthy, bespattered dirt floors inside a narrow tent or tepee. Among the conditions we experienced might be mentioned irritating smoke curling slowly from the camp fires around our heads to the vent at the top of the tepee, while the innumerable and ever-present mixed breed of dogs snapped at flies and scratched their prolific crop of parasites at our sides. Nor were our photograph galleries equipped with soft rugs, cushioned chairs or carefully painted backgrounds, but instead consisted of the most level place on the ground with our patient sitting on a stick of wood or perhaps his feet, with dirty canvas—the tepee—for a background; while the subject to be photographed constantly wiggled and changed positions or again stuck out his hand for more shining coins. Under these conditions, I could not obtain with any degree of accuracy information relative to frequency, recurrence, duration of case or the exact age or patient; but only recorded such as my eyes discovered or my interpreter was able to elicit by his sign language. During the full period of my observations, I made a more or less imperfect examination of more than five thousand Indians. In one thousand of this number only was I enabled to partially strip and make a satisfactory examination for all the skin lesions which might be present. I have, therefore, based my estimate among this limited number. As will be observed from the figures given in the table, I have found some diseases named of equal or greater frequency than among the whites. Though let me say here that I am now fully persuaded that this race of people is not subject to the same number and variety of skin lesions as are to be found in our own race.

The diseases most common are: nevus, acne, eczema, lupus vulgaris and lupus erythematosus, pityriasis capi-

Digitized by Google

tis, seborrhea, among schoolchildren; syphilis, verruca, pediculosis, impetigo and other forms of pus infection, and, perhaps the most frequent of all, tuberculosis of the lymph-nodes, particularly in the cervical region.

TABLE 1.—TRIBES AND NUMBER OF CASES EXAMINED

Arapahoes, 337; Cheyennes, 381; Caddos, 310; Kiowas, 135; Wichitas, 70; Seminoles, 58; Choctaws, 47; Apaches, 46; Osages, 63; Delawares, 31; Poncas, 56; Sioux, 38.

| Diseases Found | Cases | | Remarks |
|---|---|---|---|
| | No. | Per Cent. | |
| Tuberculosis of cervical lymph-nodes | 238 | 25 | Of Arapahoes and Cheyennes. |
| Lupus | 53 | 3 | Of certain tribes. |
| Syphilis | 46 | 3 to 5 | More common in Arap. & Chey. |
| Pediculosis | 186 | 5 | Common. |
| Tinea circinata | 8 | ..... | Not common. |
| Pityriasis capitis | 210 | ..... | Limited to those who are or have been in school. |
| Tinea tonsurans | 4 | ..... | Not common. |
| Seborrhea | 31 | ..... | Have been in school. |
| Impetigo | 137 | 6 | Of children not in school. |
| Scabies | 4 | ..... | School children. |
| Furunculosis | 25 | ..... | Not common. |
| Variola | 5 | ..... | Sweeps the whole unimmune vicinity when started. |
| Eczema | 39 | 2 | Of adults, dry or squamous type. |
| Verruca | 226 | 10 | Of all tribes. |
| Acne | 212 | 10 to 20 | In "teen" age. |
| Keloids | 13 | ..... | ..... |
| Nevus | 28 | ..... | Quite common. |
| Urticaria | 4 | ..... | Not at all common considering their impure food. |
| Rhinophyma | 2 | ..... | ..... |
| Rosacea | 7 | ..... | Not common. |
| Keratosis senilis | 18 | ..... | Quite common among the aged. |

The following diseases were especially looked for but no case found:

Epithelioma
Pellagra
Psoriasis
Lichens
Herpes zoster
Tinea favosa
Dermatitis herpetiformis
Sarcoma.
Alopecia
Icthyosis
Erythema multiforme
Erysipelas
Sycosis

Without attempting to discuss each disease mentioned in regular order, I might first correct an erroneous idea which I had entertained before the beginning of my investigation, namely, with reference to the frequency of syphilis. I did not find this disease present in so large a number of these aborigines as I had been led to believe by former writers and by my conversations with

Digitized by Google

some of the employees. On the contrary, with the exception of the Arapahoes and a portion of the Cheyennes, I did not find this disease as frequent as among our own highly civilized and—dare I say—over-sexualized race of people. Capt. John H. Seger, of Colony, Oklahoma, who has been with the Indians and connected with the United States Indian Service for more than forty years, and to whom I am much indebted, informs me that syphilis was practically unknown among the Indians until they became intimate with the Mexicans and white races after becoming more civilized. Possibly my findings in this disease may be partially explained by a custom which formerly existed in most tribes, namely, that of allowing the deformed or diseased infant to die without an effort at restoration or, as practiced in earlier days, to be buried alive. From personal observations and from inquiries made of persons long engaged in the Indian service, I believe that their custom of scanty dress and lack of false modesty, from infancy to adult life, or until they are taken into the schools and put under rigid training, has been conducive to less prostitution and the resultant diseases than in our own white race.

One may readily account for the prevalence of impetigo when is seen the real dirt, normal secretions, and excretions of the body which are many times allowed to remain on the skin of their children and helpless babes, until only by chance it is removed.

Again, it is a custom of their medicine men and other would-be assistants to treat open lesions and ulcers or infections, by placing their mouths over these lesions and sucking out, as they term it, the poison of the "witches" or "evil spirits" which has encompassed their bodies, thence going from one to another with their filthy mouths and hands disseminating this infection to all with whom they come in contact. This filthy mouth may soon join in a circle of bucks seated on the ground, passing the common "pipe of peace"

Digitized by Google

from mouth to mouth until all have had an equal smoke and the pipe is empty.

Notwithstanding that the pediculus is an almost ever-present organism, I was impressed with the rarity of the ordinary resultant pustules and excoriations so characteristic in the infected white person.

The enthusiast on dietetics, among our numbers, might find food for thought and partially verify his claims for the meat-eaters, for Indians have eczema, though we found the percentage among these tribes not so high as that given in the table of the American Dermatological Association.[2] The forms are chiefly the dry squamous or the papular variety.

The extreme rarity of dermatitis medicamentosa, dermatitis venenata and other acute forms, may partially be accounted for by the lack of common usage of drugs, soaps, and other chemicals, though the Indians frequently apply quite freely on their faces and other exposed parts, paints and dyes made from the wild plants, berries, etc.

The skin of the Indian is apparently almost immune to the poison-ivy and other plants which cause so much discomfort to the women of our own race.

Their simple menu, consisting chiefly of a few of the vegetable roots, beans, corn, and meats of the wild animals, and beeves, dried or raw, or, as is many times the case, partially decomposed flesh of an animal having died of disease, does not predispose to gluttony with resultant urticaria, erythema multiforme, etc. No typical case of erythema multiforme was observed in my entire investigations and but few cases of urticaria.

Neither does the Indian's well-balanced and never overtaxed nervous system predispose to lichen planus, pruritus, hyperesthesias, and other neurocutaneous diseases. His meals are deliberately eaten and with full relish, but on account of its poor quality he has considerable trouble with his stomach and bowels, though with but few manifest symptoms on his skin.

2. Stelwagon, Henry W.: Essentials of Diseases of the Skin, p. 280.

Digitized by Google

Nature's adornment and protector of their heads—their hair—is to be envied by our ladies who are constantly adding to their own more of a foreign make. Not a bald-headed Indian of either sex was observed among the total number examined. Syphilis does not seem so conspicuously to affect their hair as it does that of the whites. The color of the hair in the full-bloods, in nearly all tribes, is the monotonous coarse-black or dark brown. Two cases of deep red hair were noted in the Delawares, though it was quite evident that they were not full-bloods. Their almost constantly bared heads render their scalp diseases few. Only four cases of tinea tonsurans were found, though there were many cases of pityriasis capitis, commonly known as dandruff. The latter disease is quite definitely limited to those who are at present, or have been in the past, closely confined in schools and made to carry out the rigid regimen of the use of comb and brush. In one school nearly 60 per cent. of the children above 12 years of age were affected with this disease. Practically no pityriasis capitis or seborrhea was found in the older and unconfined of the tribes, which further confirms the later accepted theories as to its etiology.

Only brief observations among full-blood Indians of Oklahoma are necessary to impress one with the prevalence of tuberculosis of the lymph-nodes. This disease seems to have a special selection for the lymph-nodes in the cervical and submaxillary regions, both anterior and posterior chains. It seems to be an infection which most readily attacks the young, beginning in many cases as early as the first or second years of age and continuing until after the age of 25 or 30, when most patients appear to have recovered. No doubt many of them succumb to its invasion of other organs of the body, for I observed several cases of tuberculosis of the bowels, and tuberculous peritonitis, which I am quite sure was an extension of the infection beginning in the cervical region. Just why tuberculous infection of the cervical

Digitized by Google

lymph-nodes is so much more prevalent in this race than in our own is a question for solution. It may be because tuberculosis in general is so very common. I have also learned by numerous radiographs of the Indians that a large number recover from the pulmonary type of this disease. It is probably due, however, to the frequent occurrence of follicular tonsillitis, quinsy, etc., leaving the throat in a receptive condition for the tubercle bacillus, which, perhaps, lurks in the numerous meals of tuberculous meats on which he feasts without a qualm. The percentage of such diseases among the Indians is so high that I believe the special attention of the United States Indian Service should be called to it, so that such steps may be taken toward prevention of this initial infection as have been recently taken with reference to diseases of the eye among them.

Not a single case of that disease which is becoming so alarmingly prevalent in the United States, namely, pellagra, have I observed, nor have I had any reported by any of the physicians in charge of the Indians. The Indians, too, subsist mostly on the poorest quality of corn and many times spoiled foods and always endeavor to pitch their portable dwellings on the banks of the nearest stream of water.

In my examination of the different tribes and through inquiries of agents and physicians in charge, I made particular search for epitheliomas or any other superficial, malignant growths, without a single case having been fully verified as such. Dr. Roland of Muskogee, reports having seen one case of probable epithelioma situated just above the eyelid in an old Indian but this lesion was not verified microscopically and Dr. Roland admits that there is a probability of its being only an extended verruca.

Drs. C. R. Hume, Anadarko, A. L. Blesh, Oklahoma City, and F. H. Clark, El Reno, each report having seen a case which they diagnosed as cancer of internal organs, though their cases were not fully verified.

Digitized by Google

The report from Dr. Isaac Levin, previously mentioned, showed but twenty-nine cases of cancer among all the tribes throughout the United States. Also, not one of the cases reported was from Oklahoma.

Compare, if you please, an equal population, throughout the States, of our own race and we have some interesting data which should inspire a further investigation into the etiology and propagation of this dread disease.

The mortality statistics of the United States from eighteen states for the year 1900 gives 63.9 deaths from cancer per hundred thousand, and in 1909, 79.6. The same report from the same states gives us a total of 425 deaths from skin cancer alone from 1900 to 1909.

CONCLUSIONS

1. The full-blood Indian is not subject to the variety of dermatologic lesions found in the white race.

2. Full-blood Indians are almost free from such skin diseases as may be produced or excited by menstrual disorders or an overtaxed nervous system.

3. Though their food is limited in variety and poor in quality, they do not have many of the skin lesions which we ordinarily attribute to such causes.

4. Previous to civilization, baldness was probably unknown among the American Indians.

5. While syphilis is common among the different tribes, it is not so prevalent as the sensationalist would have us believe.

6. Tuberculosis of the lymph-nodes, particularly of the cervical region, is very prevalent and might be largely prevented if more prophylactic measures were enforced by our United States Indian Service.

7. The uncivilized Indian apparently is yet free from pellagra and almost immune to cancer.

Might we not find in a study of his simple outdoor life, limited foods, the character of his skin, etc., a clue which may lend material aid in the discovery of the etiology and propagation of these diseases among our own race of people?

Digitized by Google

Fig. 1.—Lupus erythematosus. Cheyenne girl, aged 16 years. Disease present since 8 years of age.

Digitized by Google

Digitized by Google

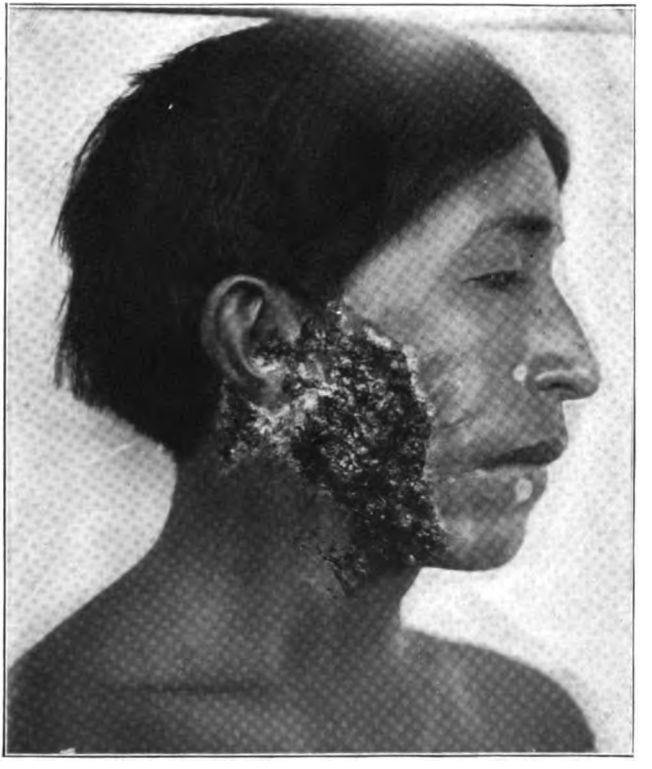

Fig. 2.—Scrofuloderma. Ponca Indian, diseased since 4 years of age, now aged 15 years.

Digitized by Google

Digitized by Google

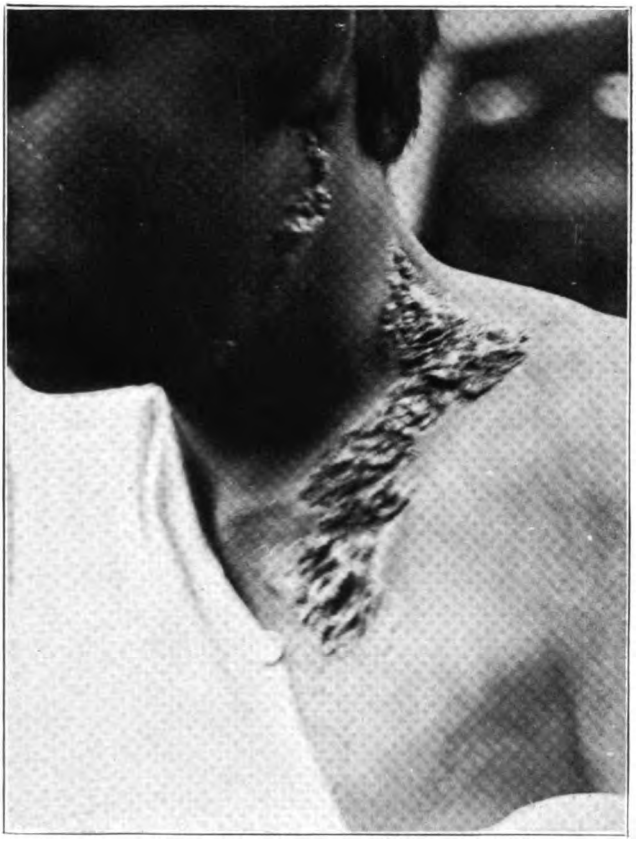

Fig. 3.—Scrofuloderma. Arapahoe Indian, aged 18.

Digitized by Google

Digitized by Google

**Fig. 4.—Vitiligo. Cheyenne Indian, aged 87 years.**

Digitized by Google

Digitized by Google

## ABSTRACT OF DISCUSSION

Dr. Howard Fox, New York: I have been particularly interested in this paper on account of the studies which I made among the negroes several years ago. In quite a number of instances, the skin diseases common in these two races correspond very closely, while in others they are diametrically opposite. For instance, the negro is practically exempt from psoriasis, and Dr. Lain has made the same observation of the Indian. The same is true of dermatitis venenata due to ivy poisoning; the full-blooded negro, while perhaps not absolutely immune to this infection, certainly does not suffer from it as does the white man. These are two points of similarity observed in these two races, but there are several other points in which our observations are quite dissimilar. Dr. Lain found many cases of pediculosis capitis among the Indians, while I found very few such cases among the negroes. Tinea is quite as common in the negro as in the white. Pellagra is very common among them, and I was surprised that Dr. Lain did not find a single case among the Indians.

Dr. M. L. Ravitch, Louisville: In addition to the points of similarity already mentioned in the skin affections common to the negro and the Indian races, I would include the tuberculous and the syphilitic dermatoses. Pediculosis I have found to be very common among the negroes, and I have also seen a few cases of psoriasis. I think the outdoor life of the Indians keeps them comparatively free from the skin diseases which are more or less prevalent among civilized people. Again, I do not think that the negro, as seen in New York, is of the same type seen in the South; he is a little more civilized and perhaps more apt to acquire the same dermatoses as the white people among whom he lives.

Dr. Ernest Dwight Chipman, San Francisco: I think the rarity of certain dermatoses among the Indians is due to the limited opportunity they have had to acquire them. As a possible analogy I might state that in San Francisco scabies was almost non-existent until the time of the Spanish War, when a great many strangers came there; after that, scabies spread with great rapidity. Ringworm, ten years ago, was extremely rare; now it is very common. When the Indians have the same opportunity to acquire the dermatoses of the white race these affections will probably be just as common among them.

Dr. A. J. Markley, Denver: Has Dr. Lain observed an increase of tuberculosis among the Indians since they have been confined to certain reservations and fixed habitations? In one of the earlier histories of the Indian race I have read that tuberculosis was practically unknown among them when

Digitized by Google

the country was first settled; also, that tuberculosis of the bones was very rare, although a few instances of tuberculous diseases of the spine were observed.

Dr. Isadore Dyer, New Orleans: In this study of skin diseases among the Indians, there seems to be a striking absence of the ulcerative type of skin affections. In the South, among the negroes, we find a large number of such cases either of syphilitic origin or the result of their occupation. Probably the latter factor would account in a large degree for the absence of such lesions among the Indians. The negro in the South lives under conditions of community life which subject him to a variety of diseases that are carried from person to person; while the Indian, on the other hand, spends much of his time out of doors. In considering this general subject, we should regard it from a sociologic rather than from an ethnologic point of view. There is no reason why the Indian, who does not belong to an inferior race, as does the negro, should have the same diseases as the latter, or that the two races should be compared as equal or similar.

Dr. M. L. Heidingsfeld, Cincinnati: Dr. Lain's paper sets forth one very interesting fact of possibly more historic than practical interest, namely, that syphilis is a rare disease among our American Indians. This is at variance with the much-exploited, but doubtless erroneous, idea that Columbus and his followers brought syphilis for the first time to the peoples of Europe. Careful investigation has shown that syphilis has been pandemic in Europe for ages, as far back as there is any authentic record of medicine. Dr. Lain's observations are in perfect accord with the findings of archeologists who have interested themselves in the study of this question, in relation to our American aborigines. The exhumation of prehistoric bodies has shown no syphilitic changes in the skull and bones of either the mound builders or American Indians. The bones of these peoples, however, have shown changes indicative of tuberculosis.

Recently an extensive exhumation of a large prehistoric burying ground near Cincinnati, showed no changes indicative of syphilis in the bones of the prehistoric tribes. Bodies, however, which were buried with glass beads and other trinkets of a more modern civilization, postdating the discovery of America, occasionally showed changes typical of syphilis.

Dr. Everett S. Lain, Oklahoma, Okla.: There is no doubt that the rarity of certain skin diseases among the Indians, particularly those of the contagious type, may be largely due to the habits of this race, living out of doors, as they do, and lacking contact with the weaker races. Their degree of

Digitized by Google

immunity is high; that I have seen demonstrated time and again by their rapid recovery from serious infections.

In answer to Dr. Chipman as to the increase of tuberculosis among the Indians in the reservations, I would say that I began my investigations with that point in view, and in the course of my researches I came across an article dating back to 1746 relating to the Indians residing in or near the eastern portion of the present state of Oklahoma, and the author mentions that a disease which he calls consumption was then quite common among them, and he particularly refers to involvement of the bones. In our museum we have the excavated bones of Indians which show unmistakable evidence of tuberculosis. As to whether this disease is on the increase among them, it is so reported by men who have investigated that feature. The resistive power of the Indian is high. The Indians are practically all affected with tuberculosis, as almost invariably shown by the roentgenographic findings in the lungs. Again, the government physicians tell us that, although they find the disease alarmingly prevalent among the Indians, the percentage of recoveries from it is higher among them than among the whites.

Digitized by Google

# THE NEWER CUTANEOUS MYCOSES

ERNEST DWIGHT CHIPMAN, M.D.
SAN FRANCISCO

The investigation of various fungi, called by French writers *les champignons parasites,* offers one of the most inviting fields of medical research. The rapid increase in the number of cutaneous lesions traced to fungous origin inevitably brings the dermatologist face to face with problems in mycology which clinicians have been accustomed to relegate to the botanist. While the science of bacteriology has developed rapidly as a branch belonging particularly to medicine, the study of true fungi has been generally considered as something of merely academic interest. Medical mycology has been lagging behind. Our schools give it scant notice and American literature deals with it only to the extent of detached case reports. So sparse, in fact, is our literature on the general subject of pathogenic fungi that I could not find a single complete description of the common thrush organism in more than a score of American text-books consulted for the purpose. It seems certain that if our knowledge of mycology is to progress as it deserves it must be through the same cooperation of clinician and laboratory worker that has made possible the notable advance in bacteriology.

Of course all bacteria are fungi though of a special order, differing from the so-called true fungi in their direct reproduction by fission; but there has always been a tendency to separate the true fungous diseases from those caused by bacteria. Recently, however, such striking resemblances have been shown as to make the distinction seem wholly artificial. Many diseases due

Digitized by Google

to fungi closely simulate bacterial diseases. The mode of action of pathogenic fungi is identical with that of bacteria, namely, by toxins, which has been shown by numerous observers. Serologic reactions have been found in fungous diseases quite comparable to those of bacterial infections. Likewise facts relating to immunity in mycoses have been shown to be exactly analogous to those of bacterial disease. These are reasons for bringing the two classes of organisms into closer union rather than considering them as opposites.

The purpose of this paper is to emphasize the need for a wider knowledge of the pathogenic fungi as well as to recapitulate some of the available facts concerning the more recently described mycoses with which dermatologists may have to deal.

For even a brief survey of these conditions some preliminary consideration must be given the general classification of fungi in order to appreciate their relationship to one another. This question may be approached from several distinct points of view. The purely botanic classification would seem most precise in that it arranges various units into groups or families based on genealogic affinities. The classification on a simple morphologic basis, as the grouping of bacteria under such titles as bacilli, cocci, etc., will not suffice. The division of fungi into groups according to the pathologic processes they cause may be of practical value to the clinician. Bodin,[1] first arranging fungi as far as possible in groups according to their relationship, would thereafter adopt an admittedly artificial classification according as the lesions they cause in man are strictly cutaneous or capable of becoming generalized within the body.

Up to a certain point our classification must rest on a sheer botanic basis. The exact place of fungi in the plant world is seen by constructing a table beginning with the thallophyta, which differ from the other funda-

1. Bodin: Les champignons parasites de l'homme.

Digitized by Google

mental forms of plant life in that they show no differentiation into distinct parts as root, stem and leaf.

The group of thallophyta presents three subgroups:

1. Schizophyta, or fission plants.
   (*a*) Schizophycae: chlorophyll present.
   (*b*) Schizomycetes or bacteria: chlorophyll absent.
2. Algae.
3. Fungi.

Fungi are divided into two subgroups:

1. Myxomycetes: devoid of sheath and parasitic only to vegetable life.
2. Eumycetes: having a cellulose sheath and parasitic to man and animal.

Eumycetes, then, are the fungi with which we are concerned in this discussion. They are divided according to their modes of reproduction into four groups:

1. Oomycetes: egg-producers.
2. Ascomycetes: fruiting by asci.
3. Basidiomycetes: forming basidia.
4. *Fungi imperfecti:* mode of reproduction yet unknown.

*Fungi imperfecti* constitute a much-discussed group in mycology. One view is that they are fungi which were formerly superior or perfect but which have become inferior or imperfect. In other words, they have lost their superior form of reproduction, the ascus, and have retained their lower form, the conidium. Another conception is that they are primitive forms which are offshoots of other fungi of more complicated forms.

It will be noted that this classification makes no mention of the terms "yeasts" and "molds." In a general sense fungi which reproduce by budding are called yeasts, while those which fructify by spore-formation are termed molds.

The true yeasts are fungi that reproduce vegetatively by budding and that form ascospores under certain conditions. Some fungi that morphologically are yeasts and reproduce by budding do not form ascospores. Some

Digitized by Google

also resembling yeasts morphologically produce disease, and their exact botanic position is uncertain. They are termed "pseudoyeasts," "torulae" or "mycodermae," and are grouped among the *fungi imperfecti.*

While the yeasts are unicellular the molds are multicellular. It is difficult to define molds. The systematic botanist does not recognize any such group. Considered collectively, however, they present certain superficial resemblances. They all possess a plant body made up of hyphae. They do not form a specific class of fungi, for they include members of each of the four chief groups of fungi. The term "hyphomycetes" is often used to cover this group.

Under the title of newer cutaneous mycoses may be included those skin diseases the specific fungus of which is of relatively recent discovery. Some of these, as is well known, are not limited to the skin but become more or less generalized. It is not within the scope of this paper to discuss all of these dermatomycoses exhaustively. The intention is rather to mention certain aspects of each with the view of emphasizing the importance of their recognition.

The diseases selected for special mention are trichomycosis of Castellani, blastomycetic dermatitis, granuloma coccidioides, sporotrichosis, oidiomycosis and hemisporosis. New light recently shed on the subject of eczema marginatum and the group including actinomycosis, mycetoma, etc., brings these affections also within the range of this discussion.

Trichomycosis is the name applied by Castellani to an affection of the hair of the axilla which he has often observed in the hot, damp districts of Ceylon. The disease consists of soft formations, yellow, black or red, and easily removed by scraping with a triangular needle or similar instrument. The yellow variety is due to a bacillus-like fungus, probably a streptothrix or one of the microsporoides. The pigmentation in the black and red varieties is caused by coccus-like organisms which grow in symbiosis with the streptothrix-like fungus.

Digitized by Google

What was described in 1860 by Hebra as eczema marginatum was subsequently considered of parasitic nature and was called inguinal trichophytosis until Sabouraud in 1907 described the parasite as an epidermophyton and showed it to be entirely distinct from the trichophytons. The clinical aspects are well known. The sharp outline with somewhat elevated border and the tendency to central resolution with peripheral extension give it the trichophytoid appearance which accounts for the earlier mistake concerning its cause.

Aside from the common type, Sabouraud describes two others which are rare. The non-circumscribed erythematous type is red throughout, though in its later stages showing a tendency to heal in the center. The eczematoid type, however, observed in only one case of a considerable epidemic, showed a marked inflammatory aspect and an elevation of the entire lesion. This type was regarded as corresponding to the compound of eczema and trichophytosis described by English authors.

In 1910 Sabouraud[2] recognized in certain so-called eczemas of the fingers and toes other lesions due to the same organism. What would now appear to be the appropriate name for the condition is epidermophytosis with the proper adjective to denote the region involved if such qualification is deemed necessary.

The discovery of a specific organism capable of evoking a reaction which passes for an eczema is an event of importance. The question of micro-organisms in eczema, whether primary or secondary, whether fungous or bacterial, is probably by no means definitely settled.

The differential diagnosis of interdigital epidermophytosis and true eczema is made by the exclusive localization in the interdigital spaces, the callous inferior border of the lesion, the fine vesiculation of the adjacent skin, the absence of eczematous patches elsewhere, and

2. Sabouraud: Les Teignes; Sur l'existence fréquente d'un soi-disant eczéma des doigts et des orteils, du à l'epidermophyton inguinale, Ann. de dermat. et de syph., June, 1910.

Digitized by Google

the presence or antecedent history of inguinal epidermophytosis.

Cultures of the epidermophyton are made with some difficulty. The cold culture on glucose, gelatin-peptone gives a yellow growth in three weeks.

In connection with the treatment of the affection with an ointment containing 1 per cent. of chrysarobin, Sabouraud emphasizes two pertinent facts relative to the use of this drug. The first is that chrysarobin is soluble in neither petrolatum nor lanolin, though it does dissolve in lard. He therefore prescribes it in lard with directions that it be prepared hot and stirred until cool. The other point is to avoid soap in removing chrysarobin, as the action of an alkali is to increase its penetration. The removal of chrysarobin ointment, therefore, should be effected by the use of oil or lard.

The subject of sporotrichosis brings up the question of identity among several organisms. The importance of the disease makes it worth our while to review briefly certain points in its history.

Many saprophytic forms of sporotrichium have been known for a long time. The discovery of pathogenic forms is of comparatively recent date. Sporotrichosis was first described by Schenck,[3] and Hektoen and Perkins,[4] in 1898 and 1900, respectively. The two cases were considered identical and the organism was named sporothrix of Schenck. Matruchot and Ramond, without knowing of these cases, described a variety cultivated in Paris by de Beurmann and Ramond, and named it *Sporotrichium beurmanni.*

De Beurmann and Gougerot compared these two parasites in 1906 on the basis of the text of American descriptions and the accompanying illustrations, as well as specimens which Hektoen had sent them as typical of the sporothrix of Schenck. Between these two organ-

3. Schenck: Refractory Subcutaneous Abscesses Caused by a Fungus Possibly Related to the Sporotrichia, Bull. Johns Hopkins Hosp., 1898, p. 281.

4. Hektoen and Perkins: Refractory Subcutaneous Abscess Caused by Sporothrix schenckii, Jour. Exper. Med., 1900, p. 77.

Digitized by Google

isms they found differences in development, cultural appearances and biologic characters, differences sufficiently marked to justify considering them as distinct. In the years 1909 and 1910 quite a series of new cases was reported in the United States by various authors. In all accounts the parasite was called the sporothrix of Schenck.

Shortly before the publication of their book on Sporotrichosis in 1912, de Beurmann and Gougerot[5] had the opportunity of comparing cultures of recent American cases taken to them by Davis with those of the *Sporotrichium beurmanni.* As a result of this comparison they concluded that the Davis cultures are, if not identical with those of de Beurmann, at least the connecting links between the *Sporothrix schenckii* first sent to them from the early American cases and the *Sporotrichium beurmanni.*

They consider that in the circumstances three interpretations are possible:

1. The first American specimens of the *Sporothrix schenckii* represent the true type of this organism, in which case the *S. schenckii* and *S. beurmanni* are closely related but different organisms.

2. The *S. schenckii* and the *S. beurmanni* are derived from a common stock but differ to-day though related by numerous intermediaries as the specimens of Hyde and Davis.[6]

3. The original specimens of *S. schenckii* sent to de Beurmann represent a fixed and irreducible pleomorphism of the *S. schenckii,* differing from the original Schenck and the original Hektoen cultures. The *S. schenckii* is not to be judged by the first specimens. The true *S. schenckii* is represented by the Hyde-Davis type. In this case, since the de Beurmann form is prac-

5. De Beurmann and Gougerot: Les nouvelles mycoses; les sporotrichoses.

6. Hyde and Davis: Sporotrichosis in Man, Jour. Cutan. Dis., July, 1910.

Digitized by Google

tically like the Hyde-Davis form, the *S. schenckii* and the *S. beurmanni* are identical.

The practical importance of this question lies in the fact that cultural appearances play an important part in the recognition of sporotrichosis. A point much to be emphasized is the necessity of using a standard medium. On the so-called *milieu d'épreuve* of Sabouraud the sporothrix gives a definite appearance. One who gets his impressions of cultural appearances from de Beurmann and Gougerot's description would not recognize the cultures of early American cases as growths of the same organism, the one being nearly black while the other is nearly white.

Microscopically the differences are not marked between the two forms, though the short oblong forms seen in specimens made directly from secretions are to be considered as short mycelial forms rather than spores as some have described them.

Other pathogenic forms of sporotrichium have been reported, notably *Sporotrichium dori,* 1906; *S. gougeroti,* 1907; *S. asteroides* (Splendore), 1908; *S. indicum* (Castellani), 1908, and *S. jeanselmi,* 1910.

All of these are apparently in very close relation with the *S. schenckii* except the *S. dori,* which seems to show marked differences both clinically and in culture. The sole case of this form was reported by Dor in 1906. No parasite was demonstrated in smears, but cultures showed fine mycelium which branched dichotomously, as well as zooglea masses from which filaments radiated. These zooglea masses seemed to Dor to be made up of fragments of mycelium rather than spores. Cultures grew rapidly. The colonies reached their height in three days, remained isolated, were dull grayish, without aureole and scarcely elevated at all. At the end of a month they assumed a brownish tint but never became black in any portion. Clinically this one case was evidenced by large, multiple abscesses and was termed subacute. Guinea-pigs and rabbits were inoculated both

Digitized by Google

with the secretion and with cultures, negative results being obtained in each instance.

The usual forms of sporotrichosis show either localized or disseminated lesions. It must be remembered that the disease involves lymphatics, mucous membranes, eyes, ears, joints, muscles and viscera as well as the skin. The cutaneous lesions are too well known to bear repetition. Their resemblance to the lesions of syphilis, tuberculosis and glanders makes their recognition of extreme importance. The occurrence of sporotrichosis in animals has been shown by Hyde and Davis, de Beurmann and Gougerot and others.

In a botanic classification the sporothrix belongs with the *fungi imperfecti.*

Another mycologic subject about which much confusion has gathered is the relation between blastomycetic dermatitis and granuloma coccidioides of California writers. Do they represent different aspects of the same affection varying because of differences in environment, or do they stand for two distinct though related diseases? Should they be separated or classed together?

First of all, what do we mean by blastomyces? There are no less than three distinct views concerning blastomycetes. The first defines them strictly in accordance with etymologic signification, namely, budding fungi or yeasts. According to Vuillemin a blastomyces is any fungus which appears at a given time under the form of budding globules, whatever its relationship and whatever aspects it may reveal at other periods of its existence. Such a view would bring within the category of blastomycetes the organism of blastomycetic dermatitis as well as the yeasts of cancers, of rabies and of variola. The second view limits the term to the saccharomyces. The third reserves the name for fungi as yet unclassified.

De Beurmann and Gougerot dispose of all the formerly considered blastomycetes by grouping as exascoses the mycoses due to the saccharomycetes, the zymone-

Digitized by Google

mata and the endomycetes. Blastomycetes in their scheme represent simply the residue which is not amenable to classification. The zymonemata are so named because they exhibit at the same time both yeast and filamentous forms. In this group they would include both blastomycetic dermatitis and coccidioidal granuloma.

In making these two diseases identical they are simply following the custom of numerous other writers. It is a noteworthy fact, however, that granuloma coccidioides has occurred practically exclusively in California, where about twenty cases have been reported. Those who have followed these cases are, so far as I know, unanimous in the opinion that however close may be the relationship between their respective organisms, there yet remain sufficiently well-marked points of differentiation to make of each one a distinct entity. Clinically, as indicated by Hektoen, the nodules in the California disease bear a closer resemblance to the typical specific tubercle than do the nodules of blastomycetic dermatitis. There is, furthermore, a marked tendency toward the involvement of lymph-nodes in coccidioidal granuloma, while in blastomycosis this is slight. Blastomycosis also presents usually its primary focus in the skin with but slight tendency to become generalized, while in coccidioidal granuloma, though the disease may originate in the skin, there is most often generalization.

Microscopic appearances differ, according to Ophüls,[7] in that the blastomyces multiplies by budding while the coccidioidal organism multiples by endogenous sporulation. The latter is moreover a much larger body, attaining a size two or three times that of the blastomyces. In coccidioidal infection there is an absence of budding forms during its development in the tissues, though these forms are seen in blastomycetic dermatitis. There are also certain differences on artificial culture mediums. A further mark of differentiation sometimes urged is

7. Ophüls, W.: Jour. Exper. Med., vi, 443; Coccidioidal Granuloma, THE JOURNAL A. M. A., Oct. 28, 1905, p. 1291.

Digitized by Google

that blastomycetic dermatitis responds to the administration of the iodids, while coccidioidal granuloma resists them. A case of the latter recently under my care tends to deny this point.

This was the case of a man aged 28 who had lived for over two years in the San Joaquin Valley, the district in which most of these cases have originated. By occupation he was a machinist. The family history showed that an aunt on the maternal side had died of tuberculosis. The previous cutaneous history was negative. The previous general health had been good except for some cough and loss of weight for several months past. Dr. H. S. Warren of Coalinga, who referred the case, had found tubercle bacilli in the sputum.

The lesion, which began as a pimple on the left side of the nose in August, 1912, had, when I first saw it two months later, attained a size of 3 cm. in diameter, extending to the upper lip. It was circular and elevated above the surrounding skin approximately 5 mm. In color it was violaceous and in consistence boggy. It was apparently made up of an agglomeration of papules. Scattered throughout the surface were numerous minute, superficial pustules. Subjectively it was painful, tender and intolerant of any save the blandest applications. There was no evidence of scar tissue; neither was there any sign of tendency to spontaneous repair. There was no suggestion of any verrucous element. The submaxillary lymph-node on the corresponding side was markedly enlarged.

Smears from the pustules showed doubly contoured cells which I considered blastomycetes. Dr. Ophüls, of whom I sought confirmation, identified them as coccidioidal fungi. Careful examination of the sputum revealed tubercle bacilli but no fungi. The cutaneous lesions as well as the enlarged lymph-node showed marked improvement under the administration of potassium iodid, but what was clinically a laryngeal tuberculosis quickly followed the pulmonary condition and

Digitized by Google

the patient died within a few months of the first observation. Unfortunately a post-mortem was impossible.

Oidiomycosis is a term applied to a fungous disease of which only two cases have been reported: the first by Babès in 1882 as dermatomycosis discoidea exulcerans caused by the *Oidium subtile cutis,* and the second in 1910 by de Beurmann, Gougerot and Vaucher[8] due to the *Oidium cutaneum.* According to the latter observers the so-called *Oidium albicans* of thrush is not an oidium at all but belongs with the endomycetes; for the name oidiomycosis should be applied only to those affections due to the oidium defined by Linck as showing "rampant, septate mycelium of isolated filaments; simple, erect, septate conidiophores dividing into oval or cylindrical chain-like conidia."

The clinical aspect of oidiomycosis is that of an ulcerating gummatous nodule which resembles blastomycetic dermatitis, syphilis or sporotrichosis. The diagnosis is best made from cultures. On Sabouraud's medium, de Beurmann and Gougerot's case showed macroscopically the viscous glistening veil of yeasts. Microscopically they presented exclusively round, budding forms. Biologically they caused fermentation of glucose into alcohol and carbonic dioxid. From the first cultures the observers thought of saccharomyces of Busse-Buschke; later, in subcultures the colonies became godrooned or fluted, yellowish-white and resistant. Filamentous forms were added to the yeast-cells which suggested blastomycetic dermatitis. Finally subsequent transformations of the same parasite showed it fixed under exclusively filamentous forms, with all the characters of the genus oidium of Linck. Macroscopically the cultures were godrooned and even downy on potato; microscopically the oidium form was without mixture of yeast forms; biologically glucose was no longer attacked.

8. De Beurmann, Gougerot, H., and Vaucher, R.: Oidiomycose gommeuse ulcéreuse disséminée, Rev. de méd., December, 1910.

Digitized by Google

The *Oidium cutis* of Babès gave ulcerations of the skin of a rabbit and the *Oidium cutaneum,* though slightly virulent, is pathogenic for rats.

The prognosis is good and the disease yields to iodids as sporotrichosis and other mycoses.

The study of the oidium shows an organism exhibiting itself first as a yeast or blastomyces, then as one of the zymonemata of de Beurmann and Gougerot; that is, an organism showing both yeast and mycelial forms, and finally in the exclusively filamentous forms of the true oidia. It illustrates the transitions possible between the different genera of the same family. According to Gougerot it emphasizes the fact that a yeast form may be only a degraded aspect of a mycelial parasite of the genus oidium, and that the budding yeast aspect is only a non-specific morphologic aspect common to very different parasites.

If the characteristics of the mycelium as set forth by Linck are the sole criteria by which the true oidiomycoses are to be judged, then it would seem as if the organism of granuloma coccidioides was correctly named originally by Ricketts[9] when he applied to it the designation of *Oidium coccidioides.* In this case granuloma coccidioides would properly belong with the group of oidiomycoses. As we have seen there are similar though distinct forms of sporotrichosis, and also there are marked resemblances between blastomycetic dermatitis and granuloma coccidioides. The same sort of analogy exists between actinomycosis and mycetoma or Madura foot. There has been much discussion as to the relation between the organisms of the two diseases last named, the majority of writers favoring the view that each one has its own special organism, although admitting close relationship. Recent research according to Gougerot shows that these clinical units result from multiple parasites.

Mycetoma, which was first described over two hundred years ago, was first reported in America less than

9. Ricketts, H. T.: Philadelphia Med. Jour., April 27, 1901.

Digitized by Google

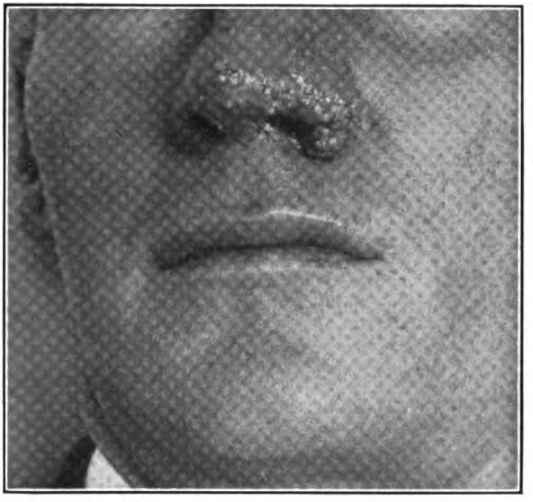

Fig. 1.—Granuloma coccidioides.

**Fig. 2.—Blastomycetic dermatitis (courtesy of Dr. E. C. Dickson).**

Digitized by Google

Digitized by Google

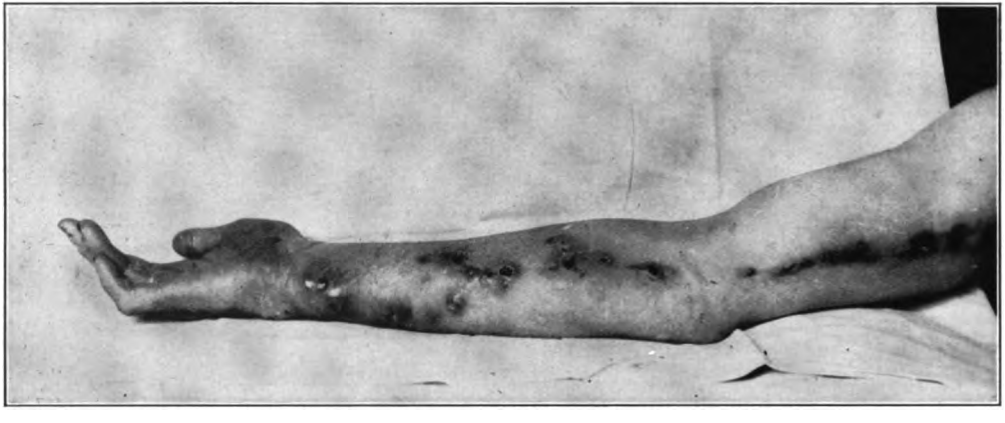

Fig. 3.—Sporotrichosis (Courtesy of Dr. John Armstrong).

Digitized by Google

Digitized by Google

twenty years ago. Sutton has recently reported from Kansas City two cases of this mycosis which makes a total of seven American cases.

Hemisporosis, due to the *Hemispora stellata,* was first described by Gougerot and Caraven in 1908; the case being a primary osteitis of the tibia simulating syphilitic periostitis or post-typhoid osteomyelitis. Two subsequent cases have been reported, one resembling a tuberculous gumma, the other a syphilitic nodule.

The consideration of the ever-increasing list of mycosic disease leads to the opinion that many new forms are yet to be revealed. Presumably many of the known forms constantly escape recognition.

One who becomes interested in the group will not fail to be struck with the necessity of a clearer classification or even the general adoption of any classification. There seems to me urgent need for dermatologists to undertake more comprehensive work along the line of cutaneous mycology.

The clinical lesson is that any subcutaneous nodule or refractory abscess about whose etiology there is the slightest uncertainty should be subjected to careful investigation to determine the presence or absence of pathogenic fungi. To avoid discrepancies of description, a standard culture-medium should be employed.[10]

I wish to express my indebtedness to Dr. Ernst A. Victors of San Francisco for many slides and cultures used in the preparation of this article. I am further indebted to Dr. E. C. Dickson of the Leland Stanford Junior University for a culture of blastomycosis.

240 Stockton Street.

---

10. In addition to the references already given, the following will be found of interest:

Castellani: Brit Jour. of Derm., November, 1911.
Brown, Philip King: Coccidioidal Granuloma, THE JOURNAL A. M. A., March 2, 1907, p. 743.
Gougerot: Gaz. des hôp., Jan. 5, 1913.
Hektoen: Systemic Blastomycosis and Coccidioidal Granuloma, THE JOURNAL A. M. A., Sept. 28, 1907, p. 1071.
Montgomery, F. H.: Cutaneous Blastomycosis, THE JOURNAL A. M. A., June 7, 1902, p. 1486.
Sutton: Mycetoma in America, THE JOURNAL A. M. A., May 3, 1913, p. 1339.
Weis: Jour. Med. Research, vol. vii, No. 3.

Digitized by Google

## ABSTRACT OF DISCUSSION

DR. RICHARD L. SUTTON, Kansas City, Mo.: The question of group classification of the various pathogenic fungi is an exceedingly interesting one, but of more theoretic than practical importance. Sporotrichosis is a comparatively common disease in the Middle West. I have seen almost a score of cases and have heard of as many more unreported instances. From the results of a bacteriologic study of the organisms recovered from the lesions in four characteristic examples of the malady, I am forced to confess that I can find no essential differences between the organism originally described by Schenck and Smith and the so-called *Sporotrichium de Beurmannia* of Gougerot. In studying fungi, even more than in studying the ordinary pus organisms, slight cultural and tinctorial differences are frequently noted, just as slightly diverse clinical manifestations usually follow infection from various strains of staphylococci. While these slight differences mean little to the majority of bacteriologists, they may form ample material for theoretical controversy. Consequently, I agree with Page, Frothingham, Lutz and Splendore and other observers that up to the present time the *Sporotrichium schenckii* (including all of the various strains, of course) is the one and only cause of sporotrichosis. The fact that the disease may be local or general, trivial or fatal, means but little from an etiologic point of view. The existence of several clinical types of blastomycosis hardly warrants our separating the organism into forty-seven different varieties and appending to each a different name.

Mycetoma is an exceedingly rare affection in this country. In all the reported cases the infecting organism has been of the yellow variety. A beautiful example of this disease was recently reported by Allison of Texas (*Texas State Jour. Med.*, October, 1912, p. 166), which I unfortunately overlooked in a statistical study of the condition in America published a few weeks ago. The fact that the causative organism apparently possesses an affinity for the tendons and tendon sheaths may account for the frequency with which the foot is attacked and may prove of value from a bacteriologic point of view.

For several years I have been of the opinion that granuloma coccidioides was an aberrant type of blastomycotic infection. Recent studies have shown that environment will account for many slight clinical, pathologic and bacteriologic differences, even in so thoroughly understood a disease as lues (I of course refer to gangosa); consequently, it is difficult for me to forego the opinion.

DR. H. E. MENAGE, New Orleans: In a case at the Charité Hospital in New Orleans about six months ago, we believed

Digitized by Google

that we found an organism identical with that of de Beurmann.

Dr. A. Ravogli, Cincinnati: In the course of my private and hospital practice I have seen perhaps nine or ten cases of blastomycosis, and at the present time I have under my care two cases of sporotrichosis. I did not make this diagnosis without seeing the parasite under the microscope and getting a culture. My recent cases were of the tuberculoid type. The parasite has peculiar oval spores that make it easily recognized. I regard sporotrichosis as a much more stubborn affection than blastomycosis, as I have seen several patients with the latter recover, which so far I cannot say of sporotrichosis. Potassium iodid does these patients no good. I have obtained my best results from liquor formaldehydi and liquor cresolis compositus, mixed together. The application of this strong solution burns the surface of the patch and produces a necrotic eschar which sloughs off and leaves a clean healing surface. I give potassium iodid in these cases, but more as a matter of custom than because I think that it helps the patient.

Dr. Ernest Dwight Chipman, San Francisco: The point which I should like to add and emphasize is that to us in California there is a distinct difference between blastomycosis and granuloma coccidioides. The latter affection is almost always apt to become generalized and extremely virulent and rapid in its course. Many of these mycotic diseases are grave if unrecognized, and the point is to make an early, thorough and complete bacteriologic examination. The taking of cultures should be insisted on in all doubtful cases. I think we should have a standard culture medium, such as the glucose-gelatin-peptone medium. If we all use a similar standard culture medium, our results will be more apt to be similar.

Dr. David Lieberthal, Chicago: Before this discussion is closed, I wish to mention that Petersen of St. Petersburg (*Archiv für Dermatologie,* 1911) calls attention to the fact that the growth of the blastomyces is inhibited at a temperature of 40 C. He therefore treated blastomycosis of the skin by applying heat of higher degrees and accomplished excellent results.

Digitized by Google

# IDIOPATHIC ATROPHY OF THE SKIN

## WITH REPORT OF A CASE *

H. G. IRVINE, M.D.
Instructor in Dermatology and Syphilis, University of Minnesota, College of Medicine and Surgery
MINNEAPOLIS

Buchwald[1] in his work of 1883 was the first to describe an authentic case of idiopathic atrophy of the skin. Previously described cases were either secondary to some other disease or were scleroderma. Kaposi[2] in 1897 was the first to suggest that these cases were not primarily an atrophy but rather a dermatitis passing into atrophy. Herxheimer and Hartmann[3] in 1902 were the first, however, to use a title suggestive of this dermatitis. They published their observations on twelve cases under the title of "Acrodermatitis chronica atrophicans."

In a monograph published in 1910, Finger and Oppenheim,[4] after an exhaustive study of all cases found in the literature as well as those seen by themselves, suggested a classification and nomenclature which if followed should serve to clear away the confusion at present found in the literature on skin atrophies.

English literature is especially weak on this subject, owing perhaps to lack of cases for observation; but many cases have been so meagerly and indefinitely

* Sections and Histologic Pathology by E. T. Bell, M.D., Department of Pathology, University of Minnesota, College of Medicine and Surgery.

1. Buchwald: Ein Fall von idiopathischer, diffuser Hautatrophie, Arch. f. Dermat. u. Syph., 1883.
2. Kaposi: Verhandl. d. Wien. dermat. Gesellsch., 1897, iii; Arch. f. Dermat. u. Syph., 1897, v, xxxix.
3. Herxheimer and Hartmann: Ueber Acrodermatitis chronica atrophicans, Arch. f. Dermat. u. Syph., 1902, lxi, 57.
4. Finger, E., and Oppenheim, M.: Die Hautatrophien, 1910.

Digitized by Google

reported that one is unable to decide whether or not many of them should be accepted as authentic. Then too, many cases reported in the United States have been cases of atrophy occurring secondarily to some specific disease such as syphilis, and some cases probably were scleroderma.[5] Leaving these out, one may safely say that cases of idiopathic atrophy are rare here.

In their classification Finger and Oppenheim exclude all cases of so-called deuteropathic or secondary atrophy. This rules out congenital and senile atrophy, striae et maculae distensae, atrophies following lupus erythematosus, leprosy, scleroderma, morphea, xeroderma, etc. Included are those cases of atrophy which cannot be accounted for by any known disease and which present, in general, histologically and clinically, a dermatitis of gradual and insidious onset followed by atrophy. The skin is loose, wrinkled and has little or no elasticity. All cases which may be included under their definition whether of atrophies occurring in circumscribed areas, atrophies listed as suggested by Herxheimer (dermatitis chronica atrophicans) or as erythromelie, or so-called diffuse idiopathic atrophies, are different in degree and not in kind. Therefore, Finger and Oppenheim offer the following classification:

1. Dermatitis atrophicans diffusa or universalis, which applies to those cases involving large areas or the entire body.

2. Dermatitis atrophicans maculosa, applying to those cases in which only small circumscribed areas are involved.

---

5. Ravogli's case reported in 1903 came to necropsy and showed a gumma of the brain. Fordyce's case in 1904 was one of syphilis, and the patient recovered under specific treatment. Finger (Die Hautatrophien und deren Verhältnis zu Sklerodermie, Wien. med. Wchnschr., 1910, No. 3, p. 165) asserts that the case reported by Taylor (Am. Arch. Dermat., 1876), was one of circumscribed scleroderma; that the case of C. S. Smith (Jour. Cutan. and G. U. Dis., 1888), was scleroderma; questions whether Duhring's case (Am. Jour. Med. Sc., 1892) was not one of morphea alone and combined with maculae atrophicae, and asserts that the case of Taylor (Jour. Cutan. and G. U. Dis., 1893) was one of *sklerodermie en plaque,* and that the case of Bronson (Jour. Cutan. and Ven. Dis., 1895), was a typical case of lupus erythematosus.

Digitized by Google

The first class can be further divided clinically into acrodermatitis atrophicans (Herxheimer), which begins on and is usually confined to the extremities, and dermatitis atrophicans, which may appear on various parts of the body. The acrodermatitis atrophicans frequently has the further characteristic that the inflammatory stage shows not only a redness but even a marked swelling and infiltration.

As an example of dermatitis atrophicans diffusa the following case is submitted:

REPORT OF CASE

*History.*—G. B., widower, aged 61, with no occupation at present, has been a carpenter and a blacksmith. The father died at the age of 55 and the mother at 50, from unknown causes. The patient has four brothers, of whom two died in childhood, and two are living and well, and three sisters, two of whom are dead and one is living and well. The patient was born in Austria and has had no illness except that he asserts that he had syphilis; but the history is questionable. He took practically no treatment, and now has no symptoms and a negative Wassermann reaction.

*Present Illness.*—This dates back about twenty-five years, starting with redness and swelling of the skin of the dorsum of the left foot and the back of the right hand; then the left hand was involved and last the right foot. The swelling present in the skin of the feet and legs is variable, being sometimes better and sometimes worse. The subjective symptoms have varied; occasionally the patient has a great deal of burning and itching, and again none at all. The extension of the condition over the extremities onto the trunk has been slow but gradually progressive.

*Examination.*—The patient is of average size and fairly well nourished; the hair and nails are unaffected. The reflexes are normal. The thyroid gland is normal in size; the inguinal lymph-nodes are palpable but not enlarged. Mucous membranes are negative. The urine is a light straw color, clear, specific gravity 1.018, and neither albumin nor sugar is present. The patient has complained at times of frequent urination of good-sized amounts, even getting up several times at night; but examination was negative and no cause for this condition could be found. Examination of internal organs is negative. The skin affection is roughly symmetrical and extends from the backs of the feet to Poupart's ligaments anteriorly and to the lumbar region posteriorly, from the wrists over the arms and onto the shoulders (Fig. 1). The junction of normal

Digitized by Google

skin with the diseased part on the feet is sharply marked by an area from 1 to 1½ inches wide which extends along the sides of feet about an inch above the soles, and passes over the bases of the toes. This area is distinctly bluish-red and edematous, is soft and shows numerous ramifying dilated vessels; its margin is irregularly scalloped; below is normal skin; above, the skin is more of a clear pink, is hard, tense and edematous and has few wrinkles; in many places lamellar scales are seen. This swollen condition extends upward about half way to the knees anteriorly but not so high posteriorly (Fig. 2); it gradually fades or merges into more yellowish-pink skin with no edema, much decreased in thickness, of soft, silky appearance and with fine wrinkles, giving a crumpled cigarette-paper appearance. With the exception of an edematous plaque over the knees this atrophic condition extends to Poupart's ligament in front and to the lumbar region behind.

The skin of the genitals is not affected, which is characteristic. The scleroderma-like condition of the lower legs has been present in about one-third of the cases according to Finger and Oppenheim.[6] Through the atrophic skin the vessels show plainly as a network of whipcords. Where the tense edematous skin merges into the atrophic are many small areas with lamellar scales, on removal of which a depression is left that is white and almost scar-like (Fig. 2). Upward these appear to grow more numerous and smaller until gradually the diffuse atrophy appears, and passing downward these areas are larger, fewer and more separated until the skin is all tense and smooth except for a few scaly places around the ankles. The color can be pressed out of this edematous skin, but it does not pit; it can be folded some, not having the hardness of a true scleroderma, and it does not appear to be bound down to the underlying tissues. The skin is easily bruised and at times gives the patient considerable trouble with burning and itching.

On the posterior surface of the left thigh are three groups of rather round raised nodules. These groups are in a line running up and down the leg and separated about 2 inches. It appears that there was originally a raised plaque for each group, and that the formation of furrows running in various directions produced the nodular appearance (Fig. 3). These nodules are raised sharply from the surrounding atrophic skin, are smooth and of a very hard fibrous consistency, and the color is darker and more brownish than the adjacent skin. Below these groups are two or three small, round, smooth white areas which look as though they might have followed the disappearance of other nodules. These lesions made their appearance, according to the patient, about a year ago, and are

6. Finger and Oppenheim: Die Hautatrophien, 1910, p. 24.

Digitized by Google

painless. Similar lesions were first described by Oppenheim and occurred in one of his patients on the extensor surface of the elbow and knee.[7] Noble and Rona have also observed these fibroma-like lesions.

The atrophy begins on the back of the right hand where the edge is not well marked, and passes up the arm onto the shoulder. On the left, the hand is not involved, the affection starting at the wrist where the color is bluish-red and continuing upward as on the right. The margins on the shoulders are marked by numbers of dilated vessels. On the upper extremities the skin is very thin, soft and wrinkled, and the vessels stand out very prominently. On the flexor surfaces of the forearms are seen at times fine bran-like scales.

Sensation in the thin skin seems about normal both to heat and cold and to touch, but there is some difficulty in distinguishing heat and cold in the infiltrated skin of the lower legs.

*Histologic Examination.*—For microscopic examination three small pieces of skin were removed, one from the back just above the buttock, one through one of the nodules on the thigh and one from the anterior surface of the lower part of the leg.

Sections from the first specimen show the malpighian layer of the epidermis much reduced in thickness (Fig. 5), but the stratum corneum somewhat increased. The papillae are entirely obliterated, making the line of contact between epidermis and corium almost a straight line. In the corium and subjacent subcutaneous tissue is a marked infiltration of mononuclear leukocytes. The high magnification shows many plasma cells. The elastic tissue is considerably reduced in quantity, but a number of fine fibers are still to be seen. In some portions of this section no elastic fibers are seen. No adipose tissue is present.

The skin alongside the fibrous nodule shows quite similar changes (Fig. 10), the cellular infiltration being much less and occurring only in small patches. The reduction of elastic fibers is more marked (Fig. 10); adipose tissue is absent. The nodule itself shows a structure corresponding to hard fibromas (which corresponds to the findings of Oppenheim), being fairly well-circumscribed and readily separated from the underlying tissues. It consists of fibrous tissue, rounded underneath but spreading out under the skin above. No elastic tissue is present.

The specimen from the lower leg shows the epidermis practically normal in appearance. There is a slight increase

7. Oppenheim, M.: Verhandlungen der 79 Vers. deutscher Naturforscher und Aerzte, Dresden, September, 1907; also die Hautatrophien, p. 26.

Digitized by Google

Fig. 1.—Extent of diseased process, up leg over crest of ilium, to *A*; up arm onto shoulder to *B*. Note fine wrinkling of skin.

Fig. 2.—Tense edematous skin of lower leg merging into thin atrophic skin. At *A* are depressed scar-like areas where heavy lamellar scales were removed

Digitized by Google

Digitized by Google

Fig. 3.—Nearly actual-size appearance of nodules on posterior aspect of left thigh. Fine crumpled tissue-paper appearance is well shown.

Fig. 4.—Thin wrinkled skin of arm with vessels showing prominently.

Digitized by Google

Digitized by Google

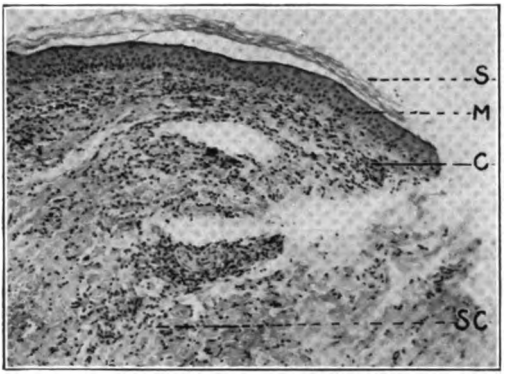


Fig. 5.—Section of skin from left upper gluteal region. Hematoxylin and eosin. Note the thinning of the malpignian layer, the lymphocytic infiltration of the corium and subjacent subcutaneous tissue, the absence of adipose tissue, the absence of papillae, and the moderate hyperkeratosis. *S*, stratum corneum; *M*. stratum malpighii; *C*, corium; *Sc*, subcutaneous tissue.

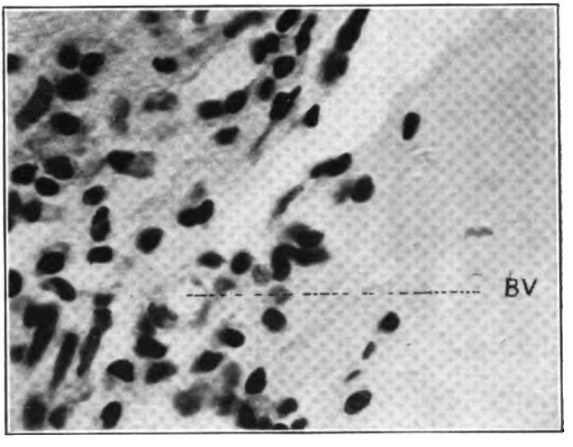


Fig. 6.—Area from the corium, from the section shown in Figure 5, under high magnification. Hematoxylin and eosin. Note the infiltration of lymphocytes and plasma cells by small blood-vessel.

Digitized by Google

Digitized by Google

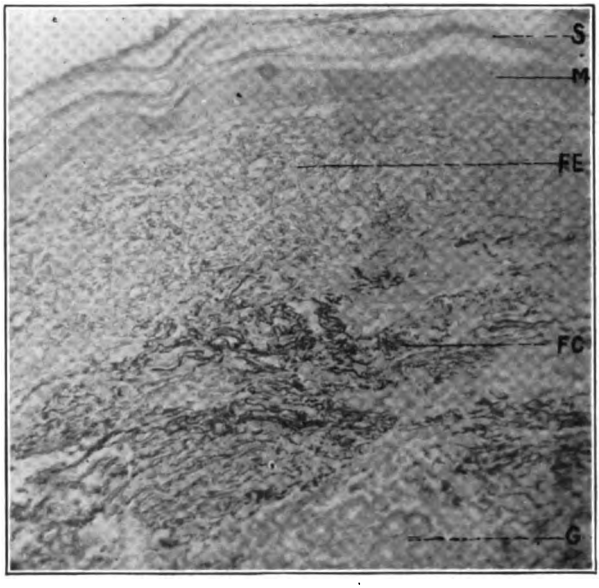


Fig. 7.—Section from the same specimen as the one shown in Figure 5. Weigert's elastic-tissue stain. There is a considerable reduction in the elastic tissue of the corium, although a large number of fine fibers are still to be seen. Elastic fibers, black; *S*, stratum corneum; *M*, stratum malpighii; *fe*, zone containing fine elastic fibers; *fc*, zone containing coarse elastic fibers; *g*, sweat-gland.

Digitized by Google

Digitized by Google

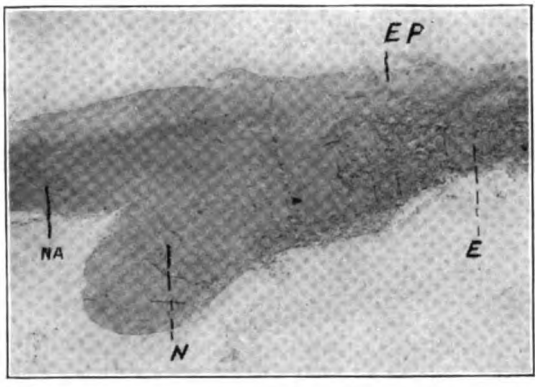


**Fig.** 8.—Section through one of the nodules on the back **of the thigh,** shown in Figure 3. Low magnification. Weigert's **elastic-tissue** stain. Nodule consists of dense fibrous tissue. Elastic **tissue shown** on the right; none in the nodule. *N,* nodule proper; ***Na,*** **continuation** of nodule under epidermis; *ep,* epidermis; *e,* **elastic fibers.**

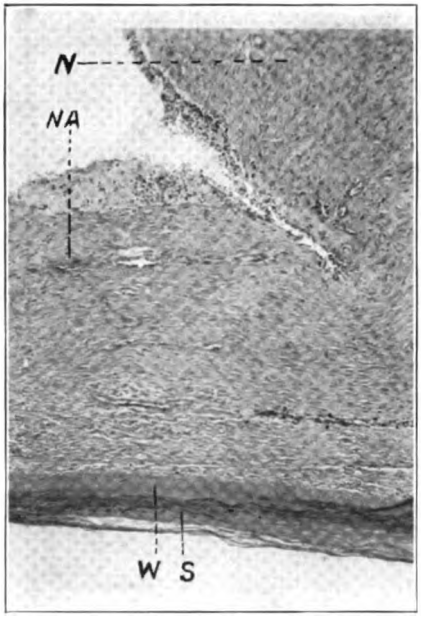


**Fig. 9.—Part of nodule shown in Figure 8, under higher magnification. It consists of dense fibrous tissue.** *N,* **nodule corneum;** *N,* **stratum malpighii.**

Digitized by Google

Digitized by Google

**Fig. 10.—Section from the skin of back of thigh, taken near the nodule shown in Figures 8 and 9. Weigert's elastic-tissue stain. Elastic fibers back. There is a marked reduction of elastic tissue. Epidermis resembles that shown in Figure 5; *S*, stratum corneum (torn); *M*, stratum malpighii; *e*, area containing sweat-gland.**

Digitized by Google

Digitized by Google

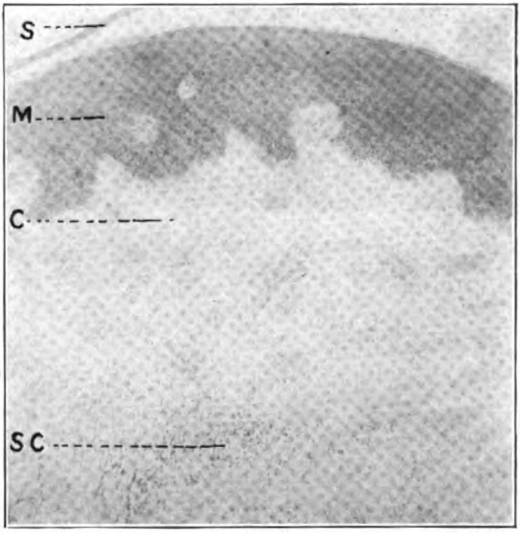


**Fig. 11.—Section of the scleroderma-like area on front of lower third of leg. See Figure 2. Hematoxylin and eosin. There is absence of adipose tissue, and a slight lymphocytic infiltration. Epidermis practically unchanged. *S*, stratum corneum (torn loose); *M*. stratum malpighii; *C*, corium; *Sc*, subcutaneous tissue.**

Digitized by Google

Digitized by Google

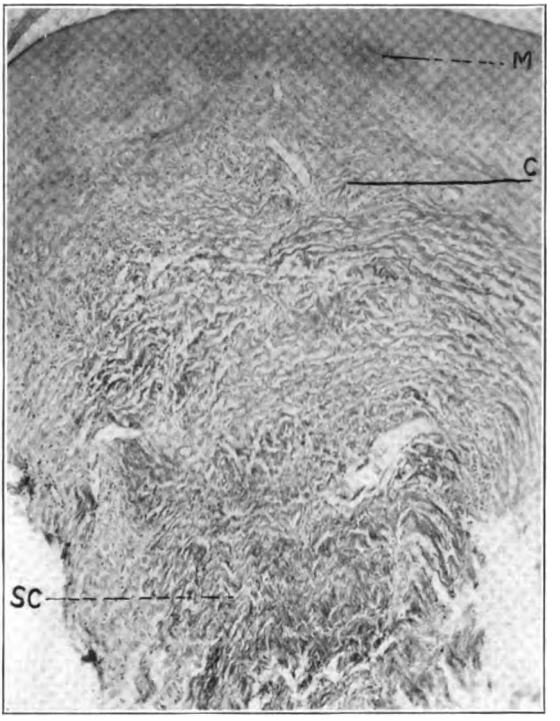


Fig. 12.—Section from the same specimen shown in Figure 11. Hoehl's orcein stain. No elastic fibers shown in the photograph. (A few very faintly stained elastic fibers can be seen in the deep part of the section by close examination.) *M*, stratum malpighii; *C*, corium; *Sc.*, subcutaneous tissue.

Digitized by Google

Digitized by Google

in lymphocytes in the connective tissue. Elastic tissue is almost entirely absent, no fibers staining with normal intensity, but a few faintly staining fibers are seen in some portions of the section.

ETIOLOGY

Many cases of idiopathic atrophy have been reported in which the etiology was quite plain. For instance, the case reported by Ravogli[8] came to necropsy and showed a gumma of the central nervous system, and in that reported by Fordyce[9] there were plain evidences of syphilis, and an improvement of all symptoms followed the use of antisyphilitics. Later writers, however, both here and abroad, are inclined now not to consider these cases as true cases of idiopathic atrophy. Sutton and Kanoky[10] state that evidence occasionally can be deduced to warrant the recognition of a new and distinct disease, and in consequence many cases that formerly were classed among the idiopathic atrophies can now definitely be placed in groups of their own. Finger, Oppenheim, Arndt and many others are in accord with this view; consequently syphilis and diseases of the nervous system need not enter into a discussion of the etiology.

In considering the etiology a hypothesis must be advanced which will fit all the various classes of atrophy which differ in form and not in kind, and one which will constantly account for that which is histologically the typical finding, namely, the loss of elastic fibers. Other findings may vary in different cases and in different parts of the same case, but always we have the loss of elastic fibers.

Trauma was first considered as a causative factor, and Ehrmann attempted to prove the traumatic infectious nature of the malady, advancing as arguments the fact

8. Ravogli, A.: A Case of Progressive Idiopathic Atrophy of the Skin, THE JOURNAL A. M. A., Jan. 10, 1903, p. 73.

9. Fordyce: Symmetrical Cutaneous Atrophy with the Coincidence of Syphilis of the Skin and Nervous System, Jour. Cutan. Dis., 1904, p. 155.

10. Sutton, R. L., and Kanoky, J. P.: A Comparative Study of Acrodermatitis Chronica Atrophicans and Diffuse Scleroderma, with Associated Morphea Atrophica, Jour. Cutan. Dis., 1909, xxvii, 556.

Digitized by Google

that most cases occurred in those whose work especially exposes them to trauma and infection, such as field-hands, fishermen and washerwomen; that the beginning place was frequently in the skin where bones come close to the surface; and further he found histologically in very early cases a perilymph angitis. This view undoubtedly fits many cases and explains the inflammatory stage, but it does not account for the atrophy with the loss of elastic tissue. Further, many cases are recorded as occurring in office workers, salespeople and others whose work does not expose them to trauma or to infection. This hypothesis could not possibly fit those cases of diffuse dermatitis atrophicans that occur on protected areas or those of macular dermatitis occurring on various locations.

Trauma then can explain only the beginning of the cases in which there might be an injury and an accompanying infection, and a predisposition would be necessary to account for the atrophy of the elastic elements.

Many men have inclined toward atrophoneurosis. Neumann called it a trophoneurotic inflammatory process. Zinsser came to this conclusion, describing a case as a neuritic atrophy on account of the symmetrical distribution. Blaschko in his second case reported an angioneurosis with trophic disturbances and Heller found histologically atrophic nerves. In general, however, it does not appear that a direct connection with disturbances of the nervous system is present. Few cases show changes in the sensibilities either qualitative or quantitative. Reaction to cold, heat and pain are usually quite normal, as are also the reflexes. Muscles and bones show no atrophy as might be expected with a central trophic disturbance. Changes in the hair, nails and glands are rarely seen as would be expected.

Cases have been observed by Jadassohn, Heuss, Wechselmann and Bettman in tuberculous subjects, and this might be considered as a factor especially as a number of authors, including Orth, Federmann and Lubarsch,

Digitized by Google

declare that the tubercle bacillus and its toxin has an elective action on the elastic tissue. Wechsberg found by animal experiment that the toxin was directly injurious to elastic elements. Whether this effect was mechanical or chemical remains unsettled, but it is probable that both have an effect. Meffert, studying experimentally the influence of the exudate and transudate, found histologically little difference, but asserted that the greatest decrease in elastic elements was caused not by exudative processes but by connective-tissue increase.

With dermatitis atrophicans complete loss of elastic fibers may be found without exudation or proliferation.

Oppenheim in studying histologically the organs and skin from cases of various forms of tuberculosis, could find no loss of elastic elements except when an exudate was present or when scars were found. Experimentally he studied the effect of tuberculin and other bacterial toxins on the aorta, skin and lungs, and could find no change in the elastic tissue. Experimental injections into animals also gave negative results. He therefore came to the conclusion that a specific action of the tubercle bacillus and its toxin on elastic tissue could not be proved; without a cellular infiltration no injury was observed. According to his results then, tuberculosis cannot be the cause of dermatitis atrophicans in any case in which there is loss of elastic fibers independently of infiltration.

An interesting experiment was tried in one of Finger's cases. Serum from a patient with dermatitis atrophicans maculosa was injected into the healthy skin of the thigh and also an injection of normal saline was made. The skin where the serum was injected became atrophic, but where the saline was injected no change took place. This would suggest that there might be some element in the serum which had the property of attacking the elastic fibers.

An etiologic factor which seems to play a rôle in the history of a large number of cases is the influence of

Digitized by Google

temperature and weather, frosting, freezing, chilling, wetting and exposure to heat, as in cases of Columbini, Pospelow, Heller, Nikulin, Herxheimer and Hartmann and in some of Finger and Oppenheim's cases. My case was in a blacksmith for many years exposed to the heat of the forge. Nothing definite can be asserted for this, merely that it apparently bears some relation.

The fact that some cases of Roentgen dermatitis have resulted in scleroderma-like changes and sometimes give a similar picture to idiopathic atrophy with erythema and venous stasis, with histologically, according to O. Salomon and G. Noble, infiltration around the vessels, flattening of papillae and decrease of elastic tissue, might be regarded as significant.

One must also remember that xeroderma pigmentosa starts as an erythema solare and that in the atrophic stage it shows degeneration of elastic and connective tissues. These facts suggest that light may bear a certain relation to the atrophy.

Finger and Oppenheim after their studies and observations came to no definite conclusion as to the etiology, but offer three hypotheses which cover all classes of the idiopathic atrophies:

1. An internal causative agent acting on a predisposed skin, accounting for the macular and diffuse dermatitis atrophicans.

2. An external causative agent acting on a predisposed skin, accounting for the acrodermatitis atrophicans. Here mechanical, chemical and thermal injuries come into regard.

3. An external causative agent, through intensive and length of time of applications, can of itself cause atrophic conditions, as with the Roentgen-ray.

### DIAGNOSIS

If a classification such as suggested by Finger and Oppenheim is accepted, much confusion is at once done away with and there remains but one disease with which dermatitis atrophicans may be confused—scleroderma.

Digitized by Google

Most authors agree that the differential diagnosis is usually easy, but I must confess after going over the literature that unless some one's work is taken as a standard one could put a given case in either class. For instance, Herxheimer in 1905 went into a detailed differentiation of scleroderma from acrodermatitis atrophicans, and according to him there could be confusion only in the atrophic stage; the early stage both histologically and clinically was easily differentiated. On the other hand, Arndt[11] in 1909 in reporting a case held that confusion can occur only in the early stage. Finger and Oppenheim also maintain that the diagnosis is harder in the initial stage than in the atrophic. In the infiltrated stage scleroderma shows a harder infiltration, the color is whiter than with dermatitis atrophicans and the skin is bound down to underlying tissues. Histologically scleroderma shows a marked increase in the collagenous fibers and not so much infiltration. Both may show loss of elastic fibers and atrophy of papillae. In the early stage it seems that there will be some cases which are atypical which will be hard to classify. Later in the condition two good points are suggested, one by Arndt, who believes that the most typical characteristic of the dermatitis atrophicans is its tendency to start on the extremities and progress toward the center of the body, while scleroderma shows no tendency to any regular localization, the other by Finger and Oppenheim who suggest that the best single diagnostic point is the so-called anetodermia, that is, the wrinkled or literally the sleeping skin. These authors[12] say that scleroderma always passes into a smooth scar-like atrophy and that any case which had been diagnosed scleroderma in the infiltrated stage which shows later wrinkled atrophy is not a scleroderma but an idiopathic atrophy.

11. Arndt, G.: Acrodermatitis chronica, atrophicans und Zirkumscripte Sklerodermie, Berlin. Med. Wchnschr., 1909, xxviii, 1308.
12. Finger, E., and Oppenheim, M.: Die Hautatrophien, p. 125.

Digitized by Google

### PROGNOSIS

The prognosis in so far as *restitutio in integrum* is concerned is bad although two cases have been reported with recovery, one by F. J. Pick[13] and one by Finger and Oppenheim.[14]

### THERAPY

Therapy is symptomatic and palliative. Improvement in the inflammatory stage may follow warm baths, galvanization or massage. My patient does not like heat either moist or dry, saying that it causes intolerable burning. He has been relieved of the itching and states that he feels more comfortable after the use of the faradic current and emollient salves; over the thin atrophic skin he has absolutely no symptoms and complains only of the legs and feet where infiltration is present. The dryness of the atrophic skin can be relieved by indifferent emollient salves. Internally tonics such as iron and arsenic are suggested to improve the general health.

601 Syndicate Building.

### ABSTRACT OF DISCUSSION

DR. RICHARD L. SUTTON, Kansas City, Mo.: With the exception of the tumors on the thigh, the case here presented closely resembles one described by Bronson in 1892. Much of our earlier knowledge of this condition we owe to Pick of Prague, who first described the disorder as *érythromélie*, in 1888. I am of the opinion that in dealing with a case of this kind we are often too prone to try to make the case fit the disease instead of the disease the case. In 1905, Herxheimer and later, in 1908, Herxheimer and Hartmann described under the title of "acrodermatitis chronica atrophicans," a series of cases which presented, in varying degree, inflammatory manifestations followed by an atrophy of the affected skin resembling "crumpled cigarette-paper." While some of these cases proved acceptable under the title suggested, others did not. In 1910, I had an opportunity to study and report two cases, both occurring in the practice of my associate, Dr. J. P. Kanoky. One was clinically indistinguishable from a typical example of the so-called "acrodermatitis chronica

13. Pick, F. J.: Ueber Erythromelie, Arch. f. Dermat. und Syph., Festschrift gew. M., Kaposi, 1900.
14. Finger, E., and Oppenheim, M.: Die Hautatrophien, p. 43.

Digitized by Google

atrophicans" of Herxheimer and Hartmann; the other was a mixed case of scleroderma and morphea atrophica. Histologically, the two cases were practically identical; consequently, I expressed the belief that while the gentleman from Frankfort may have been describing a new clinical and pathologic entity, the example of "acrodermatitis chronica atrophicans" studied by me was not a new disorder at all, but atrophic scleroderma. Later, my findings were verified by one of Unna's students, in Hamburg. In a third communication, Herxheimer, in collaboration with Schmidt, acknowledges that the two conditions are frequently indistinguishable.

Dr. Irvine places great stress on the decrease or absence of elastic tissue in the affected areas; in fact, he apparently agrees with Finger and Oppenheim in their assertion that this feature is pathognomonic of the disorder. Charles J. White, D. W. Montgomery and others have shown that the elastic fibers are diminished to a greater or lesser extent in a large number of cutaneous disorders; consequently, I fear that the conclusions of the men quoted by Dr. Irvine have rather an insecure foundation. I know of only two diseases in which the partial or complete absence of elastic tissue is probably a characteristic feature: epidermidolysis bullosa (the epidermolysis bullosa of Kobner) and angiokeratoma (Mibelli).

Dr. M. L. Heidingsfeld, Cincinnati: Dr. Irvine's patient immediately impressed me as being a well-defined case of erythromelia. The thin, wrinkled, parchment-like character of the affected areas, purplish-red discoloration, superficial telangiectases and symmetrical distribution over knees and elbows are absolutely typical. I think that the nodules over the legs are of secondary character, not relative to the affection. Erythromelia is a distinct entity, and a tendency to group this with such affections as scleroderma, acrodermatitis and lichen sclerosus is confusing and unnecessary. I regret to note the same tendency by some authors to group such affections as psoriasis, lichen planus and parakeratosis variegata in a similar manner. All these affections are distinct entities and failure to recognize individual types lies with us and not with the affection.

Dr. William A. Pusey, Chicago: I had the opportunity of watching throughout its course a case which presented the terminal stages of practically the same affection which we have here. There were, when I first saw the case, areas of pseudosclerosis, with a distinct inflammatory element in the lesions. Later there was atrophy, such as is seen in this case; most interesting of all, I saw the patient a year later with gummata. I put this case and mine into the same class with those of Bronson and Fordyce. Until the appearance of the gummata on the legs, I had not suspected an association of the condition with lues. The process, to my mind, is an

Digitized by Google

endarteritis of the superficial vessels, with subsequent atrophy, and it is due to various causes, of which lues is probably the most frequent.

I was glad to hear what Dr. Sutton had to say about the elastic fibers. Following Dr. Charles J. White's paper, in which he showed that destruction of the elastic tissue is one of the common changes in many processes in the skin, I have systematically examined it in all sorts of skin lesions, and I have found with White that it is a tissue element of great sensitiveness, the disappearance of which in skin lesions is so frequent that it can have little diagnostic significance.

Dr. H. G. Irvine, Minneapolis: In regard to the loss of elastic fibers, I did not wish to convey the idea that that was pathognomonic, but that it was the most constant finding, and in searching for the etiology of this condition, Oppenheim and Finger tried to learn the cause of this loss of the elastic tissue. That was the one constant finding; the other findings varied.

Digitized by Google

# MYCOSIS FUNGOIDES FOLLOWING PSORIASIS

HOWARD FOX, M.D.
NEW YORK

There are few diseases primarily affecting the skin which can appear in so many different forms as mycosis fungoides, and which, in the early stages may prove so difficult to recognize. It is also true that there are few diseases of the skin which have been studied so thoroughly from a clinical and pathologic standpoint. In spite of this we are still ignorant as to the cause and real nature of this affection. On account of some interesting features the following case seems worthy of being placed on record.

*History.*—September, 1912: The patient, G. L. S., was a man aged 47, born in the United States, an insurance agent. He was married and was the father of two apparently healthy children. An aunt was said to have suffered from psoriasis during her entire life. The patient had suffered from the usual diseases of childhood.

At the age of 20, according to his statement, the patient first noticed an eruption on the elbows consisting of "thick silvery white scales." A few years later the scalp, eyebrows and legs became affected. The eruption persisted, with partial intermissions, every summer and showed no particular change until April, 1902, when it became generalized. A positive diagnosis of psoriasis of the nummular type was made at that time by Dr. George T. Jackson, who was seen in consultation. The same diagnosis was made by his family physician, Dr. J. Gardner Smith, who had previously treated him. Following the local application of ichthyol and chrysarobin the eruption disappeared completely. It again became rather severe two years later.

In 1905, the following year, an eruption of a different character appeared, for which the patient consulted Dr. Jerome Kingsbury. The latter made a positive diagnosis of syphilis,

Digitized by Google

the patient presenting a generalized ulcerating, pustular eruption, alopecia and angina. He was treated by inunctions and internal administrations of mercury for four months, the eruption nearly disappearing during this time. Recent Wassermann reactions, however, made by me and also at the German Hospital, proved to be negative.

In January, 1906, the patient was seen by my father, Dr. George Henry Fox, who again found a typical eruption of psoriasis. His notes contain the statement that the patient "now has silvery rounded patches of various sizes on scalp, trunk and extremities." Under tonic treatment and the local use of chrysarobin the psoriasis again disappeared, and the patient remained apparently well for a year when, according to his statement, the psoriatic patches again appeared. They remained until two years ago, when the character of the eruption began to change. According to the patient's intelligent description the "scaly lesions seemed to be replaced by smooth pigmented masses which gradually became elevated."

During the past two years, in which time the new type of eruption has been present, the patient has become gradually weaker and has lost flesh and strength. He states that the present eruption has never caused any subjective symptoms whatever.

*Examination and Course.*—When examined by me in August, 1912, the patient was rather delicate in appearance and weighed about 140 pounds. He then presented an eruption consisting of a large number of grouped macules and more or less elevated nodules of a dull reddish color. The eruption was profuse and involved principally the neck, arms, trunk and thighs. The majority of the lesions were not elevated and showed little or no infiltration. A few of them, especially a patch on the side of the neck, were in the beginning stage of tumor formation. There was no scaling, ulceration or evidence of scratching. A number of the more elevated lesions had become flattened under Roentgen-ray treatment.

In the fall of 1912 the patient was shown before the Manhattan Dermatological Society, where the diagnosis of mycosis fungoides was accepted without question.

An examination of the urine showed nothing abnormal. A blood examination showed 4,896,000 red cells, 7,000 leukocytes and 85 per cent. of hemoglobin. A differential count gave 74 per cent. of polynuclear leukocytes, 13 per cent. of small leukocytes, 5 per cent. of large lymphocytes and 8 per cent. eosinophils. A von Pirquet test was negative. Examination of the chest showed an infiltration at the apex of the right lung. There was some cough but no expectoration. Nothing abnormal could be detected by palpation of the abdomen. The heart was apparently normal.

Digitized by Google

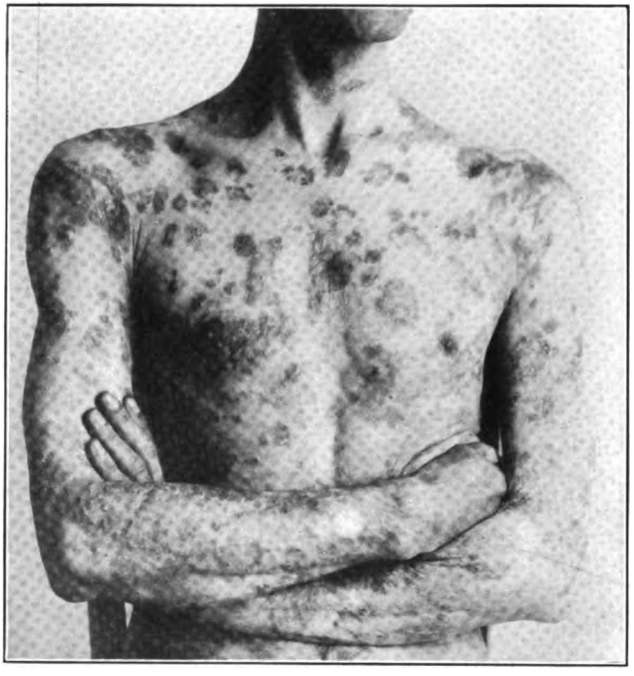

Fig. 1.—Mycosis fungoides in so-called lichenoid stage, or stage of flat infiltration.

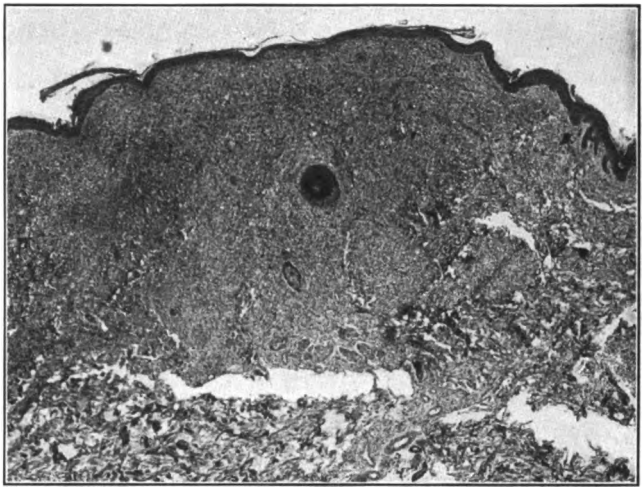

Fig. 2.—Mycosis fungoides showing infiltration of papillary and subpapillary layers of the corium.

Digitized by Google

Digitized by Google

In November, 1912, while at the German Hospital, the patient developed a lobar pneumonia, from which he made a good recovery. He was later discharged from the hospital showing improvement in the eruption as a result of Roentgen-ray treatment. He was then lost to further observation.

*Histologic Examination.*—This was kindly made by Dr. Walter J. Heimann and showed the following:

Section of the skin from thigh. Eosinhemotoxylin stain. Low-power, Zeiss objective A, ocular 4: The section contains both normal and abnormal tissue, the latter lying between two areas of the former. In the diseased portion, changes exist in both the epidermis and the cutis. The epidermis is stretched into a prevailingly straight, but occasionally wavy line, corresponding to the shape of the altered papillary body, the outlines of which have been lost, for the lesion represents an elevated papule. The changes in the cutis consist of an infiltration corresponding in breadth to the changed epidermis. In depth it includes the papillary and subpapillary layers but not the deeper stratum of the corium. It is sharply limited below.

"High power. Dry system, apochromatic. Objective 3 mm. Ocular 8: The epidermis is thin, consisting of a columnar, an atrophied malpighian, a thin granular layer and an excessively hyperkeratotic stratum corneum. The malpighian cells, arranged in layers from three to five deep, take the stain with varying intensity. The nucleus at times is shriveled and surrounded by a clear zone which, in turn, is sharply demarcated by a distinct cell-membrane. Such cells are spherical and lie singly or in groups (Unna's ballooning degeneration). Epithelial bridges are not to be found.

The infiltration consists of four elements, vascular, cellular, collagenous and, finally, a peculiar reticulum. The vessels are increased in number, but are small. They are engorged, and their endothelial cells are slightly swollen and have blurred nuclei. The walls of the arterioles are not thickened; the lymphatics are somewhat dilated. A distinct group of minute vessels lies immediately under the epidermis. About the coil-glands and hair follicles where there is no infiltration, the vessels are a little dilated, and there is a slight perivascular inflammation. The cells found in the infiltration are mainly of the round type, uniform in shape, size and staining intensity, with nuclei filling out the entire body. A few epithelioid cells and fibroblasts are present, but have no definite arrangement with reference to the round cells. Neither plasma, mast eosinophil nor giant cells could be found. The connective tissue, distributed throughout the infiltration, is fairly well stained, although in places it is clearly undergoing degeneration. The reticulated appear-

Digitized by Google

ance uniformly present consists of round or fusiform spaces corresponding either to degenerated connective-tissue elements or to degenerated round cells in which the nucleus is absent, or but faintly stained. The entire infiltration thus has the appearance of a mesh-work containing normal and degenerating cells, vessels and connective tissue.

Unfortunately as only the eosin-hematoxylin section was preserved the elastic tissue and finer connective tissue changes could not be studied. All of the characteristics enumerated above, however, speak for the histologic picture of granuloma fungoides."

To summarize, my patient had suffered for the greater part of twenty-five years from an eruption that was unquestionably psoriatic from a clinical point of view. This continued until two years ago when the eruption changed in character and finally proved to be without doubt a mycosis fungoides.

The eruption in this case failed to show any of the premycotic manifestations (erythematous stage of Bazin, eczematous stage of Kaposi) unless it might possibly be thought that the psoriasis was the initial manifestation of the disease. It may simply be said that the psoriasis was absolutely typical and that a microscopic examination would have seemed entirely superfluous. The manifestations of mycosis fungoides in my case properly belong in the so-called second stage of the disease (lichenoid of Bazin, flat infiltration of Köbner) and in the third stage of tumor formation.

A study of the literature of mycosis fungoides shows that the earliest manifestations may vary greatly in appearance. While the great majority of the earliest cutaneous lesions are of the eczematous or erythemato-urticarial type, some of them are certainly psoriasiform in appearance even if not actually psoriatic. Doubtless some of the premycotic eruptions that have been regarded as psoriasis would not have been so considered by expert dermatologists.

In collecting a series of 166 case reports of mycosis fungoides (98 men, 68 women, with an average age of 48), I have found the following references in which

Digitized by Google

premycotic eruptions were stated to have simulated more or less closely the lesions of psoriasis. Thus, Stowers[1] remarks that his case had been mistaken at different times for eczema, leprosy, lupus and psoriasis. Allgeyer[2] writes that in his case the desquamation was so abundant at one time that it might have been compared to a case of aggravated psoriasis. Whitfield[3] writes concerning his patient that it "at first glance somewhat resembled psoriasis, as it is a red rash, throwing off thick and rather silvery scales and arranged in the gyrate manner, so common in this disease. On closer inspection it is found, however, that these circles and curves are entirely made up of small nodules." Wolters[4] says concerning one of his cases: "The clinical picture which the patient presented at the first examination resembled most closely a psoriasis. Only after the scales had been removed by baths, zinc oxid and green soap, did I succeed in recognizing the real condition." Werther[5] remarks that one of his cases presented a patch that had previously been considered to be psoriasis by another physician, and Stopford Taylor[6] made a provisional diagnosis in his case, of pityriasis rubra following a psoriasis or seborrheic eczema. Biddle[7] remarks that a patient of his "had been treated for two years by one physician and another for psoriasis" but adds, "The tumor stage had already set in so that I knew the disease could not be psoriasis." He then describes the points in which the eruption differed from psoriasis, a distinction which had probably not been appreciated by the other physicians who had treated the patient. In

1. Stowers, J. H.: Mycosis Fungoides, Brit. Jour. Dermat., 1903, xv, 47.
2. Allgeyer, V.: Micosi fungoide e leucocitosi linfatica, Arch. p. le sc. med., 1901, xxv, 235.
3. Whitfield, A.: A Case of Mycosis Fungoides, Brit. Jour. Dermat., 1898, x, 153.
4. Wolters, M.: Mycosis Fungoides, Stuttgart, 1899.
5. Werther: Zwei Fälle von Mykosis Fungoides, München. med. Wchnschr., 1906, liii, 1546.
6. Taylor, G. Stopford: A Case of Mycosis Fungoides, Brit. Med. Jour., 1894, ii, 693.
7. Biddle, A. P.: A Study of Mycosis Fungoides, Physician and Surg., 1900, xxii, 7.

Digitized by Google

a case of Völckers[8] the diagnosis at first lay between syphilis and psoriasis. There was no history of syphilis and there were no objective signs of this disease. Chrysarobin was given but without any noteworthy improvement. When seen three years later the type of eruption had changed and the true diagnosis was apparent. Mannino[9] reports a case of mycosis fungoides in which, during the course of the disease (tumor stage), a diffuse psoriasis appeared from which the patient was relieved after a long continued treatment with Fowler's solution. Von Zumbusch[10] reports a case in which an eruption which had been thought to be psoriasis had appeared eight years previously and had disappeared after chrysarobin therapy. A second attack had also occurred two years before. Later the eruption was mistaken for "lichen ruber" and finally the proper diagnosis of mycosis fungoides was made. A case is reported by Roman[11] in which an eruption had appeared fifteen years previously which was "diagnosed as psoriasis" and which cleared up under local treatment. Five years later a similar eruption appeared "which was again pronounced psoriasis and again treated as such until it almost completely disappeared." For the past six years the patient had had an eruption, the nature of which was finally shown by the presence of infiltrations and tumor formations.

In none of the cases mentioned above was it stated that the premycotic eruption had been positively diagnosticated as psoriasis by an experienced dermatologist. In only two cases besides my own that I have been able to find has such a positive diagnosis been made, and in one of these the psoriasis was of rather recent origin.

---

8. Völckers, A.: Ueber Granuloma Fungoides (Mykosis Fungoides) der Haut, Inaug. Dissert., München, 1893.

9. Mannino, L.: Sulla Micosi Fungoide di Alibert, Gior. Ital. d. mal. ven., 1882, xvii, 348.

10. Von Zumbusch, L. R.: Beitrag zur Pathologie und Therapie der Mykosis Fungoides, Arch. f. Dermat. u. Syph., 1905, lxxviii, 21.

11. Roman, B.: Two Cases of Mycosis Fungoides, Jour. Cutan. Dis., 1910, xxviii, 506.

Digitized by Google

The case recorded by De Amicis[12] was that of a man of 65 who had suffered from psoriasis for two years. The eruption had consisted of patches which finally spread over his chest, upper extremities and part of one thigh. They were covered with silvery white scales. The year before he had visited the city dispensary "where his disease was pronounced to be psoriasis" and where he was treated by chrysophanic acid for five months without any benefit. The patches persisted "with a surprising tenacity" and later became "infiltrated and slightly exudating so that they were no longer seen covered with a mass of dry, lucid and silvery scales, but rather with crusts." The itching became more intolerable and the condition failed to yield to hydrotherapy or the administration of arsenic. Finally the diagnosis of mycosis fungoides was established by the appearance of tumors and ulceration.

The case described by Pick[13] was that of a man of 53 who had attended his clinic six years previously to obtain relief from psoriasis that was "very extensive and of very long duration" (the exact duration not being stated). Under local treatment most of the recent patches disappeared, while there was only moderate improvement in the "marked pachydermatous infiltrations." On these thickened patches the tumors of mycosis fungoides later developed.

A feature of interest in my case was the entire lack of itching during the period (two years) in which the lesions of mycosis fungoides were present. In the list of cases quoted, itching was mentioned as being severe or intolerable in seventy-nine cases and moderate in forty-one while in eleven cases there was no itching at all. In thirty-seven cases no reference was made to this symptom. It may be said, however, that many of the cases in which no mention was made of pruritus were

12. De Amicis, T.: Four Recent Cases of Mycosis Fungoides of Alibert with an Examination as Regards the Existence of Parasites, Tr. Ninth Internat. Med. Cong., 1887, 275.

13. Pick: Mitteilung eines Falles von Mykosis Fungoides, mit Krankendemonstration, Verhandl. der deutsch. dermat. Gesellsch., 1889, p. 284.

Digitized by Google

those in which the eruption assumed the tumor stage from the outset, or in which the case report was very meagre.

Another feature of interest in this case was the general pustular eruption which occurred eight years ago and which was considered to be syphilis by an experienced colleague. In favor of this diagnosis it may be said that, when the patient was seen three or four years later by his family physician, there was evidence of periostitis of the tibia. Whether the pustular eruption in this case was syphilitic or not, and it appears probable that it was, it does not seem to me, judging from the reports which I have read, that syphilis can be said to play a rôle of any importance in causing mycosis fungoides. In the list of 166 cases mentioned a history of syphilis was given in only six. It must be admitted, however, that some of the reports were too short to include any reference to the previous history of the patient. It is true that in quite a number of cases with nodules and ulcerations the possibility of syphilis was seriously considered in spite of negative history and the lack of other evidence of the disease. That these lesions were not syphilitic, however, was shown by the almost invariable failure to improve under antisyphilitic treatment.

A third point of interest in my case was the alcoholic tendency of the patient who had been a heavy drinker of whisky for many years. That this alcoholism had no etiologic bearing on the disease would seem probable from the fact that this condition was absent, or at least not mentioned, in the great majority of case reports above quoted.

In conclusion, I would say that while the premycotic eruption of mycosis fungoides is at times psoriasiform in type, the disease is very rarely preceded by an unmistakable attack of psoriasis. It also seems probable that neither syphilis nor alcoholism play any important rôle in the etiology of this mysterious and fatal disease.

Digitized by Google

NOTE.—A few days after the reading of this paper the patient was again observed. In the meantime the lesions of mycosis fungoides had almost entirely disappeared and a few typical psoriatic patches had again made their appearance. A biopsy was performed on an infiltrated, non-psoriatic lesion of the back, on which Dr. Sigmund Pollitzer was kind enough to make the following report:

"A section fixed in absolute alcohol with careful avoidance of tannin (cork) stained by Unna-Pappenheim showed the characteristic pleomorphism of the granulomatous cell-infiltrate which occupied the papillary and subpapillary regions and upper part of the corium. Among the cells were scattered minute fragments of granoplasm, stained red. The capillary walls were not thickened as they would be in syphilis. The picture confirmed the diagnosis of granuloma fungoides."

616 Madison Avenue.

## ABSTRACT OF DISCUSSION

DR. JOSEPH ZEISLER, Chicago: This case is of peculiar interest to me because of the fact that during the past winter I have had under my observation for many months an unquestioned case of mycosis fungoides in which the history closely parallels that related by Dr. Fox. This patient suffered from a skin eruption for ten years before I saw him. He saw various physicians in California, where he lived, and his eruption had been repeatedly pronounced either eczema or psoriasis. When I saw him, he had a generalized nodular eruption, which resembled both leprosy and syphilis, but by carefully sifting down the various findings I arrived at the diagnosis of mycosis fungoides, practically by exclusion. The further evolution of the case showed the correctness of that diagnosis. The Wassermann was negative, and injections of salvarsan, which he insisted on, did him no good. He improved, however, under the use of the Roentgen rays.

DR. C. A. BOREEN, Minneapolis: I saw in Vienna a case originally shown as one of psoriasis; but on the following day the diagnosis was changed to mycosis fungoides, and a few weeks later the typical ulcerative lesion of that disease developed.

DR. O. H. FOERSTER, Milwaukee: I recall the case of a man who for twenty-five years had been affected with a skin eruption which had been variously diagnosed by experienced men as erythrodermia, pityriasique en placque disseminé and other allied affections. Then suddenly, within the course of a week, it took on the appearance of a mycosis fungoides and eventually ended fatally.

DR. FRANK E. SIMPSON, Chicago: I should like to mention one point of apparent connection between mycosis fungoides

Digitized by Google

and leukemia. We had a fatal case of what had been diagnosed as mycosis fungoides clinically and the necropsy showed it to be a case of leukemia.

Dr. H. H. Hazen, Washington, D. C.: In a rather extensive study of mycosis fungoides which Dr. Strobel and I made three years ago, the investigations led us to believe that this disease is a leukemic lymphomatosis, and that it may become leukemic, as exemplified in the case recently reported by Pardee and Zeit. Necropsy reports show that the visceral lesions are mainly confined to the lymphatic system, and changes in the bone marrow have been reported.

Digitized by Google

# A STUDY OF THE SPINAL FLUID IN ONE HUNDRED CASES OF SYPHILIS

## INCLUDING INVESTIGATIONS FOR ARSENIC AFTER INTRAVENOUS ADMINISTRATION OF NEOSALVARSAN *

M. F. ENGMAN, M.D., RUDOLPH BUHMAN, M.D., F. D. GORHAM, M.D., AND R. H. DAVIS, M.D.

ST. LOUIS

Examination of the spinal fluid has in recent years become of great value in the study of syphilis of the nervous system, particularly in the so-called parasyphilitic conditions, tabes and paresis, which we now know, through the investigations of Noguchi and others, to be not parasyphilitic but due to the invasion of the cerebrospinal system by the *Spirochaeta pallida* itself.

We undertook the investigation of the cerebrospinal fluid on account of the definite findings that can be demonstrated in it to indicate an invasion of the cerebrospinal system by the *Spirochaeta pallida,* the purpose being to determine what percentage of patients with syphilis applying for treatment at a general dermatologic clinic would show evidence of spinal invasion.

The large percentage of early syphilis reported in literature as giving evidence of meningeal disturbance encouraged us. All of the cases of syphilis, therefore, in the outpatient department of the Washington University Hospital and the Barnard Free Skin and Cancer Hospital, if the patient would submit to spinal puncture, were studied.

It is admitted by all observers that spinal puncture is of the greatest diagnostic importance in tabes and

* From the Medical Department of Washington University and the Barnard Skin and Cancer Hospital.

Digitized by Google

paresis and in any obscure condition of the central nervous system where syphilis is suspected. It is not necessary at present to dwell on the value of the various reactions which are accepted as significant of cerebrospinal invasion by the *Spirochaeta pallida,* but it may be stated that a Wassermann positive in the spinal fluid is of the greatest value. Secondly, a cytologic examination of the fluid revealing more than ten lymphocytes to the cubic millimeter, together with a positive Wassermann, is of pathologic significance. The presence of an abnormal quantity of globulin content is also of value in conjunction with the other two findings. This might also be said of Fehling's reduction test. A high lymphocyte-count is not necessarily pathognomonic of lues, as it may also occur in tuberculous meningitis and other meningeal disturbances. Most writers consider a count above ten as an indication of a pathologic condition, and in general paralysis and tabes and other types of cerebrospinal syphilis one usually finds a marked increase confined almost solely to the mononuclear type of cell.

The method introduced by Nonne, which is a modification of Niesl's, to demonstrate the presence of increased protein in the form of serum globulin, has been brought forward as another aid to diagnosis, as the normal spinal fluid contains such a small percentage of this protein that it is not detected by the usual methods, whereas in syphilitic infection it can usually be demonstrated. A high cell-count and increase in the globulin content are present in over 90 per cent. of cases of cerebrospinal syphilis, while in other inflammatory conditions of the nervous system they are negative, with the possible exception of tuberculous meningitis. When there is an abnormal increase in the lymphocytes, together with a positive Wassermann reaction, the diagnosis of syphilis can be positively made.

All of the cases in the investigation were examined in the following manner: Blood and spinal fluid were obtained simultaneously and a Wassermann

Digitized by Google

reaction made on the two fluids, two separate antigens being used with increasing amounts of spinal fluid, beginning with 0.2 c.c. and increasing to 0.5 c.c. The cells in the spinal fluid were counted from undiluted fluid in the ordinary blood-counting chamber. The globulin reaction was determined by the Noguchi method. Fehling's reduction test was also performed on each fluid, as normal spinal fluid reduces Fehling's solution, owing supposedly to the presence of pyrocatechin. This reaction is sometimes absent, however, in inflammatory conditions.

One of the earliest investigators of the spinal fluid in syphilitics is Ravaut[1] who, in 1903, affirmed that a large number of syphilitics at all periods of the disease presented a lymphocytosis in the spinal fluid which was indicative of meningeal disturbance, and in 1907 showed that a large percentage of syphilitic children showed spinal involvement. The majority of the latter presented mucous membrane and cutaneous lesions also. Ravaut[2] again affirmed, in 1912, that at the time of the chancre there was no involvement of the nervous system, but that 67 per cent. of the syphilitics showing no clinical nervous symptoms had a meningeal infection, evidenced by lymphocytosis and albumin content in the spinal fluid. He believed from this that if, in the secondary period, such a positive reaction should be present, the administration of salvarsan was dangerous, as the spirochete fixed the arsenic and caused a neurotropic reaction.

Jeanselme and Chevallier[3] state that the spinal fluid is negative in the chancre stage and positive in a large majority of cases in the so-called secondary period of the invasion, but that only a small percentage show involvement of the cerebrospinal system through the study of the spinal fluid in late syphilis. From their investigations these two writers affirm that there may be no clinical symptoms of meningeal involvement, with

1. Ravaut: Ann. de dermat. et de syph., 1903, p. 537.
2. Ravaut: Ann. de dermat. et de syph., 1907, p. 81.
3. Jeanselme and Chevallier: Ann. de dermat. et de syph., 1912, p. 506.

Digitized by Google

considerable cytologic evidence, or that such an involvement may cause severe headache which is relieved by lumbar puncture. They also state that syphilitics in the so-called secondary period with no eruption may show marked lymphocytosis in the fluid. From the reported findings of these investigators and others, the general opinion has been that a large percentage of early cases of syphilis show invasion of the cerebrospinal system and the prognosis depends only on a proper study of the spinal fluid. We were under this impression when we undertook this work, but have been surprised at our results, as it differs so materially from that of others.

Previous to spinal puncture, a complete physical examination of each patient was made; namely, of the viscera, fundus of the eye, pupillary and the various other reflexes, and for other symptoms of central nerve involvement. As headache is frequently a prominent early symptom of cerebral lues, careful note of this was made in each case. In all cases in which it was possible, more than one puncture was made and after each a maximum dose of neosalvarsan was administered intravenously. In four cases, after the intravenous injection of neosalvarsan a search was made for arsenic in the spinal fluid, details of which we shall give later.

## REPORT OF CASES

CASE 1.—P. C.[4] Congenital lues. Viscera, heart and reflexes normal. Iritis of both eyes. Nov. 19, 1912: Wassermann, serum ++++, spinal fluid ++++; cell-count 54, globulin +, reduction ±. Treatment, neosalvarsan and mercury. Puncture normal; fluid clear.

CASE 2.—Blood positive; spinal fluid negative. P. C. Infection seven years ago. Late lues. Tuberculous ulceration of lip and chin. Viscera, heart, eyes and reflexes normal. Oct. 20, 1912: Wassermann, serum ++++, spinal fluid —; cell count 8, globulin —, reduction +. Puncture normal; fluid clear.

4. In the case reports abbreviations indicate: W. U.=Washington University; B. F. S. and C. H.=Barnard Free Skin and Cancer Hospital; P. C. = private consultation.

Digitized by Google

CASE 3.—Blood positive; spinal fluid negative. History 4155, Barnard Free Skin and Cancer Hospital. Infection eight years ago. Ulceration on septum of nose; healed scars on leg. Viscera, heart, eyes and reflexes normal. Nov. 15, 1912: Wassermann, serum ++++, spinal fluid —; globulin ±, cell-count 7, reduction +. Puncture normal, fluid clear. Treatment, neosalvarsan and mercury.

CASE 4.—Blood positive; spinal fluid negative. History 4270, B. F. S. and C. H. No history of lues. No lesions. Mentality poor. Viscera, heart, eyes and reflexes normal. Nov. 22, 1912: Wassermann, serum +++, spinal fluid —; cell-count 8, globulin —, reduction +. March 12, 1913: Wassermann, serum ++, spinal fluid —; cell-count 10, globulin —, reduction +. Puncture normal, fluid clear.

CASE 5.—History 3575, B. F. S. and C. H. No history of lues obtainable. Hemiplegia of entire left side; mental aberration, exaggerated reflexes, ankle-clonus. Aug. 17, 1912: Wassermann, serum ++++, spinal fluid ++++; cell-count 60, globulin +, reduction ±. Puncture, increased pressure; fluid clear. Treatment, salvarsan and mercury. Nov. 9, 1912: Wassermann, serum ++++, spinal fluid ++++; globulin +, cell-count 25, reduction +. Puncture normal, fluid clear.

CASE 6.—Blood positive; spinal fluid negative. History 4223, B. F. S. and C. H. Infection two months ago. Primary anus; inguinal adenopathy. Oct. 31, 1912: Wassermann, serum ++++, spinal fluid —; reduction +, globulin —, cell-count 10. Puncture normal; fluid clear.

CASE 7.—History 4212, B. F. S. and C. H. No history of infection. Early symptoms of tabes. Heart, eyes and viscera normal. Knee-reflexes sluggish. Oct. 30, 1912: Wassermann, serum +, spinal fluid ++; cell-count 20, globulin +, reduction —. Puncture normal, fluid clear.

CASE 8.—History 4282, B. F. S. and C. H. History indefinite. Late lues. Circinate ulceration of left arm. Viscera, heart, eyes and reflexes normal. Nov. 22, 1912: Wassermann, serum ++++, spinal fluid ++++; cell-count 25, globulin +, reduction ±. Puncture, increased pressure; fluid clear.

CASE 9.—History 4179, B. F. S. and C. H. Infection one year ago. No lesions at present. Viscera, heart, eyes and reflexes normal. Oct. 12, 1912: Wassermann, serum ++++, spinal fluid ++++; globulin +, cell-count 30, reduction ±. Puncture normal, fluid clear.

CASE 10.—Blood positive; spinal fluid negative. History 4219, B. F. S. and C. H. Infection one month ago. Macular secondaries at present. Viscera, heart, eyes and reflexes normal. Nov. 2, 1912: Wassermann, serum ++++, spinal fluid —; cell-count 4, globulin —, reduction +. Puncture normal, fluid clear.

Digitized by Google

CASE 11.—Blood positive, spinal fluid negative. History 4197, B. F. S. and C. H. Infection six weeks ago. Inguinal adenopathy; macular secondaries. Oct. 25, 1912: Wassermann, serum ++++, spinal fluid —; cell-count 10, globulin —, reduction +. Puncture normal, fluid clear. Treatment, salvarsan and mercury. Viscera, heart, eyes and reflexes normal.

CASE 12.—Blood positive; spinal fluid negative. History 4192, B. F. S. and C. H. Primary lesion three months ago. Mucous patches, macular secondaries. Viscera, heart, eyes and reflexes normal. Oct. 22, 1912: Wassermann, serum ++++, spinal fluid —; cell-count 3, globulin —, reduction +. Puncture normal, fluid clear. Treatment, salvarsan.

CASE 13.—Blood positive; spinal fluid negative. History 4191, B. F. S. and C. H. Infection five months ago. Papular secondaries; paronychia. Viscera, heart, eyes and reflexes normal. Oct. 18, 1912: Wassermann, serum ++++, spinal fluid —; cell-count 4, globulin —, reduction +. Puncture normal, fluid clear. Treatment, salvarsan.

CASE 14.—Blood positive; spinal fluid negative. History 4121, B. F. S. and C. H. No history of infection. Late lues. Destructive ulceration on ala of nose. Viscera, heart, eyes and reflexes normal. Oct. 10, 1912: Wassermann, serum ++++, spinal fluid —; cell-count 10, globulin —; reduction +. Puncture normal, fluid clear. Treatment, salvarsan.

CASE 15.—Blood positive; spinal fluid negative. History 4116, B. F. S. and C. H. Infection five years ago. Punched-out ulcer on leg at present. General adenopathy. Viscera, heart, eyes and reflexes normal. Nov. 21, 1912. Wassermann, serum ++++, spinal fluid —; cell-count 3, globulin —, reduction +. Puncture normal, fluid clear. Treatment, salvarsan and mercury.

CASE 16.—Blood positive, spinal fluid negative. History 4555, B. F. S. and C. H. Infection twenty years ago. At present large tuberculous ulceration of upper lip, nose and cheek; many healed scars. Viscera, heart, eyes and reflexes normal. March 17, 1913: Wassermann, serum ++++, spinal fluid —; cell-count 12, globulin ±, reduction +. Puncture normal, fluid clear. Treatment, salvarsan and mercury. April 2, 1913: Wassermann, serum ++++, spinal fluid —; cell-count 5, globulin —, reduction +. Puncture normal; fluid clear.

CASE 17.—History 4544, B. F. S. and C. H. Infection two months ago. No lesions at present. Viscera, heart and eyes normal, reflexes sluggish. March 6, 1913: Wassermann, serum ++++, spinal fluid —; cell-count 17, globulin —, reduction +. Puncture, slight increase in pressure; fluid clear. Treatment, neosalvarsan.

Digitized by Google

CASE 18.—Blood positive; spinal fluid negative. History 4253, B. F. S. and C. H. No history of infection. Severe headaches; no lesions. Viscera, heart, eyes and reflexes normal. Nov. 13, 1912: Wassermann, serum ++++. Treatment, neosalvarsan and mercury. March 6, 1913. Wassermann, serum ++++, spinal fluid —; cell-count 15, globulin ±, reduction +. Puncture, slight increase in pressure; fluid clear.

CASE 19.—Blood positive; spinal fluid negative. History 4415, B. F. S. and C. H. No history of infection. Late lues. Tuberculous ulceration on ala of nose. Viscera, heart and eyes normal. Reflexes, left knee-jerk sluggish; others normal. Feb. 4. 1913: Wassermann, serum ++++, spinal fluid —; cell-count 12, globulin —, reduction +. Puncture normal, fluid clear.

CASE 20, Sanatorium.—No history of infection. At present paresis. Patient confined in sanatorium. Pupils irregular; reaction sluggish; knee and Achilles reflexes absent. Viscera and heart normal. April 22, 1913: Wassermann, serum ++++, spinal fluid ++++; globulin +, cell-count 112, reduction ±. Puncture, increased pressure; fluid clear. April 22, 1913: Treatment, neosalvarsan 0.9 gm. intravenously. April 27, 1913: Puncture; spinal fluid examined for the presence of arsenic with negative result.

CASE 21, Sanatorium.—Date of infection not obtainable. Patient confined in sanatorium with paresis. Romberg's symptom present; pupils equal, reaction good. Knee and Achilles reflexes absent. Viscera and heart normal. April 22, 1913: Wassermann, serum ++++, spinal fluid ++++; cell-count 32, globulin +, reduction +. Puncture, increased pressure; fluid clear. April 22, 1913: Treatment, neosalvarsan 0.9 gm. intravenously. April 27, 1913: Puncture; spinal fluid examined for the presence of arsenic with negative result.

CASE 22, Sanatorium.—Infection fifteen years ago. No history of treatment obtainable. Patient confined in sanatorium with paresis. Pupils irregular; reaction sluggish. Achilles and knee-reflexes absent. April 22, 1913: Wassermann, serum ++++, spinal fluid ++++; cell-count 42, globulin +, reduction ±. Puncture, pressure normal; fluid clear. Treatment, neosalvarsan 0.9 gm. intravenously. April 24, 1913: Puncture; spinal fluid examined for the presence of arsenic with negative result.

CASE 23, Sanatorium.—Date of infection not obtainable. Patient confined in sanatorium with paresis. Romberg's symptom present; pupils irregular; reaction sluggish. Reflexes: Knee sluggish, Achilles absent. Viscera and heart normal. April 22, 1913: Wassermann, serum ++++, spinal fluid ++++; cell-count 62, globulin +, reduction —. Punc-

Digitized by Google

ture, pressure increased; fluid clear. Treatment, neosalvarsan 0.9 gm. intravenously. April 24, 1913: Puncture; spinal fluid examined for the presence of arsenic with negative result.

CASE 24.—Blood positive; spinal fluid negative. History 4429, B. F. S. and C. H. Infection three months ago. Mucous patches and general adenopathy. Viscera, heart, eyes and reflexes normal. Jan. 25, 1913: Wassermann, serum ++++, spinal fluid —; cell-count, 12, globulin —, reduction +. Puncture normal, fluid clear. Treatment, neosalvarsan and mercury.

CASE 25.—Blood positive; spinal fluid negative. History 4401, B. F. S. and C. H. Infection three years ago. Deep ulceration at angle of both jaws; healed scars left inguinal region. Viscera, heart and eyes normal. Exaggerated knee-reflexes. Feb. 17, 1913: Wassermann, serum ++++, spinal fluid —; cell-count 10, globulin —, reduction +. Puncture normal, fluid clear. Treatment, neosalvarsan and mercury.

CASE 26.—Blood positive; spinal fluid negative. History 4475, B. F. S. and C. H. No history of infection. Healed scars on face. Late lues. Viscera, heart, eyes and reflexes normal. Feb. 26, 1913: Wassermann, serum ++++, spinal fluid —; cell-count 20, globulin —, reduction +. Puncture, pressure decreased; fluid clear. Treatment, neosalvarsan.

CASE 27.—Blood positive; spinal fluid negative. History 4495, B. F. S. and C. H. Infection ten years ago. No lesions. Viscera, heart, eyes and reflexes normal. Feb. 27, 1913: Wassermann, serum +, spinal fluid —; cell-count 5, globulin —, reduction +. Puncture normal; fluid clear. Treatment. neosalvarsan.

CASE 28.—Blood positive; spinal fluid negative. History 4019, B. F. S. and C. H. Infection six years ago. Late lues. Partial destruction of septum of nose and palate. Viscera. eyes and reflexes normal. Heart, slight mitral regurgitation. Aug. 1, 1912: Wassermann, serum ++++. Treatment, salvarsan and mercury. Jan. 10, 1913: Wassermann, serum ++++, spinal fluid —; cell-count 5, globulin +, reduction +. Puncture normal; fluid clear. Feb. 19, 1913: Wassermann, serum ++, spinal fluid —; cell-count 7, globulin —, reduction +. Puncture normal, fluid clear.

CASE 29.—Blood positive; spinal fluid negative. History 4500, B. F. S. and C. H. Infection five years ago. Late palmar lues. Viscera, heart, eyes and reflexes normal. Feb. 19, 1913: Wassermann, serum +, spinal fluid —; cell-count 2, globulin —, reduction +. Puncture normal, fluid clear. Treatment, neosalvarsan.

CASE 30.—Blood positive; spinal fluid negative. History 4522, B. F. S. and C. H. Infection three years ago. Late tuberculous lues on shoulder, legs and back. Heart, accentu-

Digitized by Google

ated second sound. Viscera, eyes and reflexes normal. Feb. 28, 1913: Wassermann, serum ++++, spinal fluid —; cell-count 5, globulin —, reduction +. Puncture normal, fluid clear. Treatment, neosalvarsan and mercury.

CASE 31.—Blood positive; spinal fluid negative. History 3802, B. F. S. and C. H. No history of infection. Late tuberculous lues over body. Viscera, heart, eyes and reflexes normal. May 7, 1912: Wassermann, serum ++++. Treatment, salvarsan and mercury. Feb. 26, 1913: Wassermann, serum ++++, spinal fluid —; cell-count 17, globulin —, reduction +. Puncture, increased pressure; fluid clear.

CASE 32.—Blood positive; spinal fluid negative. History 4274, B. F. S. and C. H. No history of infection. Late lues; loss of uvula and part of soft palate. Viscera, heart, eyes and reflexes normal. Nov. 20, 1912. Wassermann, serum ++++, spinal fluid —; cell-count 5, globulin —, reduction +. Puncture normal, fluid clear. Treatment, salvarsan.

CASE 33.—Blood positive; spinal fluid negative. History 4652, B. F. S. and C. H. Infection one year ago. Small pustular syphilid and iritis. Viscera, heart and reflexes normal. Treatment, neosalvarsan. April 16, 1913: Wassermann, serum ++++, spinal fluid —; cell-count 5, globulin —, reduction +. Puncture normal, fluid clear.

CASE 34.—Blood positive; spinal fluid negative. History 4664, B. F. S. and C. H. Infection five years ago. At present mucous patches, corneal ulcers and iritis. Viscera and heart normal. Knee-reflexes accentuated. April 21, 1913: Wassermann, serum ++++, spinal fluid —; cell-count 12, globulin —, reduction +. Puncture normal, fluid clear. Treatment, neosalvarsan.

CASE 35.—History 1545, B. F. S. and C. H. Infection fourteen years ago. Late lues; tuberculous ulcer of lower lip. Viscera, heart and eyes normal. Knee-reflexes sluggish. April 11, 1913. Wassermann, serum ++++. Treatment, neosalvarsan. April 21, 1913: Wassermann, serum ++++, spinal fluid ++++; cell-count 27, globulin +, reduction ±. Puncture, pressure increased, fluid clear.

CASE 36.—History 4051, B. F. S. and C. H. Infection eight months ago. Viscera, heart and eyes normal. Reflexes, knee and Achilles, sluggish. March 12, 1913: Wassermann, serum ++++, spinal fluid ++++; cell-count 42, globulin +, reduction ±. Puncture, pressure increased, fluid clear. Treatment, neosalvarsan and mercury. March 26, 1913: Wassermann, serum ++++.

CASE 37.—Blood positive; spinal fluid negative. History 3422, B. F. S. and C. H. Infection eleven years ago. Late lues. No lesions. Viscera, heart, eyes and reflexes normal. Oct. 7, 1911: Wassermann, serum ++++. Treatment, sal-

Digitized by Google

varsan and mercury. Feb. 3, 1912: Wassermann; serum ++. Jan. 22, 1913: Wassermann, serum ++++, spinal fluid —; cell-count 10, globulin —, reduction +. Puncture normal, fluid clear.

CASE 38.—Blood positive; spinal fluid negative. History 4592, B. F. S. and C. H. Infection fifteen years ago. No lesions. Rheumatism and headaches. Viscera, heart, eyes and reflexes normal. March 27, 1913: Wassermann, serum ++, spinal fluid —; cell-count 7, globulin —, reduction +. Puncture normal, fluid clear. Treatment, neosalvarsan and mercury.

CASE 39.—History 4339, B. F. S. and C. H. Infection two months ago. Macular secondaries. Viscera, heart, eyes and reflexes normal. Dec. 23, 1912: Wassermann, serum ++++, spinal fluid —; cell-count 12, globulin ±, reduction +. Puncture normal, fluid clear. Treatment, salvarsan.

CASE 40.—Blood positive; spinal fluid negative. History 4387, B. F. S. and C. H. Infection six weeks ago. Mucous patches. Viscera, heart, eyes and reflexes normal. Jan. 8, 1913: Wassermann, serum ++++, spinal fluid —; cell-count 5, globulin —, reduction +. Puncture normal, fluid clear. Treatment, neosalvarsan.

CASE 41.—Blood positive; spinal fluid negative. History 4390, B. F. S. and C. H. Infection two months ago. Mucous patches and macular secondaries. Viscera, heart, eyes and reflexes normal. Jan. 24, 1913: Wassermann, serum ++++, spinal fluid —; cell-count 4, globulin —, reduction +. Puncture normal, fluid clear. Treatment, neosalvarsan.

CASE 42.—History 4375, B. F. S. and C. H. Infection five years ago. Healed scars on right forearm. Viscera, heart and eyes normal. Reflexes, knee and Achilles accentuated; ankle-clonus marked on both sides. Jan. 2, 1913: Wassermann, serum ++++, spinal fluid ++++; cell-count 15, globulin +, reduction —. Puncture, increased pressure; fluid clear. Treatment, neosalvarsan and mercury.

CASE 43.—Blood positive; spinal fluid negative. History 4548, B. F. S. and C. H. Infection six weeks ago. Mucous patches and sore throat. Viscera, heart, eyes and reflexes normal. March 10, 1913: Wassermann, serum ++++, spinal fluid —; cell-count 7, globulin —, reduction +. Puncture normal, fluid clear. Treatment, neosalvarsan and mercury.

CASE 44.—Blood positive; spinal fluid negative. History 4704, B. F. S. and C. H. Infection five years ago. Healed scars on hip and forearm. Viscera, heart, eyes and reflexes normal. March 23, 1913: Wassermann, serum +++, spinal fluid —; cell-count 12, globulin —, reduction +. Puncture normal, fluid clear. Treatment, neosalvarsan.

Digitized by Google

CASE 45.—History 4571, B. F. S. and C. H. Infection two months ago. Large crusted primary on lower lip; submental adenopathy. Viscera, heart, eyes and reflexes normal. March 14, 1913: Wassermann, serum ++++, spinal fluid —; cell-count 12, globulin —, reduction +. Puncture normal, fluid clear. Treatment, neosalvarsan.

CASE 46.—Blood positive; spinal fluid negative. History 4565, B. F. S. and C. Infection fourteen years ago. No lesions. Iritis, right eye. Viscera, heart and reflexes normal. March 14, 1913: Wassermann, serum ++++, spinal fluid —; cell-count 20, globulin ±, reduction +. Puncture normal, fluid clear. Treatment, neosalvarsan and mercury.

CASE 47.—Blood positive; spinal fluid negative. History 4433, B. F. S. and C. No history of infection. Late lues. Typical luetic ulcer, right leg. Viscera, heart, eyes and reflexes normal. Jan. 24, 1913: Wassermann, serum ++++, spinal fluid —; cell-count 4, globulin —, reduction +. Puncture normal, fluid clear. Treatment, neosalvarsan.

CASE 48.—Blood positive; spinal fluid negative. History 4586, B. F. S. and C. H. Infection thirteen weeks ago. Viscera, eyes and reflexes normal. Heart, second sound accentuated. March 27, 1913: Wassermann, serum ++++, spinal fluid —; cell-count 2, globulin —, reduction +. Puncture normal, fluid clear. Treatment, neosalvarsan.

CASE 49.—History 4574. B. F. S. and C. H. Infection four years ago. No lesions. Viscera, eyes and reflexes normal. Heart, systolic murmur at third intercostal space. March 27, 1913: Wassermann, serum +++, spinal fluid ++++; cell-count 107, globulin +, reduction ±. Puncture, increased pressure; fluid clear. Treatment, neosalvarsan.

CASE 50.—Blood positive; spinal fluid negative. History 4590, B. F. S. and C. H. No history of infection. At present tuberculous palmar lues. Viscera and heart normal. Pupils, reaction sluggish. Reflexes, knee and Achilles, sluggish. March 27, 1913: Wassermann, serum ++++, spinal fluid —; cell-count 5, globulin —, reduction +. Puncture normal, fluid clear. Treatment, neosalvarsan and mercury. April 9, 1913: Wassermann, serum ++++, spinal fluid —; cell-count 7, globulin —, reduction +. Puncture normal, fluid clear.

CASE 51.—Blood positive; spinal fluid negative. History 4596, B. F. S. and C. H. Infection three years ago. No lesions. Viscera, heart and reflexes normal. Iritis of right eye. March 27, 1913: Wassermann, serum +, spinal fluid —; cell-count 10, globulin —, reduction +. Puncture normal, fluid clear. Treatment, neosalvarsan and mercury.

CASE 52.—Blood positive; spinal fluid negative. History 4349, B. F. S. and C. H. Infection fifteen years ago. Late palmar lues. Viscera, heart, eyes and reflexes normal. Dec.

Digitized by Google

23, 1912: Wassermann, serum ++, spinal fluid —; cell-count 10, globulin —, reduction +. Puncture normal, fluid clear. Treatment, salvarsan.

CASE 53.—Blood positive; spinal fluid negative. History 4304, B. F. S. and C. H. Infection four years ago. Circinate lesions on arm and forehead. Viscera, heart, eyes and reflexes normal. Dec. 2, 1912: Wassermann, serum ++++, spinal fluid —; cell-count 20, globulin —, reduction +. Puncture normal, fluid clear. Treatment, salvarsan.

CASE 54.—Blood positive; spinal fluid negative. History 4302, B. F. S. and C. H. Infection one month ago. Papular secondaries. Viscera, heart, eyes and reflexes normal. Nov. 29, 1912: Wassermann, serum ++++, spinal fluid —; cell-count 5, globulin —, reduction +. Puncture normal, fluid clear. Treatment, salvarsan.

CASE 55.—Blood positive; spinal fluid negative. History 3021, B. F. S. and C. H. Infection thirteen years ago. No lesions. Hemiplegia of left side in 1908. At present severe pains in left arm and leg. Right pupil larger than left; both react to light and accommodation. Left knee-jerk accentuated; right normal. Viscera and heart normal. Oct. 14, 1912: Wassermann, serum ++++. Treatment, salvarsan and mercury. Nov. 26, 1912: Wassermann, serum ++++, spinal fluid —; cell-count 10, globulin ±, reduction +. Puncture normal, fluid clear.

CASE 56.—History 4282, B. F. S. and C. H. No history of infection. At present, circinate ulceration on left arm. Healed scars on both arms. Nov. 22, 1912: Viscera, heart and eyes normal. Knee-reflexes slightly accentuated. Wassermann, serum ++++, spinal fluid ++++; cell-count 25, globulin +, reduction ±. Puncture, increased pressure; fluid clear. Treatment, salvarsan.

CASE 57.—Blood positive; spinal fluid negative. History 4386, B. F. S. and C. H. Infection three years ago. At present, tuberculous lues of both hands. Viscera, heart, eyes and reflexes normal. Jan. 9, 1913: Wassermann, serum ++++, spinal fluid —; cell-count 6, globulin —, reduction +. Puncture normal, fluid clear. Treatment, neosalvarsan.

CASE 58.—Blood positive; spinal fluid negative. History 2319, B. F. S. and C. H. No history of infection. Late lues. Uvula, soft palate entirely gone. Superior maxillary and nasal bones show necrosis. Treatment, mercury. Feb. 1, 1911: Wassermann, serum +++. Jan. 18, 1913: Viscera, heart and eyes normal. Reflexes active. Jan. 20, 1913: Wassermann, serum ++++, spinal fluid —; cell-count 12, globulin ±, reduction +. Puncture normal, fluid clear. Treatment, neosalvarsan and mercury.

Digitized by Google

Case 59.—Blood positive; spinal fluid negative. History 4403, B. F. S. and C. H. Infection two months ago. At present, mucous patches in mouth and tonsils. Viscera, eyes and reflexes normal. Heart, second sound accentuated. Nov. 10, 1912: Wassermann, serum ++++, spinal fluid —; cell-count 4, globulin —, reduction +. Puncture normal, fluid clear. Treatment, salvarsan.

Case 60.—Blood positive; spinal fluid negative. History 4566, B. F. S. and C. H. Infection three years ago. At present, mucous patches. Viscera, heart and eyes normal. Reflexes slightly exaggerated. March 12, 1913. Wassermann, serum ++++, spinal fluid —; cell-count 12, globulin —, reduction +. Puncture normal, fluid clear. Treatment, neosalvarsan.

Case 61.—Blood positive; spinal fluid negative. History 4498, B. F. S. and C. H. Infection one month ago. Viscera, heart, eyes and reflexes normal. March 10, 1913: Wassermann, serum ++++, spinal fluid —; cell-count 5, globulin —, reduction +. Puncture normal, fluid clear. Treatment, neosalvarsan.

Case 62.—Blood positive; spinal fluid negative. History 4628, B. F. S. and C. H. Infection six months ago. No lesions. Viscera, heart, eyes and reflexes normal. March 7, 1913: Wassermann, serum ++++, spinal fluid —; cell-count 7, globulin —, reduction +. Puncture normal, fluid clear. Treatment, neosalvarsan.

Case 63.—Blood positive; spinal fluid negative. History 4551, B. F. S. and C. H. Infection two months ago. Mucous patches on mouth and tonsils; macular secondaries. Viscera, heart and reflexes normal. Pericorneal congestion of eyes; hyperemia of iris. March 21, 1913: Wassermann, serum ++++, spinal fluid —; cell-count 4, globulin —, reduction +. Puncture normal, fluid clear. Treatment, neosalvarsan.

Case 64.—Blood positive; spinal fluid negative. History 4636, B. F. S. and C. H. Infection one month ago. Macular secondaries. Viscera, heart and eyes normal. Reflexes sluggish. April 11, 1913: Wassermann, serum ++++, spinal fluid —; cell-count 2, globulin —, reduction +. Puncture normal; fluid clear. Treatment, neosalvarsan.

Case 65.—Blood positive; spinal fluid negative. History 4631, B. F. S. and C. H. No history of infection. At present, luetic ulcer of leg. Viscera, heart, eyes and reflexes normal. April 9, 1913: Wassermann, serum ++++, spinal fluid —; cell-count 5, globulin —, reduction +. Puncture, increased pressure; fluid clear. Treatment, neosalvarsan.

Case 66.—Blood positive; spinal fluid negative. History 4618, B. F. S. and C. H. Infection four years ago. Now has tuberculous ulceration at angle of jaw. April 2, 1913: Wassermann, serum ++++, spinal fluid —; cell-count 10, globu-

Digitized by Google

lin —; reduction +. Puncture normal, fluid clear. Treatment, neosalvarsan. Viscera, heart, eyes and reflexes normal.

CASE 67.—History 4391, B. F. S. and C. H. Infection seven years ago. No lesions. Viscera, heart, eyes and reflexes normal. Jan. 11, 1913: Wassermann, serum ++++, spinal fluid ++++; cell-count 34, globulin +, reduction ±. Puncture normal, fluid clear. Treatment, salvarsan.

CASE 68.—Blood positive; spinal fluid negative. History 4254, B. F. S. and C. H. Infection six weeks ago. Mucous patches in mouth and tonsils. General adenopathy. Viscera, heart, eyes and reflexes normal. Nov. 22, 1912: Wassermann, serum ++++, spinal fluid —; cell-count 3, globulin —, reduction +. Puncture normal, fluid clear. Treatment, salvarsan.

CASE 69.—Blood positive; spinal fluid negative. History 4632, B. F. S. and C. H. No history of infection. Mucous patches in mouth. Viscera, heart, eyes and reflexes normal. March 10, 1913: Wassermann, serum ++++, spinal fluid —; cell-count 5, globulin —, reduction +. Puncture normal, fluid clear. Treatment, neosalvarsan.

CASE 70.—Blood positive; spinal fluid negative. History 4540, B. F. S. and C. H. Infection eight years ago. No lesions. Viscera, heart and eyes normal. Knee-reflexes sluggish. March 6, 1913: Wassermann, serum ++++, spinal fluid —; cell-count 4, globulin —, reduction +. Puncture normal, fluid clear. Treatment, neosalvarsan.

CASE 71.—History P. C. Infection eighteen years ago. Early tabes. Eyes, reaction sluggish. Reflexes, knee and Achilles, absent. Viscera and heart normal. Feb. 14, 1913: Wassermann, serum ++++, spinal fluid ++++; globulin +; cell-count 60, reduction —. Puncture, increased pressure; fluid clear.

CASE 72.—Blood positive; spinal fluid negative. History P. C. Infection eight months ago. No lesions. Viscera, heart, eyes and reflexes normal. Oct. 9, 1912: Wassermann, serum ++++, spinal fluid —; cell-count 8, globulin —, reduction +. Puncture normal, fluid clear. Treatment, neosalvarsan.

CASE 73.—Blood positive; spinal fluid negative. History 4644, B. F. S. and C. H. Infection five months ago. Viscera, heart and reflexes normal. Eyes, scarring from old ulcer on cornea. March 6, 1913: Wassermann, serum ++++, spinal fluid —; cell-count 5, globulin —, reduction +. Puncture normal, fluid clear. Treatment, neosalvarsan.

CASE 74.—Blood positive; spinal fluid negative. History 370, Washington University. No history of infection. No skin lesions. Reflexes sluggish; aortic regurgitation; atrophy of muscles right arm and leg. Ptosis of right eyelid.

Digitized by Google

Necropsy, syphilitic aortitis. Nov. 20, 1912: Wassermann, serum ++++, spinal fluid —; cell-count 12, globulin —, reduction +. Puncture normal, fluid clear.

CASE 75.—History 363, W. U. No history of infection. No lesions. Progressive muscular atrophy. Reflexes accentuated. Nov. 11, 1912: Wassermann, serum —, spinal fluid ++++; cell-count 26, globulin +, reduction +. Puncture normal, fluid clear.

CASE 76.—Blood positive; spinal fluid negative. P. C. Infection two years ago. Slight ulceration on chin. Viscera, heart, eyes and reflexes normal. March 7, 1913: Wassermann, serum ++++, spinal fluid —; cell-count 10, globulin —, reduction +. Puncture normal, fluid clear. Treatment, neosalvarsan.

CASE 77.—Blood positive; spinal fluid negative. P. C. Infection six weeks ago. Papular secondaries. Viscera, heart, eyes and reflexes normal. Feb. 12, 1913: Wassermann, serum ++++, spinal fluid —; cell-count 7, globulin —, reduction +. Puncture normal, fluid clear. Treatment, neosalvarsan.

CASE 78.—History 334, W. U. Definite history of syphilis twenty years ago. No skin lesions. Physical examination; aneurysm of arch of aorta. Reflexes difficult to elicit. Oct. 30, 1912: Wassermann, serum —, spinal fluid —; cell-count 43, globulin +, reduction ±. Puncture normal, fluid clear.

CASE 79.—History 424, W. U. History of infection nine years ago. No skin lesions. Symptoms of chronic lead-poisoning. Nov. 4, 1912: Wassermann, serum ++++, spinal fluid ++++; cell-count 264, globulin +, reduction ±. Puncture normal, fluid clear.

CASE 80.—Blood positive; spinal fluid negative. History 371, W. U. No history of infection. Discharging sinus at lower end of sternum and sacro-iliac joint. Viscera, heart, eyes and reflexes normal. Nov. 20, 1912: Wassermann, serum ++++, spinal fluid —; cell-count 8, globulin +, reduction +. Puncture normal, fluid clear.

CASE 81.—History 368, W. U. Infection ten years ago. No lesions. Viscera, heart, eyes and reflexes normal. Neck rigid. Tuberculosis of cervical vertebra. Ankylosis of right knee. Dec. 6, 1912: Wassermann, serum ++++, spinal fluid ++++; cell-count 32, globulin +, reduction +. Puncture normal, fluid clear.

CASE 82.—Blood positive; spinal fluid negative. History 471, W. U. Infection four years ago. No skin lesions. Heart and eyes normal. Reflexes active. Gumma of liver. March 17, 1913: Wassermann, serum ++++, spinal fluid —; cell-count 9, globulin —, reduction +. Puncture normal, fluid clear.

Digitized by Google

Case 83.—Blood positive; spinal fluid negative. History 500, W. U. Infection fifteen years ago. No skin lesions. Viscera, heart and eyes normal. Paraplegia (transverse myelitis) improved under antiluetic treatment. March 29, 1913: Wassermann, serum ++++, spinal fluid —; cell-count 6, globulin —, reduction +. Puncture normal, fluid clear.

Case 84.—History 364, W. U. No history of infection. No skin lesions. Reflexes sluggish. Physical examination; aneurysm of ascending aorta. Aortic mitral regurgitation. Feb. 17, 1913: Wassermann, serum ++++, spinal fluid ++; cell-count 6, globulin —, reduction +. Puncture normal, fluid clear.

Case 85.—Blood positive; spinal fluid negative. P. C. Infection six months ago. No lesions. Viscera, heart, eyes and reflexes normal. Feb. 21, 1913: Wassermann, serum ++++, spinal fluid —; cell-count 8, globulin —, reduction +. Puncture normal, fluid clear. Treatment, neosalvarsan.

Case 86.—History 497, W. U. Infection six years ago. No skin lesions. Heart, eyes and reflexes normal. Symptoms of duodenal ulcer. March 29, 1913: Wassermann, serum ++++, spinal fluid ++++; cell-count 24, globulin ±, reduction +. Puncture normal, fluid clear.

Case 87.—History 530, W. U. No history of infection. No skin lesions. Viscera, heart and eyes normal. Reflexes exaggerated. Symptoms of right hemiplegia. History of frequent miscarriages. May 9, 1913: Wassermann, serum ++++, spinal fluid ++++; cell-count 32, globulin +, reduction +. Puncture normal, fluid clear.

Case 88.—Blood positive; spinal fluid negative. History 525, W. U. History of infection in husband one year ago. No skin lesions. Viscera, heart and eyes normal. Reflexes exaggerated. Symptoms of epilepsy. May 11, 1913: Wassermann, serum ++++, spinal fluid —; cell-count 7, globulin —, reduction +. Puncture normal, fluid clear.

Case 89.—Blood positive; spinal fluid negative. P. C. Infection two months ago. Mucous patches, macular secondaries. Viscera, heart, eyes and reflexes normal. April 11, 1913: Wassermann, serum ++++, spinal fluid —; cell-count 4, globulin —, reduction +. Puncture normal, fluid clear. Treatment, neosalvarsan.

Case 90.—History 542, W. U. No history of infection. No skin lesions. Reflexes sluggish. Optic atrophy of both eyes; pupils fixed, right larger than left. Dizziness and headache. Romberg's symptom. April 22, 1913: Wassermann, serum —, spinal fluid ++++; cell-count 32, globulin +, reduction +. Puncture normal, fluid clear.

Case 91.—P. C. Infection two years ago. No skin lesions. Viscera, heart and reflexes normal. Slight headaches. Pupils

Digitized by Google

irregular; right larger than left; reaction both to light and accommodation. April 28, 1913: Wassermann, serum +, spinal fluid +++; cell-count 18, globulin ±, reduction +. Puncture normal, fluid clear. Treatment, neosalvarsan and mercury.

CASE 92.—Blood positive; spinal fluid negative. P. C. Infection three months ago. Mucous patches, inguinal adenopathy. Viscera, heart, eyes and reflexes normal. May 14, 1913: Wassermann, serum ++++, spinal fluid —; cell-count 6, globulin —, reduction +. Puncture normal, fluid clear. Treatment, neosalvarsan.

CASE 93.—Blood positive; spinal fluid negative. History 542, W. U. Infection two years ago. At present, mucous patches on mouth and throat. Viscera, heart, eyes and reflexes normal. April 18, 1913: Wassermann, serum ++++, spinal fluid —; cell-count 4, globulin —, reduction +. Puncture normal, fluid clear.

CASE 94.—Blood positive; spinal fluid negative. History 551, W. U. Infection two months ago. Maculopapular secondaries. Mucous patches on tonsils. Viscera, heart, eyes and reflexes normal. April 24, 1913: Wassermann, serum ++++, spinal fluid —; cell-count 6, globulin —, reduction +. Puncture normal, fluid clear.

CASE 95.—Blood positive; spinal fluid negative. P. C. Infection six weeks ago. Macular secondaries. Viscera, heart, eyes and reflexes normal. May 24, 1913: Wassermann, serum ++++, spinal fluid —; cell-count 6, globulin —, reduction +. Puncture normal, fluid clear. Treatment, neosalvarsan.

CASE 96.—P. C. No history of infection. Mucous patches on mouth and tonsils; ulcer on uvula. Viscera, heart, eyes and reflexes normal. March 10, 1913: Wassermann, serum ++++, spinal fluid —; cell-count 16, globulin ±, reduction +. Puncture normal, fluid clear. Treatment, neosalvarsan.

CASE 97.—Blood positive; spinal fluid negative. History 544, W. U. No history of infection. No skin lesions. Viscera, heart and eyes normal. Knee reflexes sluggish. Three miscarriages, one stillbirth. March 12, 1913: Wassermann, serum ++++, spinal fluid —; cell-count 4, globulin —, reduction +. Puncture normal, fluid clear.

CASE 98.—Blood positive; spinal fluid negative. History 549, W. U. Infection five years ago. Serpiginous syphilid on right arm, scalp and leg. Viscera, heart, eyes and reflexes normal. May 21, 1913: Wassermann, serum ++++, spinal fluid —; cell-count 12, globulin —, reduction +. Puncture, slight increase in pressure, fluid clear.

Digitized by Google

CASE 99.—History 562, W. U. Infection nine years ago. No lesions. Clinical symptoms of gastric crisis. Pupils irregular, left larger than right, no reaction to light in either. Fundus normal. Knee-reflexes absent. May 19, 1913: Wassermann: serum ++++, spinal fluid +; cell-count 19, globulin, +, reduction +. Puncture, increased pressure; fluid clear.

CASE 100.—Blood positive; spinal fluid negative. History 4585, W. U. Infection twenty years ago. No skin lesions. Punched-out ulcer on tongue. Viscera, heart, eyes and reflexes normal. May 28, 1913: Wassermann, serum ++++, spinal fluid —; cell-count 10, globulin - , reduction +. Puncture normal, fluid clear.

## SUMMARY

On account of the necessary length of this communication, we have concisely summed up the net results by dividing the cases into early and late: those in which infection occurred two years previously to our observation are classed as early; those in which infection occurred prior to that time as late.

*Early Syphilis.*—There were thirty-six of the early cases, three of which (Cases 9, 36 and 91) gave a positive serologic reaction in the spinal fluid and a high cell-count (8.3 per cent.). In Case 9 there were no clinical symptoms whatever, but the spinal fluid gave a cell-count of 30 and an increase of globulin. In Case 36, the reflexes were sluggish with no other clinical symptoms; the cell-count was 42 with an increase in the globulin content. The patient in Case 91 had an early syphilis and had had two salvarsan and two neosalvarsan injections together with adequate intramuscular mercurial treatment. The spinal puncture was incited by the sudden irregularity of pupils and headache. The fluid showed positive findings.

In none of these early cases giving a positive spinal reaction were there any active cutaneous manifestations. Four of this group of early infections gave a negative serologic reaction and a cell-count above 10 (Cases 17, 39, 45 and 96); the cell-count in these cases was 17, 12, 12 and 16, respectively, which in the presence of no clinical symptoms and a negative serologic test in the

Digitized by Google

spinal fluid, is probably of no pathognomonic significance.

*Late Syphilis.*—There were sixty-four of the late cases, twenty-one of which (34.4 per cent.) gave a positive serologic reaction (Cases 1, 5, 7, 8, 20, 21, 22, 23, 35, 42, 49, 56, 67, 71, 75, 79, 81, 86, 87, 90 and 99); sixteen of these showed definite clinical symptoms of cerebrospinal syphilis, ranging from headache and pupillary changes to definite symptoms of tabes and paresis (five were tabetic, four paretic and four hemiplegic), which leaves five cases with no clinical symptoms referable to the nervous stystem (Cases 1, 8, 49, 67 and 86). In Case 1 the patient had congenital lues with double iritis. In Case 8 the patient was apparently normal with the exception of a serpiginous ulcer of arm. In Case 49 there was a systolic murmur. In Case 67 there were no clinical symptoms whatsoever. In Case 86 the patient had symptoms of duodenal ulcer.

Of the twenty-nine patients showing cutaneous manifestations of acquired syphilis only one (Case 8) gave a positive spinal reaction (3.4 per cent.). In thirteen cases of the late group there was a cell-count in the spinal fluid above 10, with a negative serologic reaction; in seven a cell-count of 12; in one of 15; one of 17, and three of 20, all of which gave a negative globulin content except one which showed a slight increase. In Case 78, the cell-count was 43 with an increase of globulin. This patient also gave a negative Wassermann in the blood but was suffering from an aortic aneurysm, probably the result of an old cured syphilis.

Of the one hundred cases included in this report, only six had a positive spinal fluid[5] with no clinical symptoms of involvement of the central nervous system. One of these was congenital, two visceral and one showed late cutaneous lesions.

5. Positive spinal fluid, meaning a positive Wassermann reaction in the fluid with a cell-count above 10 and an increase of the globulin content.

Digitized by Google

During the course of our investigation, we were quite anxious to determine whether, if some of the spinal fluid was removed and an intravenous injection of neosalvarsan followed immediately, the fluid removed would not be replaced with a fluid surcharged with arsenic. To determine this we selected four cases of paresis. In each of these a spinal puncture was made and 10 c.c. of fluid removed immediately after which a full dose of neosalvarsan was administered intravenously. Within forty-eight hours, in two of these cases puncture was again made; and in the remaining two, in ninety-eight hours. The fluid was then examined for the presence of arsenic by the Gutzeit and Marsh methods fully controlled, with negative results in all four cases.

From the number of cases included in this report, one is not justified in being dogmatic, but the study seems to demonstrate that (1) only a comparatively small percentage of those infected by the *Spirochaeta pallida* give serologic and cytologic evidence of cerebrospinal invasions, and (2) when such an invasion does occur there are usually early clinical manifestations of it, which substantiate clinical observation.[6]

Before closing we wish to thank Dr. George Dock of the Washington University for his kindness in allowing us to use some of his cases from the wards, and also, Dr. Walter Fischel and Dr. H. N. Lyon of the Barnard Free Skin and Cancer Hospital, for the physical examinations of the patients from that institution.

## ABSTRACT OF DISCUSSION

Dr. F. G. Harris, Chicago: It has been shown that in a large number of cases of secondary syphilis there is involvement of the spinal fluid. The percentage of cases in which this occurs differs according to the reading of different observers, but we know that it is comparatively large. The cerebrospinal axis is affected early, in my experience, and these are the cases that later develop tabes and paresis and cerebrospinal syphilis. The spinal fluid is a true secretion, and our

6. In those patients on whom subsequent spinal punctures were made after intravenous injection of salvarsan and neosalvarsan there was no material change noted in the spinal fluid in the large majority of cases. We hope to report on this later.

Digitized by Google

antisyphilitic remedies circulating in the blood have little effect on it, as they do not reach it. As long as a case of syphilis shows a positive reaction of the cerebrospinal fluid, it should still remain under treatment.

Dr. David Liebertbal, Chicago: The assertion made by some that any case of syphilis in which the cerebrospinal fluid shows a positive Wassermann will, if left untreated, eventually develop into tabes or paresis or cerebrospinal syphilis is too broad. We have lost sight of the fact, apparently, that there is a natural healing process in connection with syphilis. If we review the statistics of cases of syphilis, treated and untreated, we shall find quite a large number of the latter in which the patients never developed any of these nervous affections. We are not in a position to prove that those cases showing a positive reaction in the cerebrospinal fluid will develop paresis or tabes: this can only be proved or disproved in the course of time. The authors stated that under the administration of neosalvarsan, the findings in the cerebrospinal fluid improved. I believe that mercury gives still better results. I use both salvarsan and neosalvarsan. but not to the exclusion of mercury. I do not limit my time of treatment of syphilitic patients to three years or to five years or even longer, and I advise them to keep themselves under observation for the rest of their lives, even in those cases in which the Wassermann has been negative for a year or longer.

Dr. H. G. Irvine, Minneapolis: I should like to call attention to the fact that these late syphilitic manifestations are very resistant to treatment. I should like to ask Dr. Buhman what his results have been in changing the positive Wassermann to a negative by treatment.

Dr. M. L. Heidingsfeld, Cincinnati: I should like to ask Dr. Buhman if these cases have been followed by subsequent spinal puncture. If so, with what result? Dr. Buhman's work exercises a therapeutic control over selected cases that would be otherwise entirely lacking. The therapeutic efficacy of salvarsan can hardly be questioned in these cases. Mercury may effect some good here and there. Four hundred years of experience has shown that it utterly fails in the vast majority of instances. Syphilis shows one peculiarity in that it often directs its influence against one special system, and I believe that for that reason we often see a positive cerebrospinal fluid, when the nervous system is attacked, and a negative blood Wassermann.

Dr. H. H. Hazen, Washington, D. C.: It has been noticed that an intravenous injection of salvarsan is often followed by a positive Wassermann in the blood in from seventeen to forty-eight hours. Will Dr. Buhman tell us if this is also true of the cerebrospinal fluid?

Digitized by Google

Dr. Rudolph Buhman, St. Louis: In reply to Dr. Harris I would say that in our work the blood and cerebrospinal fluid are obtained simultaneously, and that all the cases that did not give a positive blood or spinal-fluid reaction were thrown out. I cannot make any definite statement as to the effect of treatment on a positive spinal-fluid reaction, as I do not think that sufficient time has elapsed between the first and succeeding spinal punctures to draw any positive conclusions. In three of the cases, however, in which there was definite involvement of the nervous system, with positive blood, spinal-fluid and cytologic findings, the patients received five or six injections of salvarsan, and at the end of a year the findings were still practically unchanged with the exception of a lower cell-count. I have had no experience with the provocative treatment of the spinal fluid, but I have had experience with this treatment of the blood.

Digitized by Google

# ANGIOMA SERPIGINOSUM (INFECTIVE ANGIOMA OF HUTCHINSON), WITH A REPORT OF A VERY EXTENSIVE CASE

FRED WISE, M.D.
Chief of the Dermatological Clinic, Beth Israel Hospital; Assistant in Dermatology, Vanderbilt Clinic, Columbia University, College of Physicians and Surgeons
NEW YORK

Under the title "A Peculiar Form of Serpiginous and Infective Nevoid Disease," Hutchinson,[1] described and portrayed a rare affection of the skin, the lesions of which appeared to consist of superficial vascular dilatations, which spread peripherally and increased in size by the formation and coalescence of "satellite spots." He subsequently called attention to four additional cases[2] of this type, which had come under his observation, and called the disease "infective angioma."

Since Hutchinson's account of the disease more than a score of similar cases have been reported, chiefly by British observers. Crocker[3] described a case under the title "angioma serpiginosum," believing that this designation was better adapted to the clinical appearance of the disease. There seems to be a great diversity of opinion and a corresponding diversity of names in the descriptions of the case reports of the disease. In reading over the literature I find that, although the reports of all the cases bear clinical resemblances to each other in many minor and essential details, still there is by no means a

1. Hutchinson, Jonathan, Sr.: Articles Dealing with Angioma Serpiginosum, Arch. Surg., 1899-1890, i, Plate ix.
2. Hutchinson, Jonathan, Sr.: Arch. Surg., 1890, i, Plates xiv and xv; ibid., 1890-1891, ii, 71, Jamieson's Case; ibid., 1890-1891, ii, Lassar's Case; ibid., 1891-1892, iii, Plate ix, Tay's Case.
3. Crocker: Brit. Jour. Dermat., 1894, vi, 367.

Digitized by Google

uniform and stereotyped description of the cases, taken as a whole. In some of the reports the description of the disease is too meager to permit of its identification; in others the lesions are so ill-defined that doubts arise as to the propriety of including them under angioma serpiginosum; and, what is most important, in only a few cases have histologic studies been made to determine the actual changes taking place in the skin.

To make as thorough as possible a review of the literature, I have attempted to collect and abstract all of the cases published to the present time. In this list I have included J. C. White's case[4] of "so-called angioma serpiginosum," which, however, on histologic examination, proved to be an angiosarcoma, placing it under another category of vascular neoplasms. The list also includes a case shown "for diagnosis" by Dore, before the Dermatological Association of London in May, 1905; in this case the diagnosis of angioma serpiginosum was made by Pringle. To these I have added two cases in which the true nature of the affection was not recognized at the time the patients were presented. And finally, the list includes two cases, concerning which the diagnosis of angioma serpiginosum could not be made with any degree of certainty.

Three cases of the disease have come under my observation; the first was in a young woman whom I saw for the first time five years ago, who forms the subject of this report, and from whom the histologic studies were made. For the opportunity to study the other two cases I am indebted to Dr. Howard Fox.

## REPORT OF CASE

CASE 1.—*History.*—K. M., a woman aged 28, single, a native of Ireland, was seen by me for the first time, Dec. 26, 1908. The family history was negative; the father died of old age, the mother was living and in normal health; none of the family had suffered from any cutaneous disorders. The patient had always enjoyed the best of health; menstruation began at the age of 16 and had been normal since. The cutaneous

4. White, J. C.: Jour. Cutan. Dis., 1894, xii, 505.

Digitized by Google

eruption began at the age of 14, as a bright red patch, about the size of a 25-cent piece, on the right side of the neck, just above the outer end of the clavicle. There was no pruritus or other subjective disturbance, so far as she could recollect. When it first appeared, the patch was uniformly reddened, not raised above the normal skin and was free of scales; shortly after, the center of the lesion began to grow lighter and within a few weeks after its appearance, "the spot looked like and was considered to be a ringworm." Six or eight weeks later she noticed similar patches, together with very minute, punctate, bright-red spots, on both upper arms, on their outer aspects; subsequently similar lesions appeared on both thighs, legs, breasts and on the abdomen and the buttocks; gradually the process spread until nearly the entire integument was involved, only the palms and soles and the face and scalp remaining clear.

The mode of onset, or the primary lesions—if the patient's own account is to be taken into consideration—seemed to show a variety of clinical manifestations; the initial patch on the neck appeared in the shape of a uniformly reddened disk; on the arms and thighs there was a simultaneous eruption of punctate spots and bright-red, circular patches; while the breasts, the buttocks, the backs of the thighs and the abdomen presented, in the beginning of the disease, uniform sheets of a dark-red tint, in the midst of which could be discerned grouped, bright-red, pin-point spots, with little rings grouped in clusters of five or six, or scattered here and there in pairs or singly. On the breasts and the lower abdomen, instead of the punctate spots and the little rings, the patient observed "little red lines, some of them crooked, others curved into half-circles." She stated that after taking a warm bath, the rings and lines and red spots would stand out more distinctly; she also noticed that after a bath the skin looked as though it were covered with dusting-powder. On the legs, from the knees to the ankles, she stated that during the last few years the dark-red and purple rings and lines were turning yellow and brown.

Shortly after the patient first consulted me, she left for her home in Ireland, to return in February of this year, so that I saw her again after a lapse of five years. So far as I could judge, the eruption had remained practically unaltered, excepting that the rings seemed to be more distinct, the telangiectatic arborizations and the reticulated meshwork of dilated capillaries more pronounced, the pigmentation of the lesions on the legs more marked, than they were five years ago. On this occasion I sent the patient to Dr. Fordyce, who was kind enough to examine her for me; he made the diagnosis of angioma serpiginosum.

*Status Praesens.*—The patient is a robust, well-built young woman, at present occupying the position of governess. Phys-

Digitized by Google

ical examination fails to reveal any abnormality aside from the cutaneous lesion. The lower portion of the face is subject to acne vulgaris. The visible mucous membranes are free of disease and are normal in color. The urine is normal; the Wassermann and von Pirquet tests are negative. The blood examination reveals the following: Red blood-cells, 3,800,000; white blood-cells, 7,000; polynuclear neutrophils, 68 per cent.; polynuclear eosinophils, 2 per cent.; polynuclear basophils, 2 per cent.; large lymphocytes, 4 per cent.; small lymphocytes, 20 per cent.; mononuclears, 4 per cent.; abnormal white cells and abnormal red cells are absent. The color index is 1. Coagulation time is normal. The blood-pressure is normal.

*Description of the Eruption.*—Subjective Symptoms: Aside from a moderate amount of itching after bathing, there are no subjective symptoms, nor have there been any since the beginning of the affection.

Objective Symptoms: With the exception of the palms and soles, the backs of the hands and the face and scalp, the eruption involves the integument of the entire body. On superficial examination of the skin, viewed at some little distance, the picture which presents itself is that of a wide-spread, diffused, superficial vascular nevus. On closer scrutiny, however, no less than seven distinct and individual clinical types of lesions can be demonstrated. These are as follows: (1) bright-red, pin-point dots, barely visible to the naked eye, but, on account of their vivid red tint, standing out prominently and distinctly, in contrast to the surrounding, diffusely reddened skin; (2) areas of diffuse, uniform redness; (3) slightly raised, vascular papules; (4) delicate, vascular rings; (5) meshworks of irregularly curved and crooked lines; (6) pigmented lesions; (7) atrophic spots. There is present, also, on some portions of the skin, a diffuse, branny desquamation.

These efflorescences, diversified as they are in their color, configuration, size, localization and pattern-arrangement on the surface of the integument, have, with the exception of the atrophic spots, one thing in common; namely, each one of them is composed, apparently, of a congeries of ectatic capillaries, some of them flush with the surface of the skin, some of them sunken, others raised above the niveau.

I shall detail their distribution over the body, taking up each type of efflorescence in the order named before.

1. The puncta. Of these minute lesions I can find but two small groups; one on the anterior surface of the wrist is composed of three tiny, vivid-red spots, which, in spite of their small size, can be sharply differentiated from the surrounding reddish-pink skin; another group is situated on the front of the left thigh just above the knee, and consists of four bright spots, similar to those on the arm, but somewhat larger. These diminutive lesions are on a level with the surrounding

Digitized by Google

skin; pressure with the diascope does not alter the depth of their color.

2. Areas of diffuse, uniform redness. On the extensor surfaces of the hands and forearms and on the buttocks and posterior surfaces of the thighs are areas of diffuse, homogeneous redness; the depth and character of color varies somewhat in the different localities; on the forearms and hands the shade of red is like that ordinarily seen in persons with a poor circulation after exposure to moderate cold; on the buttocks and thighs the shade is from dark red to purple. On cold, wet days the depth of color is said to be more intense over the entire body. Pressure with the diascope over these areas makes the skin much paler, but not quite normal in appearance.

3. Slightly raised, vascular papules. These papules, varying in size from the head of a small pin to the diameter of a lentil, are scarcely raised above the level of the skin and are purplish red, simulating at a distance an old purpura. They do not occur in groups, but are scattered somewhat promiscuously on various portions of the integument, chiefly on the breasts, abdomen and thighs. Of these papules I can count thirty or thirty-five, most of them on the anterior aspect of the body. They are soft and compressible, but they do not pale appreciably under pressure. They resemble the small, scattered angiomas often seen on the back and chest of adults, save that they are not so well-defined as are the latter.

4. Delicate, vascular rings. These rings, probably the most striking units in the picture, are also the most abundant. They are most prominent over the sternum, portions of the breasts, the abdomen, the forearms, the legs, the sacral region and the outer aspect of the thighs. Clusters of them are also seen on the back, between the shoulder blades. A group of these rings over the sacrum, which had photographed itself on my mind's eye with especial distinctness when I first saw it five years ago, has not shown any appreciable change during the elapsed time. The peripheries of these rings vary in color from a faint pink to a light red; their size ranges from 1.5 mm. to 2 cm. in diameter. In some areas the rings are sharply defined, as on the chest, legs and abdomen, while on other parts of the skin, as on the breasts, they have a vaguely marked contour, the peripheries gradually shading off and being lost in the surrounding reddened skin. Roughly speaking, the rings are of two types: those having sunken centers and those whose centers are flush with their peripheries. The former are most abundant over the middle portion of the abdomen and over the epigastric region, on either side of the median line; the latter are found on the various parts of the body already enumerated. There does not seem to be any systematized grouping or arrangement of these vascular rings. In the left epigastric region I saw a group of four rings

Digitized by Google

arranged in a straight line from above downward, reminding one of a chain, four of whose links were separated from each other and laid down with short spaces between them. An elliptical excision of the skin on which these four links rested was made for biopsy purposes. Clinically, the centers of many of the rings show evidence of atrophy. The lesions are most distinct over the manubrium sterni, the sacrum, the lower abdomen, the outer aspect of the hips and a few on the forearms and the legs. Pressure with the diascope makes them fainter in color and less distinct in outline, but none of them fade entirely.

5. Meshworks of irregularly curved and crooked vascular lines. This type of efflorescence occupies chiefly the breasts, neck and anterior aspects of the shoulders. It consists of a reticulated arrangement of ectatic blood-vessels, with meshes of irregular outline, the color varying from red to purple. The strands which make up this retiform plexus vary in width and in outline; some are curved, some serrated, some elongated, some sinuous. On the lower and inner quadrant of the left breast is seen a serrated line about an inch long; on the upper quadrant a congeries of capillary dilatations is seen, grouped to form an irregularly outlined circle, which, however, in no way resembles the annular lesions already described. These retiform lines pale under pressure, but do not entirely fade.

6. Pigmented lesions. These are limited to the legs and ankles. They are most pronounced on the calves and middle portions of the legs, from just below the knees to the ankles. The pigment ranges from a yellow to a dark-brown tint; it is most marked in the annular lesions, the peripheries of which are for the most part, darkly stained, while the centers of many of them are lighter in color. Some of these annular lesions are completely hidden by a disk of uniform, dark-brown pigmentation. The skin intervening between the annular lesions is also pigmented.

7. Atrophic spots. Viewed with the light striking the body at an angle, certain areas of the skin show evidences of atrophy. These areas are most marked on the neck and breasts and they bear some resemblance, in a general way, to the reverse side of a fine nutmeg-grater; that is, the surface of the skin presents areas showing more or less regularly disposed, whitish, glistening depressions, somewhat irregular in outline, most of them being ovoid or elliptical in shape.

A fine branny desquamation is present on the chest, abdomen and upper and lower extremities. It is most pronounced over the breasts and in regions where the clothing constricts the body, as around the waist; an hour after a warm bath, the scaly appearance is intensified. On the neck and breasts, when the patient refrains from the use of an ointment for several days, the skin assumes the appearance seen in cases of mild ichthyosis.

Digitized by Google

The second and third cases were patients of Dr. Howard Fox. Both of them were presented before the New York Dermatological Society, one by Dr. George H. Fox, the other by Dr. Howard Fox. At the time of presentation, the diagnosis of angioma serpiginosum was not made in either case, but in one of them (Mrs. S.), several members of the society agreed that the eruption was a type of angioma. Through the kindness of Dr. Howard Fox, I had the opportunity to see both of these patients during the first week in April, 1913, and found that in both cases the lesions were those of angioma serpiginosum.

CASE 2.—Mrs. S. was shown at the October, 1910, meeting of the New York Dermatological Society, by Dr. Howard Fox,[5] as a "case for diagnosis." The report was as follows:

"The patient was a German woman, aged 38, who had applied for treatment of tuberculo-ulcerative syphilid of the chest. In examining the patient, the peculiar eruption for which she was presented was incidentally noticed. The patient had been very delicate up to her ninth year. She had been married fourteen years and had had four apparently healthy children. Between the first and second births, she had had one miscarriage. The eruption (for diagnosis) was confined entirely to the thighs and legs and had first been noticed eighteen years previously. It was first noticed on the inside of the thighs and had steadily increased in extent up to the present time. None of the lesions had ever disappeared, according to the patient's statement. There had never been any constitutional symptoms and she had never undergone any treatment for this condition. The eruption, which was roughly symmetrical, consisted of yellowish, punctate macules, grouped together to form more or less reticulated patches. The lesions were not raised and apparently not scaly, although the patient insisted that they had at first been covered by fine scales. She also thought that the patches were redder during the first few years of their existence. Many of the individual lesions presented a somewhat shiny and atrophic appearance."

In the discussion, "Dr. Johnston thought it might be an angiosarcoma; Dr. Jackson agreed with Dr. Johnston, that it was probably a vascular trouble of angioma type and Dr. Fordyce said it was a unique case and suggested angioma."

In this report, the statement was made that the eruption was confined to the thighs and legs; but when I examined the

5. Fox, Howard: Jour. Cutan. Dis., 1911, xxix, 181.

Digitized by Google

patient, a few weeks ago, I was surprised to see that the process had extended considerably during the last three years, as the eruption was present not only on the thighs and legs, but also on the shoulders, arms, forearms, abdomen and hips. The eruption as a whole consisted of isolated and coalescing areas of efflorescences, apparently composed of a reticulated meshwork of dilated vessels, not raised above the level of the skin. The strands of the network are light red, and in places where some of these strands of dilated vessels have fused or have crossed each other, the appearance of an irregularly outlined macule, ranging in size from a pin-head to a split pea, is given. On both arms, over the biceps muscles, are groups of from pin-point to lentil-sized, purpura-like macules, the larger ones slightly raised above the level of the skin; none of these lesions, either the reticulated or the macular type, disappears under the pressure of the diascope, although they all become considerably paler. On the thighs and legs an unmistakable atrophic and shiny appearance is evident when the light strikes the skin at an angle. On examination with a lens, the little islands of skin enclosed in the network of dilated vessels give the impression of being somewhat depressed below the level of the surrounding skin.

On the outer aspect of the right thigh are seen a few groups of small annular lesions; pigmented spots are absent. On the same thigh, above the knee, there is a patch of diffuse, reddish-pink, slightly scaly erythema, about the size of a silver dollar and somewhat resembling a patch of acute erythematous lupus; the patient states that this patch, together with the spots on the upper arms, have made their appearance during the last six months. All of the affected areas are covered by fine, branny scales; at times there is moderate itching. A biopsy was not obtainable.

CASE 3.—MRS. L. W. was presented before the New York Dermatological Society, December, 1911, by Dr. G. H. Fox,[6] as a case of diffuse macular atrophy of the skin.

"The patient was a Russian woman, aged 38, who had been in the United States for nineteen years. During this time she had suffered a good deal from indigestion. She was the mother of six rather delicate children. No member of the family had ever suffered from any similar disease of the skin. The eruption on the breasts was first noticed about ten years ago, that on the trunk and extremities about two years ago. The eruption was worse in winter than in summer. It had only recently occasioned much itching. There had never been any oozing according to the patient's statement. Examination showed the presence of large, diffuse patches on the back, chest, arms and legs, which were reddish, dry and slightly scaly and presented numerous small atrophic spots. On the breasts there was a reticulated, macular atrophy, somewhat resembling

6. Fox, G. H.: Jour. Cutan. Dis., 1912, xxx, 208.

Digitized by Google

the telangiectases following Roentgen-ray treatment. At a certain angle of light, the atrophic spots had a white, shining appearance and a tendency to linear distribution. The elbows and knees presented the usual picture of diffuse atrophy of the skin. The patient was well nourished and appeared to be in good general health. She had never been treated by the Roentgen ray."

In this patient, whom I examined on several occasions during the month of April, the most striking features of the eruption were the large, diffuse, irregularly outlined areas of skin, presenting a network of reddish vascular dilatations, together with a glistening, atrophic appearance of the affected areas of skin. There was also a moderate amount of fine, branny desquamation and the patient complained of attacks of occasional, mild itching. The condition was most marked on the breasts, where it had first made its appearance about ten or twelve years ago. The upper arms, the thighs and legs, parts of the abdomen, the buttocks and the lower portion of the back presented large, irregular, vaguely outlined, reddish and violaceous areas of dilated capillaries, which were not raised, and which, on pressure with the diascope, would pale slightly. On the breasts, elbows and knees the atrophic appearance was more marked than elsewhere. I was unable to find other types of efflorescences—there was no evidence of puncta, vascular nodules, annular lesions or pigmented spots.

According to the patient's statement, the vascular dilatations were preceded by patches of diffusely reddened skin, somewhat rough and scaly, in the midst of which would appear a group of branches and forked telangiectases, the diffuse redness gradually fading and giving place to a whitish, glistening appearance; there has been no evidence of retrogression; fresh areas of the integument have become involved in the process during the last few months; she complains of only slight itching and states that, aside from the cosmetic point of view, the eruption gives her no trouble.

In studying these three cases from a clinical point of view, we find that they present a number of striking similarities to each other, both subjectively and objectively. The subjective disturbances in each of the patients manifested themselves by such a moderate degree of pruritus that the symptom may be dismissed as a negligible item, requiring no further comment. Objectively, the most salient features of the three cases may be briefly summarized as follows:

The eruptions were not preceded by a port-wine mark or other form of nevus, or any cutaneous abnormality;

Digitized by Google

in all three, no etiologic factors were ascertainable; in each case the eruption began insidiously and progressed slowly, without any apparent exciting cause; the general health of the patients remained unaffected, despite the inroads of the cutaneous trouble (in Case 2 it will be noted that the skin affection appeared before the patient was infected with syphilis); different portions of the integument were attacked during the course of the disease, the patches appearing independently of each other, but usually symmetrically arranged on either side of the body; the eruption did not spread serpiginously from a single primary or parent lesion; but the individual patches, appearing on various portions of the integument, independently of each other, had their inception in a variable number of primary or parent lesions; these primary lesions were destined to form the centers of diffuse patches of various extent; each of them was a nucleus from which the vascular dilatations, either punctate or macular or linear in type, would gradually spread by means of outlying or "satellite spots," as they were called by Hutchinson; these satellite spots would then coalesce, forming the reticulate or gyrate or papular types of efflorescence; in each case, the little islands of skin formed by the branching and coalescence of the blood-vessels gave the appearance of being atrophic spots, slightly sunken below the level of the surrounding skin; this atrophic and glistening appearance was most marked in the older patches and was very slight or altogether absent in the more recent areas of involved skin. Another point of interest is that these three cases occurred in women, in whom the malady made its appearance at the ages of 14, 20 and 28 years, respectively.

## HISTOLOGIC REPORT

BY S. POLLITZER, M.D., NEW YORK

When Dr. Wise was good enough to refer his case of angioma serpiginosum to me for histologic study, it was agreed that he was to confine his share of the work to the clinical description of his case, with a comparative study of the cases in the

Digitized by Google

literature, from a clinical point of view, while the histologic study was to be left to me. In other words, we were to do our work independently and to that extent without prejudice. I had an opportunity, however, of examining the patient, and while I do not believe that all the cases in the literature published under the name of infective angioma or angioma serpiginosum are properly included in one class, there is no doubt in my mind that Dr. Wise's case, from a clinical point of view, is an instance of that disease.

The material for the histologic study consisted of three pieces of skin cut from different parts of the surface and suitably fixed. This set of specimens, when sectioned, showed at a glance such marked differences from the appearances anticipated from a study of the meager literature of the subject, and above all, such grave changes in the epidermis about which previous writers had made no mention at all, that I feared that possibly the specimens had not been promptly fixed after excision, and accordingly, I requested Dr. Wise to procure some more material. The second set of specimens consisted again of three pieces of tissue, cut from typical areas and immersed instantly into Zenker's fluid, Fleming's solution and alcohol, respectively. These specimens showed the same changes that had aroused my astonishment in the first set of specimens, demonstrating, as Dr. Wise had assured me, that the first set of specimens had been properly handled.

The second set of specimens was cut from: (1) the border of an erythematous patch of recent origin on the leg, fixed in alcohol; (2) a group of ringed lesions on the abdomen, fixed in Zenker's fluid; (3) a ringed lesion with apparent atrophy in the middle, from the thigh, fixed in Fleming's solution.

These specimens, embedded in paraffin, were cut and mounted to some extent serially and stained in various ways. I take pleasure in acknowledging my obligation to Dr. Hillman of the Post-Graduate Medical School, who supervised the technical preparation of the specimens, for his interest in the work, and the excellent sections which he prepared. We found that sections stained with eosin-methylene blue (Mallory) and phosphotungstic acid-hematoxylin gave the most useful pictures. Other stains, such as polychrome methylene blue, von Gieson, polychromeorcein, and special stains for elastic tissue, etc., were also employed.

The specimens all showed the same kind of lesions, the differences being only those of degree. In all, the changes were limited to the subpapillary and papillary layers of the corium and the epidermis. In the early lesions (the alcohol specimens from the leg) the changes in the subpapillary layer consist of a moderate lymphocytic perivascular infiltration, with proliferation and swelling of the endothelial layer of the vessels. In some of the capillaries the number of endothelial cell-nuclei seems, on comparison with normal vessels in other parts of

Digitized by Google

the section, to be increased to half again the normal number. The swollen endothelium projects well into the lumen of the capillaries, but nowhere is there any evidence of occlusion of the vessels. The perivascular infiltration consists of cells of the type of lymphocytes, arranged sometimes in a single row, along the adventitia, sometimes increased to form a collar of moderate thickness. Here and there a plasma cell and a few mast-cells are visible. In the papillary layer the changes are more marked; we find at various points in the section one or more papillae distended with cells that infiltrate the widely dilated perivascular lymph-spaces, the capillaries themselves abnormally sinuous, so that a single capillary loop of the papilla may be cut transversely or obliquely a number of times, giving the appearance of an increase in the number of vessels in the papilla; the endothelial nuclei, swollen and increased in number. The epidermis over the area involved presents marked evidences of edema; the basal layer of cells is most strikingly altered; the sharp line of demarcation between epidermis and corium is often disorganized, the lymphocytic cells of the papillary layer intermingling with the cells of the rete; the latter are separated from each other by widely dilated spaces, the intercellular bridges having ruptured and in some places the cells themselves are distended with fluid so as to present a dilated shell of cell membranes, without any remains of cytoplasm, the small, compressed nucleus floating free in the clear fluid contents of the cell. In other words, we have here a high degree of intercellular and intracellular edema. The evidence of this edema, in the form of widely dilated lymph-spaces and vesicular nuclear cavities, extends for a considerable distance into the rete and in some places almost up to the stratum granulosum; over such an area the stratum granulosum and the horny layer show the parakeratotic appearances common in an epidermic edema.

The specimens from the non-advanced lesions exhibit virtually the same class of changes except that they are more pronounced. The infiltration is far more extensive, occupying in the sections an area corresponding to from four to eight papillae and extending down to the lowest portion of the subpapillary region, where it terminates in a fairly sharp line. This definitely circumscribed area of infiltration is made up mainly of lymphocytic round cells and in addition to a few pigment, mast and plasma cells, shows a small number of polynuclear cells. The latter invade even the epidermis to a slight extent. In these more advanced lesions, the changes in the capillaries are also more marked. We find the same endothelial proliferation, but there is also a certain amount of capillary new formation. In places, three, four or five capillaries may be seen in close proximity, running parallel to each other and vertical to the surface, from the subpapillary plexus to the epidermis. Both from their greater number and from

Digitized by Google

the thin, delicate walls of some of these capillaries, it is evident that many of them are newly formed. They resemble the capillary new formation seen in granulation tissue. The sections do not extend to the hypoderm, but in the lower portion of the corium a few larger vessels are seen which exhibit a considerable degree of endothelial proliferation.

The elastic fibers through the sections seem normal. The collagenous tissue, however, in the areas of greatest infiltration, has suffered a certain amount of alteration—broken, clumped or twisted fragments which take acid stains less intensely than normal tissue, indicating a degeneration which possibly is a factor in the production of the clinical appearance of atrophy.

In the epidermis, the lower layers of the rete exhibit in places the same intercellular and intracellular edema as described before. The edema, however, stops short of producing a true vesicle in the epidermis. There is neither necrosis nor colliquative degeneration of groups of cells, such as we find when true vesicles are formed. The injury to the epidermis is sufficient, however, to explain the clinical appearance of minute areas of atrophy, which must follow the subsidence of the active stage of the process described.

Over the middle of the papillary infiltration, the epidermis is generally found compressed mechanically and reduced in thickness to a layer of four or five rows of cells, the papillae being obliterated.

To sum up the minute anatomical features of this case, we have a progressive, perivascular infiltration of the papillary and subpapillary layers in circumscribed areas, corresponding to the small, deep-red papules and the rings of the annular lesions. In these areas there is a proliferation of capillaries as in flammatory tissue and there is marked endothelial proliferation and swelling. The elastic tissue appears normal, the collagenous tissue sometimes degenerated. The epidermis over the areas of infiltration shows a high degree of intercellular edema, affecting the lower layers of the rete principally but extending with diminished intensity as far as the stratum granulosum. The lower layers of the rete are invaded by the lymphocytic cells from the papillary infiltration; a few polynuclear leukocytes are seen, and many of the epidermic cells have undergone a vesicular and hydropic degeneration. The epidermis as a whole is compressed at the highest point of the infiltration and

Digitized by Google

reduced to less than half its normal thickness. The stratum granulosum is thinned or absent; there is no sign whatever of extravasated blood as in a hemorrhagic process, or of widely dilated capillaries and veins, as in some forms of vascular nevus.

From this description it is evident, on the one hand, that the essential process is a low-grade inflammation, affecting primarily the capillary areas of the papillary and subpapillary regions, with secondary effects in the epidermis; and on the other hand, that the process is in no sense an angioma, and to this extent, the name given to the disease is not appropriate. The question arises, are we dealing with what has been called angioma serpiginosum, or with a disease hitherto unknown? The question must be examined in its histopathologic as well as in its clinical aspects.

It is unfortunate that the few histologic examinations reported in the literature are made for the most part by general pathologists, who notoriously are not expert in the special field of dermatopathology. From the dermatologist's point of view, many of these reports are simply useless. A few definite statements may be culled from some of these accounts, however, which have a bearing on our question. Roberts,[7] who has given us the best histologic description of a case, described and pictured cavernous vascular spaces in the papillary layer, and expressly stated that there was a total absence of inflammatory reaction, and none but mechanical changes in the epidermis. Jamieson[8] stated that he found the epidermis normal and that "the vascular loops of the apices of the papillae were dilated into wide spaces." He makes no mention of any inflammatory condition and regards the condition as "a very superficial capillary nevus." In Sequeira's[9] case "the epidermis was of normal appearance; the capillaries and most of the venules of the papillary zone were greatly engorged; the capil-

7. Roberts: Brit. Jour. Dermat., 1897, ix, 180.
8. Jamieson: Brit. Jour. Dermat., 1898, x, 325.
9. Sequeira: Brit. Jour. Dermat., 1912, xxiv, 355.

Digitized by Google

laries and venules of the deeper layers of the dermis were engorged; there was no infiltration by free cells."

It is evident that these three cases present a condition essentialy similar; a non-inflammatory process, characterized by capillary ectasia, which may be even cavernous; a condition apparently not different from the common hemangiectatic nevus, but vastly different from the condition found in our case. Are we justified in assuming that they differ from all of the other cases described as angioma serpiginosum? I think not. In studying the clinical side of the question, we are again confronted with a certain lack of definiteness in the descriptions. Many of the cases in the literature are mere outline descriptions of cases presented at some clinical meeting, and necessarily brief. But the main difficulty is to determine what was the real condition when the terms "vascular" and "telangiectases" are employed. There is a natural tendency in hurried descriptions to substitute these anatomic terms for the clinical or descriptive term "erythematous." From the clinical side, it is a matter of not much consequence which terms we use; but for an understanding of the underlying condition, it is of the greatest importance. Telangiectases are visible, for instance, in advanced cases of rosacea; they are not visible in vascular nevi, though we know they are present in that condition. In the report of a case of ringed eruption presented by Morris[10] at the London Dermatological Society, while the terms "telangiectases" and "hemorrhagic" were employed in the description of the case, several of the members expressed the opinion that the lesions were erythematous, owing to inflammatory hyperemia, rather than to permanent changes of the lumen of the vessels, or to hemorrhage.

These considerations illustrate the difficulties encountred in attempting to fix the proper relations of the

10. Morris: Brit. Jour. Dermat., 1896, viii, 122.

Digitized by Google

case which Dr. Wise has presented. It seems beyond question that some of the cases described as infective or serpiginous or retiform angioma belong to the group which includes the case here discussed. It seems to me equally certain that there has been included in this group another class of cases with similar clinical appearances, which is of an entirely different nature anatomically and etiologically. One is a progressive, superficial capillary hemangioma; the other a subacute inflammatory process, limited to the papillary and subpapillary layers, most probably of toxic origin.

A word as to Majocchi's[11] purpura annularis telangiectodes and its possible relation to the disease here described. Dr. Wise has sufficiently differentiated the two diseases on clinical grounds. From the point of view of the pathologist, the absence of the characteristic changes in the epidermis, the nature of the infiltration in our disease, and the absence of hemorrhage alone suffice to separate the two diseases completely. The unique case of universally disseminated vascular nevus which I described[12] in 1897 is often referred to, in connection with angioma serpiginosum; there is no relation between the two conditions; mine was a clear case of congenital telangiectases, an extraordinarily widespread vascular capillary nevus. White's case of "angioma serpiginosum" with a histologic study by Darier and Councilman and Bowen, was found to be an angioplastic reticulated sarcoma, a condition which we should to-day probably call perithelioma. Clinically it was not a clear case of angioma serpiginosum and histologically it was entirely different. In response to my inquiry, Dr. White recently informed me that he had heard that the patient was still living and that his cutaneous disorder had long ago disappeared, leaving scars.

---

11. Majocchi: Arch. f. Dermat. u. Syph., 1898, xliii, 454; Gior. ital. d. mal. ven., 1896, li.

12. Pollitzer: Nevus Angiectodes Disseminatus, International Atlas of Rare Skin Diseases, 1897, Plate xlii.

Digitized by Google

DESCRIPTION OF THE DISEASE

Crocker[13] defines angioma serpiginosum as "a disease in which minute vascular points are formed in rings or other groups, which spread at the borders, while fresh points are continually developing beyond them."

In describing the appearance of the eruption, he says that:

> It consists of minute, bright-red, vascular points embedded in the skin, "like grains of cayenne pepper." These are formed into small groups which spread peripherally, clearing up in the center, and thus forming rings not exceeding half an inch or so across, but in the border the vascular dot character of the components of the ring is always preserved. Fresh points are continually developing a little beyond the patches ("infective satellites," as Hutchinson calls them), and thus the process is continually repeated, and, the rings meeting, large areas of disease with gyrate borders are produced. Scattered "cayenne pepper" dots, and lines of them, are seen beyond the main patches, and the skin between the rings is generally pinkish in hue. The dots vary from the diameter of an ordinary pin's head to some so small as to be visible only with a lens. Most of them are bright and pale on pressure, but the larger-sized ones are purplish in hue and often unaltered by pressure. In three out of the first four cases scarring was certainly absent, and Hutchinson was not sure about it in the fourth case.

This definition and clinical picture coincided fairly well with the seven or eight cases of the disease, descriptions of which Crocker had at his disposal at the time. There were some deviations from this classical type of the disease, however, as shown by the cases in which there is a complete absence of the minute red spots on which Hutchinson and nearly all subsequent reporters laid so much emphasis; a case of angioma serpiginosum without the "cayenne pepper" spots was reported by Francis[14]; another one by Dockrell[15]; while of the three cases embodied in this paper, I was able to find distinct vascular puncta in only one of the patients. The great majority of the cases, however, begin by the formation of

13. Crocker: Diseases of the Skin, 1904, ed. 3. ii, 970.
14. Francis: In International Atlas Rare Skin Diseases, 1895, Plate xxxiv.
15. Dockrell: Tr. Med. Soc. London, 1898, xxi, 354.

Digitized by Google

little groups of very fine deep-red and livid-red vascular puncta, which so arrange themselves as to form small annular lesions, or vascular, flat papules, or irregular lines, varying in length, breadth and outline. By means of a very slow and insidious extension from the edge of existing lesions, the process advances, resulting in the junction and coalescence of outlying lesions, to form little rings, or larger gyrate figures, or arborescent lines which are destined to become a reticulated network of vascular dilatations. Independent groups of lesions, forming the nuclei for fresh patches of the disease, may appear on different parts of the skin; only a small area of the skin may become affected, or nearly the entire surface of the body (as in one of my cases) may become involved in the process. As to the mode of extension of the disease, I think this is still a matter of conjecture. In this connection, Joseph[16] says that it is common enough to find a single angioma at birth, which increases in size with the growth of the part of the body on which the nevus is located; now and then an increase in its size takes place through the peripheral extension of its edges. In other cases, however, after a few weeks, several new angiomas may appear, which may assume an annular arrangement and increase in size independently of the body growth, in the part on which they are situated; or a number of independent, isolated lesions may coalesce, thereby sometimes producing a serpiginous appearance. The center of the patch becomes lighter in color and may even involute throught atrophy; at the periphery an extension of the angioma takes place—angioma serpiginosum. At other times, however, the peripheral extension takes place without the occurrence of central involution. Such cases are exceedingly rare and only a few instances are found in the literature, contributed by Hutchinson, Jamieson, Crocker, White and Francis. Equally rare as the foregoing is the type of multiple eruptive extension of an angioma. Such a very

16. Joseph: In Mracek: Handbuch der Hautkrankheiten, iii, 565.

Digitized by Google

rare form is congenital and may cover almost the entire cutaneous surface, remaining unchanged through life. But one case of this type is described in the literature, reported by Pollitzer. This peculiar affection was noticed in the first or second week after birth, in a man of 25, and had shown practicaly no changes since its appearance.

REVIEW OF THE LITERATURE

The first five cases of the disease were reported by Jonathan Hutchinson, Sr., from 1889 to 1892. To the present time twenty-two cases of angioma serpiginosum have been recorded, which number, together with the three patients included in this report, makes a total of twenty-five cases. * * * * * * *

Here follows a review of 25 cases from the literature, appearing in full in the article as completely published in the *Journal of Cutaneous Diseases.*

Etiology: Nothing definite is known of the etiology of angioma serpiginosum. In five of the reported cases a port-wine mark was considered to be the starting point of the eruption. One of the cases has been ascribed to sudden fright; another began after the rupture of minute muscles of the skin during gymnastic exercises. It is not improbable that disturbances of the internal secretions play a rôle in the causation of the malady.

Incidence of Age, Sex, etc. Of the twenty-five reported cases, eighteen occurred in females, five in males, and in two the sex is not mentioned. The ages of the patients ranged from infancy to 60 years. The disease made its appearance from birth to the tenth year, in fourteen cases; from the tenth to the twentieth year, in six cases; from the twentieth to the thirtieth year, in four cases, and from the fiftieth to the sixtieth year, in one case. Five of these cases presented ordinary vascular nevi at birth; in seventeen the disease was acquired; in three of the cases the duration of the disease is not mentioned.

Digitized by Google

Initial lesion: Aside from the cases beginning as congenital nevi, the initial lesions have been described as small red spots; reddish patches; diffuse redness and puncta; radiating telangiectases; spots and lines; telangiectases and pigmentations; nevoid patches; reddish puncta; cayenne pepper spots, and magenta grains.

Distribution: With the exception of the scalp, all portions of the integument have been attacked by the eruption.

Rarity of the Disease: The American literature contains the reports of only three cases, including White's case, which, however, was an angiosarcoma; the other two cases were reported by Wallhauser[17] and by Engman and Mook.† All other cases have been reported from Great Britain. Presumably the disease occurs in other countries, but has either not been recognized or has been described under various titles which do not readily permit of its identification, from a perusal of the literature.

Course of the Eruption: This varies greatly, but in all cases it is characterized by an extremely slow and insidious advance. Periods of quiescence, during which no new lesions appear, have been described as occurring in the majority of the reported cases. Several authors have laid emphasis on the fact that retrogression of the patches may take place, resulting in a normal appearing skin at the site of the lesion; or a smooth, blanched area of skin may follow the disappearance of the telangiectases, or, most commonly, the areas in which retrogression of the lesions has taken place, give the impression of being stippled over with small, glistening, atrophic spots, producing a somewhat lichenified appearance of the affected integument.

While most of the cases show a continuous, progressive and extensive evolution, in others an arrest in the progress of the eruption may take place; Dockrell described a patient in whom the lesions remained unchanged until the sixteenth year, when they began to

17. Wallhauser: Jour. Cutan. Dis., 1909, xxvii, 353.
† Engman and Mook: Jour. Cutan. Dis., 1913, xxxi, 333.

Digitized by Google

disappear spontaneously; in Dore's[18] patient, the disease had remained stationary for five years.

Types of Eruption: In a general way, the eruption of angioma serpiginosum may be classified under five types: (1) cases in which the efflorescences are composed wholly of minute puncta, closely grouped and forming large patches; (2) cases in which the entire eruption is comprised of patches resembling the ordinary congenital vascular nevus; (3) ringed, gyrate or annular types; (4) reticulated types, and (5) cases in which these various types occur simultaneously.

Subjective Symptoms: These have been entirely absent in the majority of the cases. In some of them, the patients complained of a trivial degree of pruritus; a few of them had hyperesthesia of the affected portions of the body; several authors report the occurrence of chilblains of the hands and feet. On the whole, there is a remarkable absence of subjective symptoms in this disease.

Histopathology: The histologic studies of angioma serpiginosum have been very meager and but little light has been thrown on the subject, as to the origin and nature of the malady. The one case in which the microscopic appearances were thoroughly studied by Darier and by Councilman and Bowen—White's case of so-called angioma serpiginosum—proved to be, in reality, an angiosarcoma. Jamieson's case (reported by Hutchinson) showed a "very superficial capillary nevus, spreading by the formation of satellites." In Robert's case, "the morbid process essentially consisted, so far as the microscope could detect, in the dilatation of these vessels (the blood capillaries situated immediately beneath the epidermis) into spaces confined by a well-developed endothelium, the cells of which bulge into the cavities thus formed." Histologic studies of Sequeira's case did not reveal any definite characteristics peculiar

18. Dore: Brit. Jour. Dermat., 1905, xvii, 224.

Digitized by Google

to the disease; he found "some oval bodies, immediately beneath the epidermis, lying in unlined spaces, the significance of which could not be determined."

### RELATED DERMATOSES

The clinical characters of angioma serpiginosum are so striking that there is little likelihood of the disease being confounded with other dermatoses. In going over the literature, however, I found that several cutaneous disorders which bear resemblances, clinically, to angioma serpiginosum, have been reported; chief among these is the disease described by Majocchi in 1896, under the title of purpura annularis telangiectodes (telangiectasia follicularis annulata). In this disease the occurrence of purpura at once places it under another group of cutaneous disorders; no extravasation of blood takes place in angioma serpiginosum. Aside from the pupuric elements in Majocchi's disease, however, there seems to be a striking clinical resemblance between the two dermatoses. Majocchi's disease begins usually on the extremities as small, dark-red patches, which, on closer examination, are seen to be composed of aggregations of from pin-point to pin-head sized, dark-red spots, which do not disappear or change in size under pressure. After persisting as such for a time, they develop into annular and striated plaques, having a pale-brown center with a peripheral ring of dark-red, bluish or reddish-brown spots, some of which may also be seen in the interior of the plaques. After a lapse of months, the lesions may disappear entirely, leaving no trace behind, although recurrences are apt to take place. In one of Brandweiner's[19] cases the lesions appeared on the oral mucous membrane. There were no subjective symptoms throughout the disease. Histologically, the lesions are composed of the smallest capillaries and precapillary ectasia, accompanied by slight hemorrhages; some of the dilated vessels contain a few round cells; here and

19. Brandweiner: Dermat. Wchnschr., 1912, lv, 42.

Digitized by Google

there are seen isolated spindle-shaped elements, which probably represent hypertrophied adventitious tissue. The disease may appear in either sex and at any age, but it is most common in the young. As to its etiology, it is probably a vasomotor trophic disturbance.

In Majocchi's original description, he formulates seven general characters of the disease: (1) pink and livid-red spots, made up of capillary dilatations, followed by hemorrhages, without preexisting hyperemia, without palpable infiltration of the skin and usually in connection with the hair-follicles; (2) slow development and increase of the lesions; (3) constant, eccentric growth of the spots, whereby regular rings are formed; (4) symmetrical disposition of the eruption; (5) primary seat of the eruption on the limbs, especially the lower extremities; (6) usual observance of pruritus and other sensory disturbances, and (7) resolution by moderate degree of atrophy with achromia of the skin, sometimes with alopecia. Majocchi also described three stages of development: (1) telangiectatic stage; (2) hemorrhagico-pigmentary stage, and (3) atrophic stage. Histologically, he found a small-celled infiltration in the neighborhood of the blood-vessels within the livid-red spots; there was atrophy of the hair-roots and hair-follicles and absence of the sebaceous glands through atrophy; thinning of the stratum corneum and stratum granulosum.

Crocker evidently regarded the two diseases as being identical. In his text-book, under the heading of "Anatomy" of angioma serpiginosum, Crocker[20] speaks of Majocchi's cases of telangiectasis follicularis annulata and his own case of angioma serpiginosum as though no difference existed between the two diseases. He says (referring to the histology of angioma serpiginosum), "Majocchi found the ectatic capillaries round the follicular orifices."

20. Crocker: Diseases of the Skin, 1904, ed. 3, ii, 972.

Digitized by Google

T. Colcott Fox[21] also classes both diseases under the same heading, though he does not definitely state that he considers them to be identical. Referring to the various types of nevi, he says:

Perhaps I may, under nevi, include the group of cases denominated "infective angioma" by Hutchinson and "angioma serpiginosum" by Crocker, though the latter term is not fully expressive of the condition. These cases are characterized by minute vascular points, formed in rings or other groups, which spread at the borders, while fresh points are continually developing beyond them. Thus they form delicate ringed and gyrate patterns. They generally begin in early life. There are a number of cases recorded. Walsh's case was a curious serpiginous angioma, but probably different from Hutchinson's type. Majocchi described four ringed cases under the term "purpura annularis telangiectodes," and mentions a fifth. The first reminds one of Pollitzer's case. A child was born with harelip, incomplete right ear, double right thumb, asymmetrical face and uniformly red skin. The general redness disappeared in two weeks, leaving red, dilated vessels, punctate, lentil-seed, or tracts—not disappearing on pressure —more numerous on the back than on the chest, and scanty on the extremities. There was a ring formation of from 0.5 to 2 cm. in diameter, in some places on the back confluent. The center of the rings was atrophied and pigmented. The child died at the end of the third month. The other three cases, in men aged, respectively, 21, 22 and 25, commenced at about 19, 18 and 25 years. The description is very suggestive of Hutchinson's infective angioma.

F. Parkes Weber[22] makes the following statement:

I suspect that various forms of livedo reticulata and allied cases have been described under many names, including "purpura annularis telangiectodes," and that possibly some other cases described under the latter name may really have been examples of Hutchinson's "infective angioma" ("serpiginous nevus").

The latest contribution to the subject of purpura annularis telangiectodes is by Pasini[23]. In this exhaustive paper I find no reference to angioma serpiginosum,

21. Fox, T. Colcott: A Case of Bilateral Telangiectases of the Trunk, with a History of Marked Epistaxis in Childhood and Recent Rectal Hemorrhage, Brit. Jour. Dermat., 1908, xx, 145.
22. Weber, F. Parkes: Chronic Raynaud's Symptoms and Remarks on Livedo Reticulata, Brit. Jour. Dermat., March, 1913, xxv, No. 3.
23. Pasini: Gior. ital. d. mal. ven., 1913, liv, No. 1.

Digitized by Google

the author evidently not considering the latter disease as related to that described by Majocchi.

From these extracts it would appear that some of the writers whom I have mentioned seemed to overlook the various differences in the clinical appearances of the two dermatoses. In angioma serpiginosum none of the lesions are purpuric; there is no involvement of the follicles with atrophy of the hair and alopecia, as is the case in Majocchi's disease; nor is there a tendency to disappearance and recurrence of the lesions; the capillary dilatations are not so sharply defined or so distinctly outlined as they are in Majocchi's cases, but appear more or less clouded, as though one were examining an area of ordinary blood-vessel dilatations through a piece of ground glass pressed against the skin. In Majocchi's disease the hemorrhagic lesions can easily be differentiated from the capillary dilatations, the latter being as distinct and readily visible as those, for example, of rosacea or of a spider nevus; they appear as rose-red, punctiform, lenticular or linear telangiectases, some of which may be tortuous and others branches, running parallel to the plane of the skin.

A few observers, among them Hyde,[24] have recorded the occurrence of cutaneous telangiectases in diseases associated with profound changes in the blood and the viscera; of these, the lesions occasionally seen in exophthalmic goiter are a type.

Of other related dermatoses, there remains only to be mentioned a group of diseases regarding which a great deal has been written. I refer to the class of cases described as multiple hereditary telangiectases with recurring hemorrhages. Osler[25] described a series of cases of this type. T. Colcott Fox[21] described a similar

24. Hyde: Brit. Jour. Dermat., 1908, xx, 33.
25. Osler: Quart. Jour. Med., Oxford, 1907-1908, i, 53; Telangiectases Circumscripta Universalis, Bull. Johns Hopkins Hosp., 1907, xviii, 401.

Digitized by Google

case. F. Parkes Weber[26] has written a large number of articles on this subject. Similar cases have been reported by P. Gaston.[27] A number of other authors, too numerous to mention, have written on the same subject. In this class of diseases, the affection is usually hereditary; it affects, also, the mucous membranes, is associated with recurring hemorrhages and frequently with hypertrophy and malformation of various parts of the body.

Prognosis: From the nature of the malady it may be inferred that very little can be done in the way of removal of the lesions, especially in the wide-spread cases. The problem is practically the same as the removal of a flat vascular nevus or port-wine mark. As has been mentioned before, some of the cases are arrested in their course without treatment, while in a few, spontaneous retrogression takes place, leaving the affected skin somewhat blanched, glistening and atrophic in appearance. In the majority of the cases the disease slowly advances until large areas of skin are involved. The general health of the patient remains unaffected throughout the course of the disease.

Treatment: In my patient (Case 1), considerable improvement in the appearance of the skin resulted from the long-continued use of a strong resorcin lotion, producing desquamation; whether the improvement from this mode of treatment will be lasting, is doubtful. For the removal of small patches, the use of liquid air or of solidified carbon dioxid would probably be of benefit.

## SUMMARY

1. Angioma serpiginosum is a disease entity, differing from other dermatoses which are characterized by the occurrence of multiple telangiectases, both clinically and microscopically.

---

26. Weber, F. Parkes: Angioma Formation in Connection with Hypertrophy of the Limbs and Hemihypertrophy, Brit. Jour. Dermat., 1907, xix, 231; Multiple Hereditary Developmental Angiomas (Telangiectases) of the Skin, and Mucous Membranes, Associated with Recurring Hemorrhages, Lancet, London, 1907, ii, 160.

27. Gaston, P.: Dilatation vasculaire cutanée d'origine congénitale et héréditaire; telangiectasis vaso-motrices, Bull. Soc. franç. de dermat. et de syph., Paris, 1894, v, 71.

Digitized by Google

2. It may have its starting point from a congenital vascular nevus, or it may arise *de novo,* without a pre-existing lesion of the skin.

3. The mode of extension is by the occurrence of satellite spots which later coalesce to form larger patches.

4. No purpuric elements occur in the disease.

5. Apparently there are no associated lesions of the blood and internal organs, no tendency to hemorrhages, and the general health of the patient remains unaffected.

828 Lexington Avenue.

ADDITIONAL REFERENCES

Hutchinson, Jonathan, Sr.: Brit. Jour. Dermat., 1895, vii, 114; ibid., 1907, xix, 319.
Hutchinson, Jonathan, Jr.: Ibid, 1907, xix, 327.
Morris: Brit. Jour. Dermat., 1900, xii, 93.
Morris and Dore: Brit. Jour. Dermat., 1912, xxiv, 424.
Walsh: Brit. Jour. Dermat., 1898, x, 18; Arch. Surg., 1897, viii, 143.
White, J. Mackie: Scottish Med. and Surg. Jour., 1897, i, 312.
Schamberg: Brit. Jour. Dermat., 1901, xiii, 1.
Hyde and Montgomery: Diseases of the Skin, ed. 7, 1904.

## ABSTRACT OF DISCUSSION

Dr. Joseph Zeisler, Chicago: These cases are of extreme rarity. I have seen one single case of angioma serpiginosum in a woman of middle age. For one observer to be able to report three cases of so rare an affection is certainly unusual.

Dr. George M. MacKee, New York: I had the advantage of studying this case carefully. It possessed a number of interesting features. These lesions are apparently not due to a dilatation of the blood-vessels, but to a new formation of the vessels. Some of the sections show distinct evidence of inflammation. In these cases of infective angioma, therefore, we are dealing with a dermatitis. The disease is rare, and well worthy of careful histologic study.

Dr. Howard Fox, New York: This was one of the most interesting cases I have ever seen, showing, as it did, extensive circles which were apparently typical of angioma serpiginosum.

Dr. Fred Wise, New York: Dr. Pollitzer of New York expressed the opinion that of the twenty-three cases of so-called angioma serpiginosum, probably not more than three or four are true angiomas, in the sense of their beiing vascular capillary formations.

Digitized by Google

Digitized by Google

# List of Fellows of the American Medical Association Registered in the Section on Dermatology

List of present Fellows of the American Medical Association who are making a specialty of dermatology and who have registered in this Section at one of the last five meetings. The numbers after the names indicate the record of attendance at annual sessions. (3 indicates 1913; 2, 1912, etc.)

Abercrombie, John R., 827 N. Eutaw St., Baltimore. 9.
Alderson, H. E., 937 Asbury St., San Francisco. 9.
Alderson, M. E., Russellville, Ky. 6, 9.
Andrus, A. P., 212 6th Ave., W., Ashland, Wis. 3.
Ankrim, L. F., 5014 Penn Ave., Pittsburgh. 6, 8, 9.
Armstrong, J. M., 227 Lowry Arcade, St. Paul, Minn. 3.
Babcock, I. G., Cumberland, Wis. 3.
Baeslack, F. W., 632 Congress St., Detroit. 3.
Bathurst, Wm. R., 810 State Bank Bldg., Little Rock, Ark. 9, 3.
Bernheimer, H. L., 4th and Main, Terre Haute, Ind. 3.
Boggs, Russell H., Empire Bldg., Pittsburgh, 6, 7, 9.
Boreen, C. A., Syndicate Bldg., Minneapolis. 3.
Bulkley, L. D., 531 Madison Ave., New York. 2, 3, 4, 6, 7, 9, 3.
Burt, J. C., Westinghouse Bldg., Pittsburgh. 9.
Campbell, R. R., Hotel Leighton, Los Angeles, Cal. 2, 3, 4, 7, 8, 9.
Carbaugh, Eugene, 611 Sharp Bldg., Kansas City, Mo. 3.
Casselberry, C. M., 1060 Boylston St., Boston. 9.
Chipman, E. D., 240 Stockton St., San Francisco. 9, 3.
Cook, Paul B., 633 Fairmount Ave., St. Paul, Minn. 8, 3.
Crume, G. P., 636 Syndicate Bldg., Minneapolis. 8. 3.
Cunningham, J. H., Jr., 46 Gloucester St., Boston. 9.
De Foe, W. A., 221 S. Jefferson St., Saginaw, Mich. 3.
Desmond, M. A., Akeley, Minn. 3.
Dyer, Isadore, 124 Baronne St., New Orleans. 3, 4, 3.
Eldredge, J. S., 10 Main St., Kansas City, Mo. 3.
Engman, Martin F., Humboldt Bldg., St. Louis, Mo. 9.
Erdman, Bernhard, 430 Newton Claypool bldg., Indianapolis. 9.
Farrell, John T., 1488 Westminster, Providence, R. I. 7, 8, 9, 3.
Finck, Edward Beecher, 1120 Girard St., Philadelphia. 6, 7, 8, 9.
Foerster, O. H., 128 Wisconsin St., Milwaukee. 6, 8, 9, 3.
Fordyce, J. A., 8 W. 77th St., New York City. 3, 4, 7, 8, 9.
Foster, Burnside, Lowry Arcade Blk., St. Paul, Minn. 4, 6, 3.
Fox, George Howard, 616 Madison Ave., New York. 7, 9, 3.
Fox, J. F., Bluefield, W. Va. 9.
Freeman, Chas. D., 642 Lowry Bldg., St. Paul, Minn. 8, 3.
Friedrich, Leon L., 329 E. Capitol St., Washington, D. C. 7, 9.
Gaskill, H. K., 610 Spruce St., Philadelphia. 9.
Gnichtel, A. L., 257 W. 44th St., New York. 6, 7, 8, 9, 3.
Gold, J. D., Bridgeport, Conn. 4, 7, 9.
Gottheil, W. S., 154 W. 77th St., New York. 2, 4, 6, 7, 9.
Grier, G. W., 519 Jenkins Bldg., Pittsburgh. 9.
Grosse, Alfred B., Hastings Bldg., San Francisco. 9.
Haase, Marcus, 1222 Memphis Trust Bldg., Memphis, Tenn. 8, 9.
Hamlin, O. D., 1108½ Broadway, Oakland, Cal. 4, 9.
Handly, J. W., First Nat'l Bk. Bldg., Nashville, Tenn. 9.
Harris, F. G., 6617 Woodlawn Ave., Chicago. 3.
Hartzell, Milton R., 3644 Chestnut St., Philadelphia. 2, 7, 8, 9.
Hay, E. C., Hot Springs, Ark. 4, 8, 9.
Hayes, D. J., 1403 Majestic Bldg., Milwaukee, Wis. 9.
Hazen, H. H., 1709 S St., N.-W., Washington, D. C. 9, 3.
Heidingsfeld, M. L., 19 W. 7th St., Cincinnati. 2, 3, 4, 6, 7, 8, 9, 3.
Hirsch, Charles S., 908 Pine St., Philadelphia. 7, 9.

Digitized by Google

Hoffman, H. C., 135 S. Pittsburg St., Connellsville, Pa. 9.
Hulburd, H. L., Morris, Minn. 3.
Irvine, H. G., 601 Syndicate Bldg., Minneapolis. 3.
Johnston, G. C., 8047 Jenkins Arcade, Pittsburgh. 9.
Johnston, J. M., Huntington, Pa. 9.
Katzenstein, G. P., 1704 N. 18th St., Philadelphia. 9.
Kellow, W. J., Flower Bldg., Watertown, N. Y. 7, 9.
Kennedy, D. J., 1253 S. 21st St., Philadelphia. 9.
Kessler, J. B., Iowa City, Iowa. 3, 4, 6, 7, 8, 9, 3.
Kilroy, J. H., 61 Chestnut St., Springfield, Mass. 6, 9.
King, J. C. E., Corbett Bldg., Portland, Ore. 3.
King, J. M., Eve Bldg., Nashville, Tenn. 3.
Koehler, H. H., 918 4th Ave., Louisville, Ky. 9.
Knowles, F. C., 332 S. 17th St., Philadelphia. 9.
Lain, Everett S., State Nat'l Bank, Oklahoma City. 8. 3.
Langfitt, W. J., 688 Preble Ave., Allegheny, Pa. 4, 6, 8, 9.
Le Fevre, W. I., 218 Lennox Bldg., Cleveland, Ohio. 3.
Lewis, C. T., 9 N. Central Ave., Staunton, Va. 9.
Lieberthal, David, 31 N. State St., Chicago. 2, 4, 6, 8, 3.
Linneman, N. L., Fidelity Bldg., Duluth, Minn. 3.
Lord, J. W., 1011 N. Charles St., Baltimore. 9.
Luce, Thomas W., Portsmouth, N. H.
Mackie, G. M., 58 W. 58th St., New York City. 3.
Markley, A. J., 432 Metropolitan Bldg., Denver. 3.
Mears, D. W., 420 Connell Bldg., Scranton, Pa. 9.
Menage, H. E., 2139 Baronne St., New Orleans. 3, 6, 3.
Meter, E. G., 948 Penn St., Reading, Pa. 9.
Montgomery, Douglas W., 323 Geary St., San Francisco. 4, 9.
Morrow, Howard, Butler Bldg., Union Sq., San Francisco. 9.
Murphy, E. S., Dixon, Ill. 9.
Newman, E. D., 81 New St., Newark, N. J. 9.
Nuzum, T. W., 125 W. Milwaukee St., Janesville, Wis. 9.
Ober, Geo. Eugene, 391 E. Main St., Bridgeport, Conn. 7, 9.
Ochs, B. F., 310 Convent Ave., New York City. 9.
Pederson, James, 40 E. 41st St., New York City. 9.
Pollitzer, Sigmund, 51 E. 60th St., New York. 9.
Potter, Alfred, 491 8th St., Brooklyn. 9.
Pusey, William Allen, 72 Madison St., Chicago. 2, 4, 7, 8, 9, 3.
Randall, B. A., 1717 Locust St., Philadelphia. 9.
Ravitch, M. L., Atherton Bldg., Louisville, Ky. 8, 3.
Ravogli, Augustus, 5 Garfield Place, Cincinnati. 2, 4, 6, 7, 8, 9, 3.
Rindlaub, J. H., Fargo, S. D. 3.
Rindlaub, M. P., Fargo, S. D. 3.
Rostenberg, Adolph, 1872 Wash. Ave., New York. 7, 9.
Ruggles, E. W., 348 University Ave., Rochester, N. Y. 9.
Schalek, Alfred, 518 Brandies Theater, Omaha, Neb. 3.
Schiller, Leopold, 602 Caswell Blk., Milwaukee, Wis. 3.
Schmidt, L. E., 60 Bellevue Pl., Chicago. 2, 8, 9.
Schwartz, Arthur H., New Jersey Bldg., Duluth, Minn. 3.
Simpson, F. E., 53 E. Madison St., Chicago. 3.
Stearns, B. W., Unadilla, N. Y. 4, 6, 7, 9.
Stelwagon, Henry W., 1634 Spruce St., Philadelphia. 2, 4, 6, 7, 9.
Sutton R. L., 610 Commerce Bldg., Kansas City, Mo. 3.
Swarts, Gardner T., State Board of Health, Providence. 2, 3, 4, 6, 7, 9.
Sweitzer, S. E., 625 Syndicate Bldg., Minneapolis. 3.
Tice, Frederick, 3417 Monroe St., Chicago.
Townsend, W. W., 49 Grove St., Rutland, Vt. 7, 9.
Trimble, W. B., 39 E. 28th St., New York City. 9.
Tucker, E. D., 227 Michigan St., Toledo, Ohio. 8, 9, 3.
Uhle, Alexander A., 1831 Chestnut St., Philadelphia. 9.
Vander Veer, Jas. N., 28 Eagle St., Albany, N. Y. 9.
Varney, H. R., Washington Arcade, Detroit. 2, 3, 4, 6, 7, 8, 9, 3.
von Toll, Edward, 915 Belmont Ave., Chicago. 3.
Waugh, J. T., 1527 E. 65th St., Chicago. 3.
Wende, Grover William, 471 Delaware Ave., Buffalo. 2, 8, 9.
Whaley, T. P., 113 Wentworth St., Charleston, S. C.
Wheeler, Carl L., 307-8 Trust Co. Bldg., Lexington, Ky. 8, 9.
White, Frank, 1302 N. Broad St., Philadelphia. 9.
Wilkenson, L. B., Russellville, Ky. 3.
Wilson, John S., Perth Amboy, N. J. 9.
Wise, Fred, 828 Lexington Ave., New York City. 3.
Wolbarst, Abraham Leo, 113 E. 19th St., New York. 7, 9.
Wyeth, Geo. A., 320 42d St., New York City. 9.
Zeisler, Joseph, 32 N. State St., Chicago. 8, 3.
Zurawski, K. A., 4630 S. Ashland Ave., Chicago. 8, 3.

Digitized by Google

# INDEX

PAGE

Angioma serpiginosum; paper by F. Wise ..... 177
Discussion ..... 203
Antigens for the Wassermann reaction, comparative study of; paper by H. R. Varney and F. W. Baeslack ..... 48
Discussion ..... 56
Armstrong, J. M.: discussion on skin complications of diabetes. 85
Atrophy, idiopathic, of the skin; paper by H. G. Irvine..... 132
Discussion ..... 142
Baeslack, F. W.: paper on comparative study of antigens for the Wassermann reaction ..... 48
Discussion on same ..... 58
Boreen, C. A.: discussion on mycosis fungoides..... 153
Buhman, R.: paper on the spinal fluid in syphilis..... 155
Discussion on same ..... 176
Discussion on antigens for the Wassermann Reaction.. 57
Childhood, cutaneous diseases of; paper by A. Schalek..... 71
Discussion ..... 78
Chipman, E. D.: paper on the newer cutaneous mycoses..... 116
Discussion on same ..... 131
Discussion on skin complications of diabetes..... 85
Discussion on skin diseases among Indians..... 113
Davis, R. H.: paper on the spinal fluid in syphilis..... 155
Diabetes, skin complications of; paper by B. Foster..... 80
Discussion ..... 85
Dyer, I.: discussion on pompholyx ..... 66
Discussion on skin diseases among Indians..... 114
Engman, M. F.: paper on the spinal fluid in syphilis..... 155
Fads, our tendency to; paper by J. Zeisler..... 17
Foerster, O. H.: discussion on mycosis fungoides..... 153
Foster, B.: paper on skin complications of diabetes..... 80
Discussion on same ..... 86
Discussion on cutaneous affections in childhood..... 78
Fox, H.: paper on mycosis fungoides following psoriasis..... 145
Discussion on angioma serpiginosum ..... 203
Discussion on antigens for the Wassermann reaction.. 56
Discussion on pemphigus foliaceus ..... 28
Discussion on skin diseases among Indians..... 113
Gorham, F. D.: paper on the spinal fluid in syphilis..... 155
Harris, F. G.: discussion on the spinal fluid in syphilis..... 174
Hazen, H. H.: paper on an anomalous case of white-spot disease 90
Discussion on same ..... 97
Discussion on mycosis fungoides ..... 154
Discussion on pemphigus foliaceus ..... 28
Discussion on the spinal fluid in syphilis..... 175
Heidingsfeld, M. L.: paper on neuroma cutis (dolorosum).... 98
Discussion on antigens for the Wassermann reaction.. 57
Discussion on idiopathic atrophy of the skin..... 143
Discussion on radium in skin diseases..... 37
Discussion on salvarsan versus Profeta's law..... 46
Discussion on the skin complications of diabetes..... 85
Discussion on skin diseases among Indians..... 114
Discussion on the spinal fluid in syphilis..... 175

Digitized by Google

PAGE
Indians, skin diseases among; paper by E. S. Lain..... 105
Discussion ..... 113
Irvine, H. G.: paper on idiopathic atrophy of the skin..... 132
Discussion on same..... 144
Discussion on the spinal fluid in syphilis..... 175
Kessler, J. B.: paper on pemphigus foliaceus..... 23
Discussion on same..... 29
Lain, E. S.: paper on skin diseases among Indians..... 105
Discussion on same ..... 114
Discussion on cutaneous affections in childhood..... 79
Discussion on pompholyx ..... 68
Discussion on skin complications of diabetes ..... 86
Lieberthal, D.: discussion on cutaneous diseases in childhood.. 78
Discussion on the spinal fluid in syphilis..... 175
Lip, sarcoma of lower; paper by A. J. Markley..... 87
MacKee, G. M.: discussion on angioma serpiginosum..... 203
Markley, A. J.: paper on sarcoma of the lip..... 87
Discussion on skin diseases among Indians..... 113
Menage, H. E.: discussion on mycoses..... 130
Discussion on skin complications of diabetes..... 85
Mycoses, newer cutaneous; paper by E. D. Chipman..... 116
Discussion ..... 130
Mycosis fungoides following psoriasis; paper by H. Fox..... 145
Discussion ..... 153
Neuroma cutis; paper by M. L. Heidingsfeld..... 98
Pemphigus foliaceus; paper by J. B. Kessler ..... 23
Discussion ..... 27
Pompholyx, histopathology of; paper by R. L. Sutton..... 59
Discussion ..... 66
Profeta's law versus salvarsan; paper by A. Ravogli..... 40
Discussion ..... 46
Psoriasis followed by mycosis fungoides; paper by H. Fox.... 153
Pusey, W. A.: discussion on cutaneous affections in childhood.. 78
Discussion on idiopathic atrophy of the skin..... 143
Discussion on pemphigus foliaceus ..... 27
Discussion on pompholyx ..... 67
Radium in skin diseases; paper by F. E. Simpson..... 30
Discussion ..... 37
Ravitch, M. L.: discussion on cutaneous affections in childhood 79
Discussion on pompholyx..... 68
Discussion on radium in skin diseases..... 38
Discussion on skin diseases among Indians..... 113
Ravogli, A.: paper on salvarsan versus Profeta's law..... 40
Discussion on same..... 47
Discussion on mycoses..... 131
Discussion on pemphigus foliaceus..... 28
Discussion on white-spot disease..... 97
Salvarsan versus Profeta's law; paper by A. Ravogli..... 40
Discussion ..... 46
Sarcoma of the lower lip; paper by A. J. Markley..... 87
Schalek, A.: paper on cutaneous affections of childhood..... 71
Discussion on same..... 79
Discussion on pemphigus foliaceus ..... 27
Discussion on radium in skin diseases..... 39
Discussion on salvarsan versus Profeta's law..... 46
Simpson, F. E.: paper on radium in skin diseases..... 30
Discussion on same..... 40
Discussion on mycosis fungoides ..... 153
Discussion on pompholyx ..... 67
Skin diseases among Indians; paper by E. S. Lain..... 105
Discussion ..... 113

Digitized by Google

PAGE

Skin diseases in childhood; paper by A. Schalek ..... 71
Discussion ..... 78
Skin diseases, radium in; paper by F. E. Simpson..... 30
Discussion ..... 37
Skin, idiopathic atrophy of the; paper by H. G. Irvine..... 132
Discussion ..... 142
Spinal fluid in syphilis; paper by M. F. Engman, R. Buhman, F. D. Gorham and R. H. Davis..... 155
Discussion ..... 174
Sutton, R. L.: paper on the histopathology of pompholyx .... 59
Discussion on same ..... 69
Discussion on idiopathic atrophy of the skin..... 142
Discussion on mycoses ..... 130
Discussion on pemphigus foliaceus ..... 27
Syphilis, spinal fluid in; paper by M. F. Engman, R. Buhman, F. D. Gorham and R. H. Davis..... 155
Discussion ..... 174
Varney, H. R.: paper on comparative study of antigens for the Wassermann reaction ..... 48
Discussion on same ..... 57
Discussion on radium in skin diseases..... 39
Wassermann reaction, comparative study of the antigens for; paper by H. R. Varney and F. W. Baeslack..... 48
Discussion ..... 56
Waugh, J. F.: discussion on antigens for the Wassermann reaction ..... 57
White-spot disease, an anomalous case of; paper by H. H. Hazen ..... 90
Discussion ..... 97
Wise, F.: paper on angioma serpiginosum ..... 177
Discussion on same ..... 203
Discussion on radium in skin diseases..... 39
Zeisler, J.: paper on our tendency to fads..... 17
Discussion on angioma serpiginosum..... 203
Discussion on mycosis fungoides ..... 153
Discussion on pompholyx .....66, 69
Discussion on radium in skin diseases..... 38
Zurawski, K. A.: discussion on cutaneous affections in childhood ..... 79
Discussion on pompholyx ..... 68
Discussion on skin complications of diabetes..... 85

Digitized by Google

Digitized by Google

Digitized by Google

Digitized by Google

Digitized by Google

Digitized by Google

COUNTWAY LIBRARY
HC 4K5W 4

41C
608-

Digitized by Google

Digitized by Google